

# The non-surgical repair of a complete achilles tendon rupture by prolotherapy: biological reconstruction. A case report.

Marc Adam Lazzara, D.O.

Irvine, California

## Abstract

A 26-year old athlete suffered a full thickness tear of the Achilles tendon. After initial casting, biological reconstruction by prolotherapy was undertaken. A satisfactory result in terms of function and imaging is reported, at four months follow-up.

**Keywords:** *Achilles tendon, rupture, prolotherapy, biological reconstruction.*

## Introduction

This case reports the only known documented biological repair of a totally ruptured tendo calcaneus or Achilles tendon by prolotherapy. Prolotherapy is a non-surgical injection technique that employs various solutions to create an inflammatory response that stimulates the increase of polypeptide growth factors leading to the production of collagen that cause the proliferation of ligaments, tendons and at their bony junctions [1]. An extensive search was conducted through the following data bases: MedLine [old & new], PubMed, EBSCO, OSTMED, and Cochrane. Each data base was searched in its entirety and all queries were cross-referenced with Tex and MeSH words of: “achilles”, “achilles tendon”, “complete”, “rupture”, “repair”, “tear”, “reconstruction”, “prolotherapy”, and “sclerotherapy” to demonstrate that such a repair has not occurred in the literature prior to this case report.

## Case report

A 26-year-old female, former European national soccer player reported falling to her knees combined with the inability to walk or bear weight after feeling as if she was hit with a rock in her right heel in the second half of her third game of the day during a soccer tournament. The player stated that she arrived late to the tournament and did not have time to warm-up or stretch prior to competition and that she seemingly sprained her right ankle and strained the left achilles tendon in the first half of the second game [the achilles ruptured on the right side], however, she continued on with play despite minor discomfort. The player can recall just prior to her falling to her knees that she was trailing a developing play at a very slow jog in which she had not made any directional change or any contact with any other player on the field while beginning to decelerate to a walking pace.

The injury occurred when she went from a walking pace to a complete stop on the field.

The player was transported off the field to her orthopaedic physician who clinically felt she had a moderate to severe calf strain, although not a complete rupture of the achilles tendon. The orthopaedist recommended casting, crutches and non-weight bearing on the right lower limb. The player was casted in thirty degrees of plantar flexion three days after the injury/point zero. The cast was removed thirty days after it was placed. An MRI, on the 43<sup>rd</sup> day, of the player's right achilles tendon was obtained due to continued pain and inability to bear weight and this showed a full thickness tear of the achilles tendon 4.3 cm above the calcaneus with a 1.1 cm gap.

Additionally, the MRI described the gap to be filled with edema and hemorrhage coupled with tenosynovitis of the both the peroneus brevis & longus plus thickening of both the anterior talofibular [ATFL] & calcaneofibular [CFL] ligaments. At this point, the player was re-casted and again placed on crutches and non-weight bearing. The second cast was removed at the 60<sup>th</sup> day and subsequently placed into a walking cast and crutches.

The player presented to my clinic on the 67<sup>th</sup> day for the same continued problem of pain and inability to bear weight. During the interview process the athlete stated she has an insignificant medical history and reported that she has never had an achilles rupture or strain, for either leg, nor ever received a corticosteroid injection in the achilles area.

General observation revealed that the affected achilles tendon had a moderately swollen watershed area and a faintly swollen lateral ankle with visible medial and lateral gastrocnemius atrophy. The examination demonstrated a positive Thompson's test for achilles rupture, a palpable gap in the watershed area approximately 5cm from the calcaneus, inability to plantar flex, walk or bear weight, as well as tenderness over the ATFL & CFL. Imaging with diagnostic ultrasound demonstrated significant hypoechoic findings and a completely gapped achilles tendon with ends that were 1cm apart which is consistent with a total achilles tendon rupture and parallel with the MRI finding of an entire achilles tendon rupture. The athlete opted for treatment with prolotherapy despite strong medical recommendation that surgery was currently the treatment of choice (even though the injury was well past sixty days).

The athlete received prolotherapy for about three months at two week intervals for a total of eight treatments. The prolotherapy solutions used for treatment consisted of:

AGENT	AMOUNT
1. Lidocaine 2%	5ml
2. Dextrose 50%	6ml [15%]
3. Bacteriostatic water	7.5ml
4. Sodium Morrhuate 5%	1.5ml [3.75%]

The solution totaled 20ml which was usually completely used during treatment. The procedure included injection of the achilles tendon, ATFL, CFL and ankle joint. Specifically, the achilles tendon was injected into the gap both from the medical and lateral sides delivering 1cc per site and about 1/2ml into the tendon ends. Then using the same port on either side the needle then was redirected to parallel the achilles tendon both in the cephalad and caudad directions on both sides of the tendon delivering about 3ml per arm as the needle was withdrawn through the tissue. The injection pattern resembles the figure 'H'. Lastly, the medical and lateral calcaneus base [tuberosity process of the calcaneus], as well as the ATFL and CFL attachments and their bony junctions were injected with 1ml each of the prolotherapy solution. The athlete was placed in a walking cam at 20 degrees equines [plantar flexion] and strict non-weight bearing while on crutches.

Due to concerns of continued atrophy, poor circulation at the tear site and the possibility of Sudeck's disease or reflex sympathetic dystrophy [RSD] the athlete was instructed to perform gentle, low amplitude isometric exercises in the calf and thigh muscles without movement at the ankle. Unfortunately, the athlete did develop RSD which was evident by the lattice skin pattern, mild swelling of the lower limb, discrete stiffness and disproportion of pain with very light touch by the fourth treatment that resolved completely by the seventh treatment. RSD treatment included increased range of motion as the patient's heel cord strength improved hence allowing such increased tension with both strength exercises and proprioception training via a Bap's Board. Note that a Bap's Board is a circular platform about 24 inches (60cm) diameter with a device which has adjustable heights [about 2-6 inches (5-15cm)] that is attached onto the bottom middle. This configuration can be likened to a large dinner plate with a tennis ball attached to be bottom of it. The Bap's Board was designed to facilitate range of motion, enhance proprioception and indirectly reduce edema and promote circulation. The traditional routine for the Bap's Board is using only the weight of the lower limb or essentially non weight bearing in the eight directions of the map [north, northwest etc] and in a circular fashion both clock and counter-clockwise.

The repair process proceeded in a linear fashion. There was a palpable degree of filling-in of the gap by the second visit (the beginning of the second week) and completely by the fifth treatment (beginning of the eighth week). At the fourth treatment (beginning of the sixth week), imaging with diagnostic ultrasound showed a newly formed tendon that completely bridged the defective gap. An O'Brien's test was

performed by inserting a 25gauge, 1.5 inch (3.75cm) needle into the now newly formed achilles tendon at the height of the original gap at 4.3cm above the calcaneus and asking the athlete to plantar and dorsi-flex which caused the needle hub to move in the opposite direction of the placement of the foot confirming the diagnostic ultrasound finding of a regenerated achilles tendon. In order to make a direct comparison another MRI was scheduled to evaluate the athlete's progress since the original MRI. The second MRI was obtained three days prior to the sixth treatment (just prior to the tenth week of treatment) which showed no abnormality of the achilles tendon inferior to the musculotendinous junction and that the achilles tendon is intact [Figure1].

Home physical therapy [secondary to financial reasons] was initiated with the fourth treatment (the beginning of the sixth week) that keyed on range of motion, Bap's Board for proprioception and isotonic exercises. The patient was allowed to walk out of the walking cam only at home or in the swimming pool and used crutches if necessary. By the sixth treatment or beginning of the tenth week the patient was advanced to strength exercises, food quality heel-toe gait and advanced range of motion for the entire leg with special focus on the watershed area of the achilles.

On the last or eighth treatment at the beginning of the 14<sup>th</sup> week the diagnostic ultrasound measured both achilles tendons for comparison and found that the right or treated tendon measured 1.04cm diameter and the contralateral tendon was 0.34cm [Figure2] for a 205 percent difference.

By the last visit or total treatment time of nearly four months the patient has a normal gait, can jog and does not have any discomfort while at rest or jogging. However, the patient still exhibited significant calf atrophy [right/affected: 31cm & left 34cm; both taken 25cm from the calcaneus base] and has minor to mild tenderness with more aggressive heel cord stretching.

## Discussion

The tendo calcaneus or achilles tendon is the thickest and strongest tendon in the human body and its narrowest aspect is 4-5cm from the calcaneus base [2]. Langergren & Lindholm [3] reported that there is an avascular zone about 2-6cm from the base of the calcaneus and that this area of avascularity is the most common site for rupture of the achilles tendon [4,5,6]. There are multiple authors that suggest both intrinsic and extrinsic factors predispose an athlete to rupture of the achilles tendon.

However, if inborn [intrinsic] errors such as tendon degeneration training [extrinsic] errors such as overtraining were predictable pathogenesis for achilles tendon ruptures then it would be expected to see a far greater number of ruptures in the population. Hence, Salter [7], Clement [8] and Schepsis [9] have argued and demonstrated that sudden passive dorsiflexion at the ankle that is resisted by a strong concentric contraction in the calf is the probable mechanism of action causing the rupture of the achilles tendon. The

same authors noted that the most important measure that can be taken to prevent an achilles rupture is stretching the posterior structures of the calf.

The management of a complete achilles tendon rupture has been controversial for the last one hundred years. Major studies have not clearly indicated a definitive treatment of choice for repair; however, surgical repair is in greater

Favour clinically. Each approach has its own advantages and disadvantages such as non-operative repair [casting] which is non-invasive, has less complications and is more cost effective while surgery provides for a greater return to activity, and better recovery of strength, power and endurance. There are many studies that refute the above finding; however one statistic that powerfully argues in favour of surgery is that surgery has a much lower incidence of re-rupture after treatment of 1.6% versus 18% with non-operative repair [2].

In this particular case, the patient was disgruntle with her initial care and felt that after two months of the same persistent complaint of pain and the inability to bear weight she felt strongly against surgery and opted for prolotherapy despite this author's medical recommendation to have surgical repair. The patient was informed that prolotherapy had not yet been proven to effectively treat a completely ruptured achilles tendon and that surgical repair was the more medically appropriate procedure at that time for the athlete. After all of this had been discussed, the patient still requested to proceed with prolotherapy treatment.

Prolotherapy aims for biological reconstruction of injured ligament, tendon, enthuses [bony attachment of ligament & tendon], fascia and joint capsules. Biological reconstruction [a term coined by prolotherapy Dr. William J. Faber] induces tissue repair by stimulating multiple physiologic pathway that create a cellular cascade through both mRNA and chemotaxis which draws fibroblasts to the damaged structure. Then the fibroblast synthesizes collagen which ultimately lays down healthy, viable tissue [not scar tissue] that relieves chronic pain, strengthens ligamento-tendinous laxity, alleviates myofascial pains and effectively treats degenerative processes such as osteoarthritis.

The wound healing of classical prolotherapy has three phases [10] of inflammation, granulation and maturation. The first phase of inflammation involves homeostasis and the formation of the matrix which is analogous to a scaffolding for the construction of a building in which the newly synthesized collagen will be formed. During the first phase thromboxane, prostaglandin, epinephrine, and platelets all coordinate a sequential and temporal cascade of events that initiate clotting and vasoconstriction by eliciting polypeptides or complex proteins such as platelet derived growth factor [PDGF], fibroblast growth factor [FGF] and transforming growth factor [TGF] that eventually provide for the matrix.

The second phase of granulation involves a process of intense cell migration, cell activation and proliferation that supports the development of wound repair. Granulation tissue primarily consists of angiogenesis, continued matrix formation and collagenesis. The macrophage is the key cellular player in the granulation process. The last or third stage of prolotherapy is the maturation phase that includes elevated oxygen tissue concentration, increased nutrients, and heightened surplus of rough endoplasmic reticulum and the Golgi apparatus. Finally, collagen assembles into fibers that coalesce to form bundles which have their globular heads cleaved for complete maturation.

It is most important to understand that collagen proliferation caused by prolotherapy is not scar tissue and is identical to the reticular type fiber pattern found in fetal wound healing which is indistinguishable from surrounding tissue whereas scar tissue has a parallel fiber pattern that can be separated out from the surrounding tissue [11, 12, 13, 14].

The complete pathophysiology is not within the scope of this case study, however, it should be noted that histological studies over seventy years have well documented the detailed account of cellular events by the hour and day of occurrence of how collagen is laid down with impressive reproducibility in all studies [15, 16, 17, 18, 19, 20].

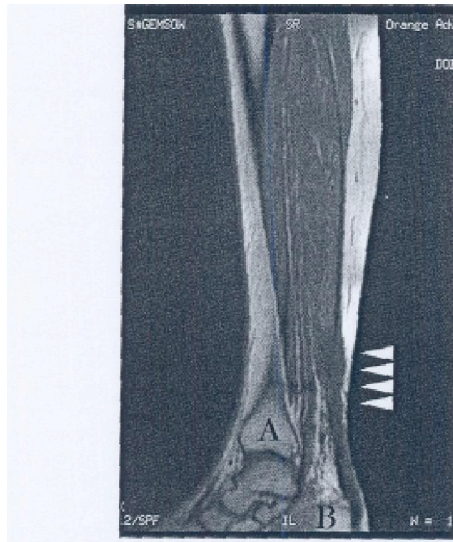
## Conclusion

This is the first ever published case study that has demonstrated that prolotherapy or biological reconstruction has no operatively repaired a full thickness tear of an achilles tendon which was proven to be completely ruptured and healed by both MRI & diagnostic ultrasound imaging techniques. This case study is advocating that prolotherapy can be a viable treatment option for those patients with a complete achilles tendon rupture that otherwise can not have an operative or casting procedure performed. It should be noted that this prolotherapy technique may also be well applied to other ligament and tendon injuries or degenerative processes of the body.

## REFERENCES

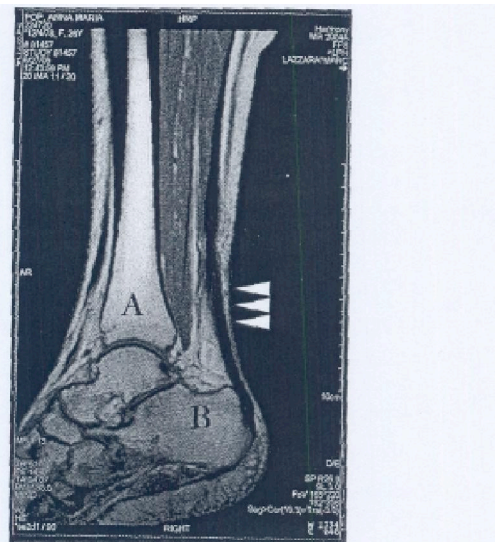
1. Reeves K Dean. Prolotherapy: Basic science, clinical studies and technique. In: Lennard TA, Pain Procedures in Clinical practice. Philadelphia: Hanley & Belfus, 2000: 172-190.
2. Keene James S. Tendon injuries of the foot and ankle. In DeLee JC, Drez D Jr., eds. Orthopaedic Sports Medicine: Principals and Practce. Philadelphia: WB Saunders Co., 1994: 1768-1805.
3. Langergren C, Lindholm A. Vascular distribution in the achilles tendon. Acta Chir Scand 1958-1959; 116: 491-495.
4. Fox J, Blazina ME, Jobe FW, et al. Degeneration and rupture of the achilles tendon. Clin Orthop 1975; 107: 221-224.

Figure 1. Before Treatment:



AT2, sagittal magnetic resonance image of the Achilles tendon on day 43 demonstrating interrupted, thickened hemorrhagic and gapped fibers of the tendon which is consistent with a full thickness tear [arrowheads]. A, tibia; B, calcaneus.

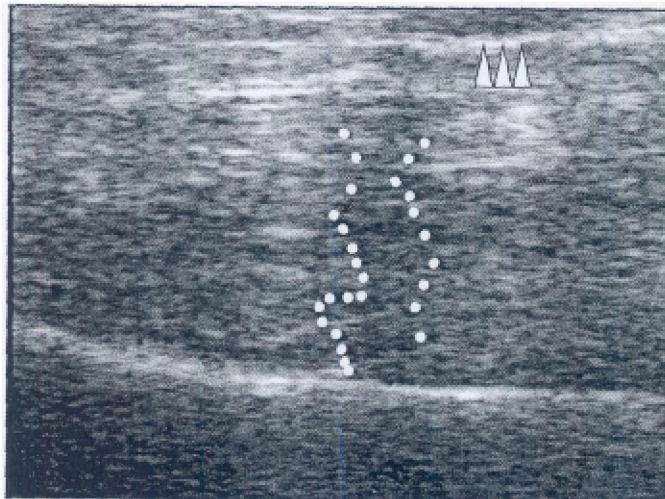
After Treatment:



A T2, sagittal magnetic resonance image of the Achilles tendon on day 144 demonstrated a regenerated, intact tendon [arrowheads]. A, tibia; B, calcaneus.

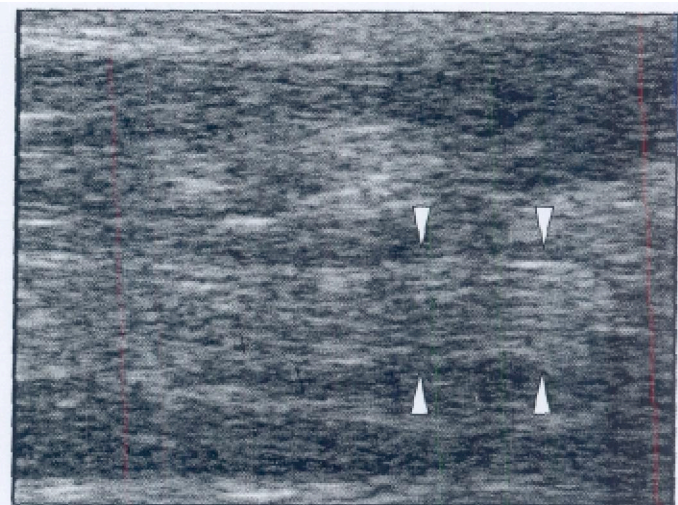
Figure 2.

Before Treatment:



Diagnostic ultrasound in a longitudinal view at 9 MHz of the Achilles tendon on day 67 demonstrating frayed ends [white dots] and a hypoechoic, heterogeneous defective middle, which is consistent with a full thickness, tear. Note the anechoic site representing a tear of the plantaris tendon [arrowheads].

After Treatment:



Diagnostic ultrasound in a longitudinal view at 9 MHz of the Achilles tendon on day 161 demonstrating a homogeneous, highly echogenic fibers which is consistent with a normal, healthy and intact tendon [arrowheads]