

## Prolotherapy

# Platelet-Rich Plasma Prolotherapy for Low Back Pain Caused by Sacroiliac Joint Laxity

A relatively new treatment modality, PRP prolotherapy demonstrates effectiveness in case studies of patients with sacroiliac (SI) joint ligament laxity and painful dysfunction.



Donna Alderman, DO

*Platelet-rich plasma prolotherapy (PRPP) is an injection treatment that stimulates healing. Like dextrose prolotherapy, PRPP “tricks” the body into repairing incompletely-healed musculoskeletal injuries that results in reduced pain and increased function. Growth factors from blood platelets in platelet-rich plasma stimulate and accelerate healing. Reports are continuing to emerge of the effectiveness, safety, and regenerative capacity of this treatment. In this interesting article, Dr. Gordon Ko, a Canadian physician, shares his expertise in the use of PRPP for low back pain caused by sacroiliac joint laxity. Dr. Ko integrates PRPP with other modalities to accomplish reliable and often dramatic improvement for his patients in this retrospective case report study.*

— Donna Alderman, DO  
Prolotherapy Department Head



By Gordon D. Ko, MD, CCFP(EM), FRCPC, FABPM&R, FABPM

The sacroiliac joints are subject to considerable stresses in weight-bearing and back-twisting movements. Trauma to the SI ligaments can occur with falls on the buttocks, car accidents, twisting and lifting injuries, and repetitive impact loading from excessive running (marathoners). Predisposing factors include hypermobile joint syndromes (such as Ehlers-Danlos syndrome; see Figure 1) and pregnancy resulting in hormonally induced laxity (relaxin). With an injury to the SI joint, pain tends to be unilateral and can refer to the posterior thigh, iliac fossa and buttocks. Sprains of the iliolumbar ligaments can also result in referred pain into the groin and genitalia. Non-traumatic causes of SI joint pain also include seronegative arthritides such as ankylosing spondylitis, reiter’s syndrome, and psoriatic arthritis.

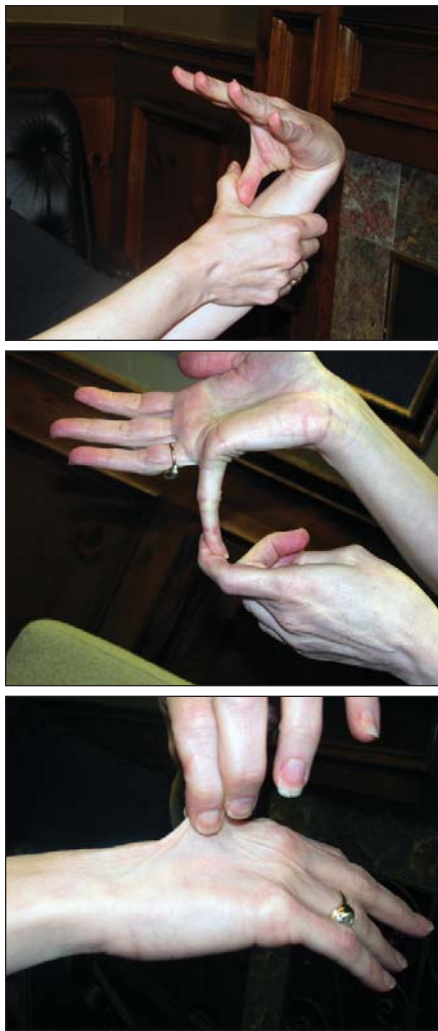
SI joint ligament instability pain is aggravated with prolonged immobility—e.g., pain from the “cocktail party”-prolonged standing; “theatre”-prolonged sitting. Pain is often worse with turning in bed, getting out of bed, standing up from a seated position or stepping up with the affected leg. Clinical signs include contranutation (anterior torsion of the ilium relative to the sacrum) as reflected by the anterior superior iliac spine (ASIS) being lower and the posterior superior iliac spine (PSIS) being higher. Nutation is the opposite (as when doing the “pelvic tilt”). Provocative tests can be done supine (gapping test, femoral shear test, Laguerre’s sign, Gaenslen’s test); prone (sacral apex pressure test, yeoman’s test, posterior iliac glide test); sitting (piedallu sign, supine-to-sit test); and standing (gillet’s knee-to-chest test). Clinical exam for diagnosis is,

however, quite unreliable.<sup>1,2</sup>

A new scale to diagnose SI joint instability that responds to prolotherapy has been recently co-developed by the author and is undergoing validity/reliability testing (Whitmore-Gordons Sacroiliac Instability Tool; see Appendix A). SI joint dysfunction diagnosed by intra-articular blocks accounts for about 20% of chronic low back pain.<sup>3,4</sup> Treatment options for SI joint pain include medication (anti-inflammatories, analgesics, cortisone injections), physiotherapy, psychological counseling, surgery (radiofrequency denervation, surgical fusion), cortisone and botulinum toxin-A injections,<sup>5</sup> and prolotherapy.<sup>6</sup> Prolotherapy injections with Platelet-rich Plasma (PRP) is a relatively new treatment. This paper documents its effective application in patients with SI joint ligament laxity and painful dysfunction.

### Physiology

The sacroiliac (SI) joints connect the large wedge-shaped sacrum (comprised of five fused sacral vertebrae) to the fan-shaped ilia bilaterally. The SI joints are part synovial and part syndesmosis. The latter is a fibrous joint in which the intervening connective tissue forms an interosseous ligament. The synovial part is C-shaped with the convex ilium surface facing anteriorly and inferiorly. The articular surface of this ilium part is covered with fibrocartilage whereas that of the sacral part, hyaline cartilage. The angulation, shape and roughness of these articular surfaces vary greatly. In children, the surfaces are smooth. In adults, the surfaces become irregular with depressions and elevations that fit into one another. By doing so, movement is restricted, enhancing the stability of these joints in transferring weight from the



**FIGURES 1A-1C.** Signs of Ehlers-Danlos Syndrome. Figures 1a and 1b demonstrate hypermobile joints, and figure 1c demonstrates elastic skin.

lower limb to the spine. One analogy is that the sacrum works as a universal link in a transmission. Another describes it as a keystone in an architectural arch. The SI joints and symphysis pubis have no muscles that control their movements directly. The force closure mechanism that stabilizes the SI joints however is enhanced by the lumbodorsal fascia forming a mechanical link between the gluteus maximus muscle on one side and the latissimus dorsi muscle on the other side.<sup>7</sup>

It used to be thought (and sometimes is still taught) that there is no movement in the sacroiliac joints. Over 100 years ago, clinical observations documented SI joint movement in pregnant women with low back pain.<sup>8</sup> Subsequent in-vivo studies using implanted metal markers and stere-

oradiography have shown small movements in normal individuals in prone hyperextension (2 degrees of backward rotation of the sacrum relative to the ileum; 0.2 degrees of inward rotation of the iliac crests; and translation gliding of 0.6mm between the sacrum and ilium).<sup>9</sup> Movements were 30-40% smaller in men and tended to increase slightly with age. Larger angular rotations (6-8 degrees) and translations (2.5mm) were reported in one subject with recurrent SI problems.<sup>10</sup> In-vitro cadaver studies using embedded lead spheres and CT scan analysis have also documented movement.<sup>11</sup> Application of eccentric forces (up to 60% of body weight) to cadaver pelvises resulted in rotational and translation movement. Rotational movement was increased by 10% when the posterior or anterior ligaments were cut and by 30% when both were cut.<sup>12</sup> Anteriorly, the symphysis pubis is a cartilaginous joint with an interpubic fibrocartilaginous disc between the two joint surfaces. The sacrococcygeal joint is another symphysis that is united by a fibrocartilaginous disc. Occasionally this joint is synovial and movable. With advanced age, this and the SI joint may fuse and become obliterated.

### Prolotherapy Background

Prolotherapy is a medical procedure that involves the injection of proliferating agents such as 12.5% dextrose mixed with local anesthetic. The injections are directed into ligaments, particularly at their insertion into bone/joints. Stronger customized solutions to promote faster healing include P2G (phenol-glycerine-glucose), sodium morrhuate (cod liver oil extract) and a patient's own blood (platelet enriched plasma). The goal of prolotherapy is to stimulate collagen formation and deposition. By doing so, ligaments are strengthened and joint stability is enhanced. Such strengthening has been supported by both animal and human studies.<sup>13-15</sup>

The first physician to report on prolotherapy was Earl Gedney, DO, in 1937, who reported on this type of joint-injection after using it successfully on his own thumb.<sup>16</sup> At a later date, while performing a hernia operation, general surgeon George Hackett, MD, discovered by chance that injections given “(usually in error) at the junction of ligament and bone resulted in profuse proliferation of new tissue at this union.” He then spent

the rest of his career developing and refining the injection techniques leading to the publication of his text *Ligament and Tendon Relaxation Treated by Prolotherapy* in 1956. He treated 543 chronic low back pain patients (ages 15 to 88 with pain duration of 4 to 56 years) and reported an 82% success rate with such patients considering themselves cured over periods ranging up to 12 years at follow-up. Subsequent supportive clinical studies include case series for chronic groin pain,<sup>17</sup> whiplash,<sup>18</sup> fibromyalgia<sup>19</sup> and randomized controlled trials (RCTs) for knee osteoarthritis,<sup>20</sup> finger-thumb osteoarthritis,<sup>21</sup> and chronic low back pain.<sup>22,23</sup> One two-year RCT for low back pain found improvement in both the active (dextrose) and placebo (saline) prolotherapy groups suggesting that even the needle itself has an effect.

### Platelet-Rich Plasma Prolotherapy

Platelet-rich plasma prolotherapy (PRPP) involves the injections of autologous blood—in particular, the portion concentrated with platelets—back into the donor's body at the site of concern.

In the PRP treatment, venous blood (up to 20-60 cc at one time) is taken out from the arm. It is then spun down over 14 minutes in a patented centrifuge (manufactured by Harvest Technologies, Inc.) that separates the blood into distinct layers. This centrifuge provides for a higher concentration of platelets (almost five times greater than that in normal blood).<sup>24</sup> The platelet portion is found immediately above the white blood cells (leucocytes) in the buffy coat. This is withdrawn into a syringe, mixed with anticoagulants, and then injected into tissues that require healing such as the sacroiliac ligaments in this case series. Local anesthetic is usually administered to the skin and subcutaneous tissues to minimize pain from the PRP procedure. Anesthetic is usually not mixed with the PRP solution since dilution of the platelets may reduce its effectiveness. Multiple injections are usually given over the injured area and repeated as needed over a period of time—depending on the severity of injury and healing response.

Blood consists of four components: plasma, red blood cells (RBC), white blood cells (WBC), and platelets. Plasma is the liquid medium in which the blood cells and platelets travel in. Plasma consists predominantly of water and contains

various proteins such as albumin and fibrinogen. At 93%, RBCs consists of the majority of all cell matter in blood. They function as transporters to deliver oxygen to cells, and remove the expelled carbon dioxide. WBCs act as the body's immune system: they defend against pathogens and foreign matter and consume waste matter in the blood. WBCs compose a mere 1% of cell matter in blood. Platelets make up the remaining 6% of blood. These small but extremely versatile cell fragments are responsible for clotting, hemostasis, revascularization, and connective tissue repair. Connective tissue repair is the platelet function that PRP operates on.<sup>25</sup>

### PRPP Mechanism of Action

PRPP operates on a very simple principle: platelet concentrations, when increased in a specific area, stimulate rapid healing. Normal blood contains approximately 200,000 platelets/mcL. In PRPP injections, platelet concentrations can be as high as 1 million platelets/mcL.<sup>26</sup> The platelet-RBC ratio is essentially reversed, with 94% of the cell matter being platelets and 5% being RBC.

Platelets contain many different structures, including glycogen, lysosomes, alpha and beta granules. The main focus of PRPP is on the alpha granules, as these structures house all of the growth factors essential to PRPP in inactivated forms. These growth factors include: transforming growth factor beta (TGFβ), vascular endothelial growth factor (VEGF), platelet derived growth factor (PDGF), and epithelial growth factor (EGF). TGFβ acts during inflammation to help regulate cell migration and replication. VEGF is released after the inflammatory phase and stimulates angiogenesis, as well as accelerates tendon cell and type I collagen synthesis. PDGF is responsible for promoting mesenchymal stem cell, osteoid, and endothelial reproduction, as well as collagen synthesis. EGF functions to produce basal skin cells and mucosal membranes, as well as inducing cell migration and replication.<sup>27</sup> Other notable proteins found in PRP are vitronectin, fibronectin, and fibrin, all of which function as cell adhesion molecules. Platelets also contain dense granules which contain factors (ADP, calcium, serotonin) that promote platelet aggregation.

Alpha granules must degranulate in order to release their contents and begin

the healing cascade of collagen restoration and growth. Degranulation and growth factor secretion are initiated by the clotting function of platelets. Growth factor secretions occur within ten minutes after coagulation, and more than 95% of the growth factors can be released within one hour. Therefore anticoagulants such as citrate solutions are mixed with PRPP blood in order to prevent premature coagulation.

After granular release, the growth factors are activated via the attachment of various histones and carbohydrate side chains. The activated growth factors are transported to the cell membrane for cellular export and paracrine signaling. These growth factors then bind to the surface receptors on the plasma membranes of their target cells. Some exam-

- Low hemoglobin (< 10 g/dL)
- Low blood pressure; hemodynamic instability
- Dysfunctional platelets and clotting (hemophiliac)
- Consistent use of NSAIDs (anti-inflammatory drugs) within 48 hours of PRP procedure<sup>28</sup>
- Corticosteroid injection at treatment site within two weeks of PRPP procedure
- Corticosteroid by mouth or i.v. within two weeks of PRPP
- Concurrent or recent fever or illness
- Septicemia (generalized blood infection)
- Active infections
- Active cancer—especially hematopoietic or of bone
- Rash at injection site.

*“Normal blood contains approximately 200,000 platelets/mcL. In PRPP injections, platelet concentrations can be as high as 1 million platelets/mcL.<sup>26</sup> The platelet-RBC ratio is essentially reversed, with 94% of the cell matter being platelets and 5% being RBC.”*

ples of these target cells include: mesenchymal stem cells, osteoblasts, fibroblast, endothelial cells, and epidermal cells. The growth factor-receptor complex then signals for internal cellular proteins to activate specific gene sequences that allow for functions such as: cellular reproduction, matrix formation, osteoid production, collagen synthesis, etc. PRPP treatments are ideally performed immediately after centrifugation to maximize the efficacy of growth factor usage.

### Safety

Since PRPP uses autologous blood, any chances of immunogenic reactions or disease transfer that may occur from the usage of non-autologous blood are negated. Acting growth factors attach to cell surfaces rather than the nucleus, essentially eliminating the chance of tumor formation through the use of negative feedback control.

### Contraindications

The following list presents contraindications to the use of PRP:

- Low platelet count (< 105/uL)

### Risks

As with all injection procedures, there is a remote chance of local anesthetic allergy and toxicity, risk of infection, neural and organ trauma, and needle breakage. These can all be minimized with established standard operating procedures in sterility and operator technique.

### Impediments to Collagen Synthesis and Tendon-Ligament Healing

Prior to PRPP or if there is no response after therapy, it is important to screen for and correct for conditions that could impair healing. These include:

- **Nutritional deficiencies**  
Iron studies, serum zinc, serum vitamin C; with neuropathic pain, screen also for 25(OH) vitamin D3, serum B12, RBC folate, omega-3 fatty acid profile
- **Hormonal deficiencies**  
TSH (hypothyroidism), DHEA-S/cortisol (a.m.) (adrenal fatigue), free testosterone (hypogonadism), IGF-1 (adult growth hormone deficiency syndrome), FBS and A1C (diabetes)
- **Inflammatory disorders**



ESR, CRP, CK, seronegative disease and immuno-nological work-up (as indicated based on the clinical examination).

### Platelet-Rich Plasma Efficacy

There is an extensive history in the use of PRP dating back to 1987 for cardiac surgery.<sup>29</sup> Since then, PRP has also been used by other specialists in dentistry, ENT (maxillofacial and periodontal), cosmetics, and burn surgery. PRP has been used over the past ten years in the musculoskeletal field, with publications by orthopedic surgeons—including randomized clinical trials in repairing:

- Tennis elbow
- Achilles tendon
- Plantar fasciitis
- Anterior cruciate ligament (ACL)
- Rotator cuff
- Lower back pain

**Tennis Elbow.** Mishra et al performed a study involving 140 patients afflicted with chronic elbow epicondylar pain. These patients were first subjected to a standard physical therapy treatment and other nonsurgical treatments. Twenty of these patients continued to have pain and were acclaimed candidates for PRP. Fifteen patients underwent PRP while the other five underwent a standard bupivacaine injection (control). Eight weeks after the treatment, results indicated that the PRP patients noted a 60% improvement in visual analog scores (VAS) in pain scores, while the control patients only noted 16%. After six months, PRP patients noted an 81% improvement, and 93% during the final follow-up at 12-38 months. However, three of the five control patients opted out of the experiment to seek other means of treatment after eight weeks, and thus limited the statistical outcome of the study.<sup>30</sup> More recently, a larger randomized controlled trial compared PRP (51 patients) to corticosteroid injections (49 patients). The primary outcome measure was a 25% reduction in VAS pain or DASH (Disabilities of the Arm, Shoulder, Hand) score without need for a re-intervention after one year. 73% of the PRP vs 49% of the corticosteroid patients were successful ( $p < 0.001$ ). The corticosteroid group was better initially and then declined, whereas the PRP group progressively improved.<sup>31</sup>

**Achilles Tendon.** This study, conducted by Sanchez et al, consists of 12 athletes who underwent open suture repair

of the Achilles tendon after complete tearing of the tendon. Half of the patients received surgery in a growth factor rich preparation (GFRP), while the remaining six patients underwent conventional surgery. The results of the surgeries were based on: range of motion, functional recovery, and complications. The six athletes with exposure to the GFRP were able to recover their range of motion in 5-9 weeks, while it took 8-14 weeks for the patients of the control group to do the same. The experiment group patients were also able to take up gentle running sooner, and the cross sectional area of the recovered tendon was less than that of the control group.<sup>32</sup> An earlier rat Achilles tendon transection study demonstrated that mechanical stimulation was a prerequisite for platelets to work by day 14 and that both activity and platelets increased repair independently of each other.<sup>33</sup> This also may provide some rationale for the lack of a significant difference after 24 weeks between PRP- (27 subjects) and saline-injected (27 subjects) Achilles tendinopathy subjects in a recently published RCT. Of significance was that both groups received eccentric exercises and both significantly improved.<sup>34</sup> This confounding variable of exercise was also similarly seen in the earlier referenced Yelland dextrose prolotherapy study.

**Plantar Fasciitis.** Barrett et al performed a study in which nine patients with thickened plantar fascia were treated with 3 cc of autologous platelet concentrate (APC+) injections. The patients were then subjected to a lower leg brace for two days and monitored regularly for a year. Results of the study—obtained through ultrasound readings—indicated that the bands of the plantar fascia significantly decreased in thickness, signifying reduced swelling. Of the nine patients in the study, six patients fully recovered from all symptoms at two months, one patient recovered after dropping out of the experiment (due to corticosteroid usage), one showed improvement after a few more injections of APC+, and the last patient still felt pain during walking. From the study, it can be concluded that the success rate of the experiment was 77.8% (7 of 9 patients).<sup>35</sup>

**Anterior Cruciate Ligament (ACL).** Ventura et al performed a study to test the efficacy of growth factors on ACL surgery recovery. Twenty patients with laxity due to torn ACL underwent surgery using autologous hamstring tendons. The

patients were divided into one of two groups: growth factor-treated and control. The experimental group was treated with growth factors similar to the ones obtained from PRP. Results after six months indicated that the patients in the experiment group reported denser ACLs after recovery. One patient had a synovitic reaction, with hypertrophic tissue.<sup>36</sup> This was further supported by a canine ACL study showing that ACL defects treated with platelets had a 40% increase in strength at six weeks vs. 14% for those untreated with platelets.<sup>37</sup> Other arthroscopic-enhanced repairs include articular cartilage avulsion<sup>38</sup> and foot-ankle surgeries.<sup>39</sup> Its use in enhancing bone repair remains controversial (PRP possibly inhibits osteogenic action of bone morphogenetic proteins).<sup>40</sup>

**Rotator Cuff.** PRP-enhanced rotator cuff arthroscopic repair has been described in the past.<sup>41</sup> It is currently under study as well at Sunnybrook Health Sciences Centre as part of a National Institutes for Health (NIH) sponsored study.

**Lower Back Pain.** Numerous case reports include the treatment (using prolotherapy technique) for sub-acute low back pain and for chronic low back pain.<sup>42</sup>

### PRP in Combination With Prolotherapy

The combination of platelet rich plasma with prolotherapy has been demonstrated to have an improved outcome on the overall healing process both in this and previous case studies.<sup>44</sup> A pictorial illustration of the overall PRP prolotherapy procedure in the outpatient environment is presented in Figure 2. Typical injection sites are illustrated in Figure 3 (page 64) and methods for guiding injections are presented in Figures 4 and 5 (page 65).

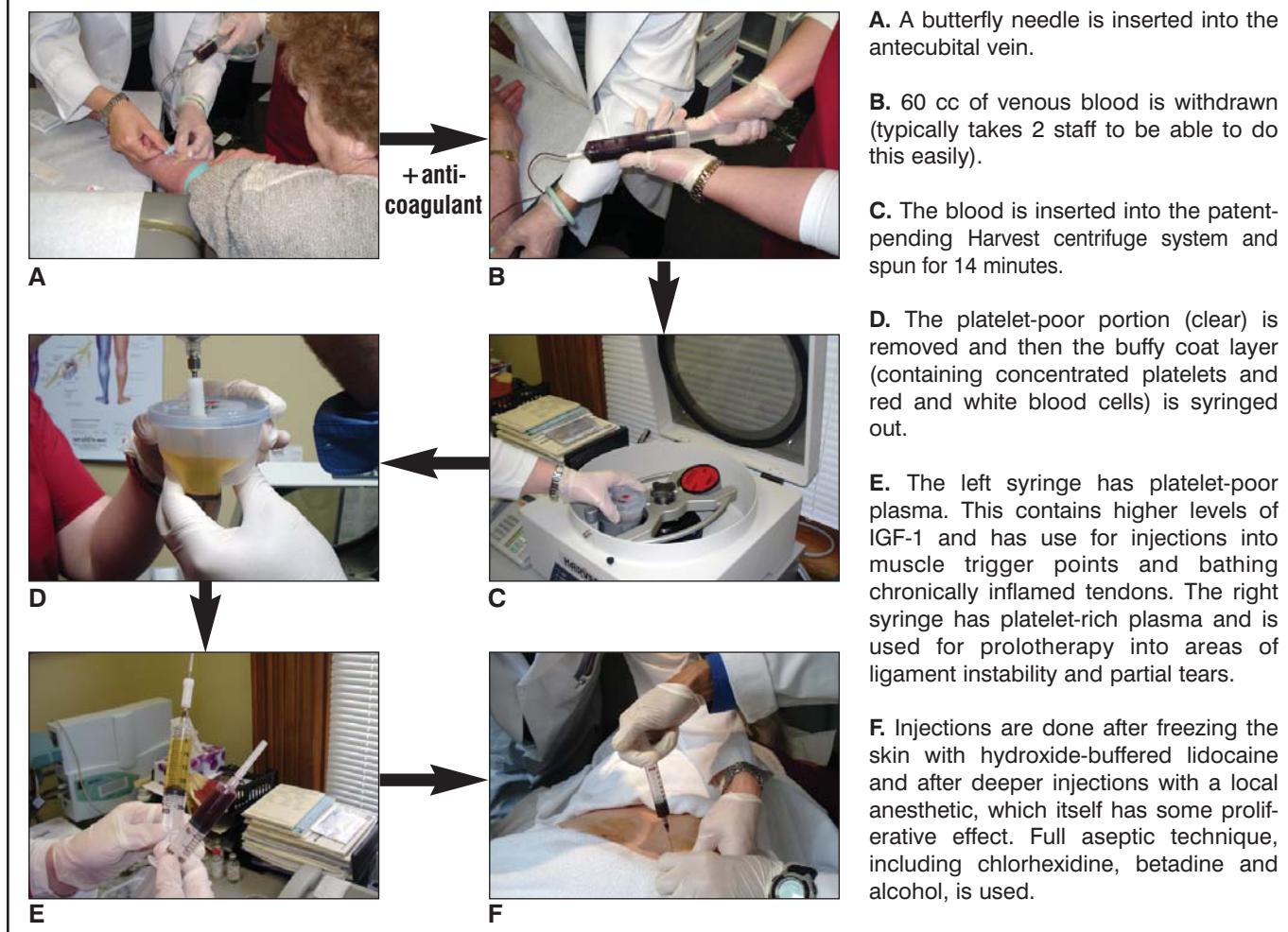
This article focuses on five case studies in which PRP prolotherapy treatment successfully improved the patients' joint pain conditions.

### Case Studies

#### Case 1

A 45-year-old former registered nurse, mother of three with pre-existing Ehlers-Danlos syndrome (see Figure 1) and anterior L3-S1 spinal fusion for scoliosis (at age 19) developed new onset left-sided low back pain following a car accident on April 20, 2007. She fell out of her wheelchair van after it had caught fire. She landed hard on her left hip and also hyper-extended her neck. She was seen

**FIGURE 2. PRP Prolotherapy Procedure**



by an orthopedic surgeon for an insurance exam and was told there was no treatment available. X-rays were negative for any fracture. MRI revealed some bony sclerosis in both SI joints. Blood work done in July 2008 revealed mildly elevated ESR 29mm/h but the rheumatoid factor, ANA and HLA-B27 tests were all negative. CBC was normal with a platelet count of 278 xE9/ L (normal is 150-400).

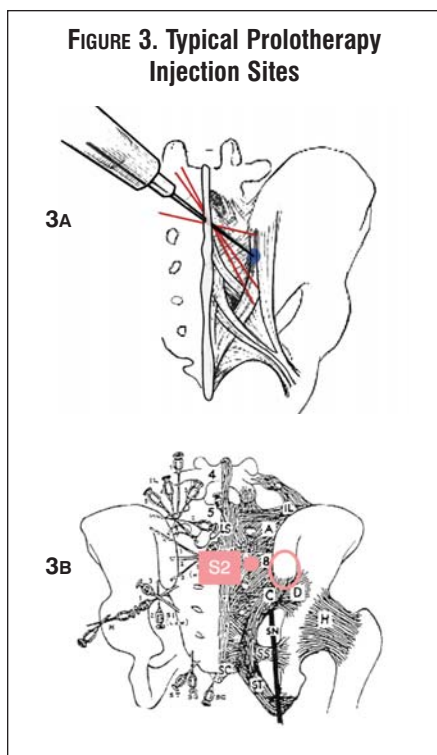
She attended physiotherapy and was noted to have a markedly unstable left sacroiliac joint. Even passive movement of the left leg would provoke a marked audible subluxation of the joint. She was unable to sit. When seen on Oct. 16, 2008, her numerical rating scale for pain (NRS) was 6-7/10, varying from a best of 6 to a worse of 9.5/10; average night time pain was 8/10; short-form McGill Pain Questionnaire (SFM) score was 34/45; and the Oswestry Low Back Pain and Disability

score was 46/50. She described associated burning pain with electric shocks, fatigue 8/10, anxiety 7/10, and decreased concentration 8/10. She had short-term relief with tramacet, advil (anaphylactic allergies to oxycodone, codeine), acupuncture, heat, and TENS. She could not sit for prolonged periods in her wheelchair and required help with dressing, cleaning, transferring, bathing, meal preparation and household chores. As she had trouble lying on her left side, she developed pressure sores in the right sacral area.

Past health included Gilbert's syndrome, previous cholecystectomy and three C-sections. She was a non-smoker and rarely drank alcohol. Family history include Ehlers-Danlos in her three children of which one had severe vascular involvement with dilated aorta. Both parents with diabetes, hypertension; father also with rheumatoid disease;

mother with breast cancer; and brother with fibromyalgia. Her physical exam revealed a reported height of 6'1" and weight of about 240 pounds, BP 124/99mm Hg. Pulse 95bpm. Signs of neuropathic pain in left leg, foot included vasomotor changes, colder skin temperature (Left big toe 23.1°C; Rt: 29.4°C) but without any brush allodynia. Only 4/18 fibromyalgia tender points on algometry. Whitmore-Gordons score of 42/60. Marked tenderness with grade 3 instability (no end feel) in both anterior-posterior and vertical stressing of the left SI joint. Secondary spasming noted of the adjacent piriformis muscle. Initial management with pregabalin helped with the left leg neuropathic pain. Naturopathic therapies (including four Myer's cocktail i.v. infusions) helped with her energy and sleep.

As she also had a history of adverse reac-



**FIGURE 3A.** Prolotherapy technique is typically done at Hackett's B and C points with up to 5 cc of PRP spread out at each site. About 0.5 cc injected at each contact with the periosteum-ligament interface. Particular attention is paid to avoid needling the sacral nerve roots (patients are never sedated and are asked to report any "electrical or radiating pain").

**FIGURE 3B.** Other common prolotherapy injection sites include the dorsal ligaments at Hackett's A, sacrotuberous ligaments, ilio-lumbar ligaments off the medial upper iliac crest and off the transverse processes of L4, L5. The vertebral supra and interspinous ligaments along with the facet capsules may also be treated based on the clinical examination correlated with radiological findings.

tions to local anesthetic, injections were administered without it. She underwent a trial of sodium morrhuate (mixed with dextrose) injections (March 3, April 7, May 5 and June 2, 2009) directed into the left sacroiliac ligaments at Hackett's B point (medial to the PSIS) and C point (inferior to the PSIS). A 3-inch 21-gauge needle was used with the prolotherapy technique requiring injection only with contact on the bony surface; 5 cc was administered at each site. There was no significant clinical improvement. A treatment plan for platelet-rich plasma prolotherapy (PRPP) injections was approved and she underwent injections using 5 cc

of PRP into each of the SI ligament sites on July 7, 2009. Following this, she noted significant improvement in pain and resolution of the "clunking" sensations. By Dec. 3, 2009 her NRS back pain was down to 3/10. On March 23, 2010, her Oswestry score was down to 5/50, SFM score 0/45, and NRS 0/10. She was no longer wheelchair confined and happily reported that she was back to her pre-accident status.

**Case 2**

A 67-year-old married mother of four, a retired CEO of a pediatric hospital, was seen with chronic low back pain. She had a previous posterior lumbar fusion from L4-S1 in 1977. In February 2008, she injured her low back playing tennis. While running to the net, she did a back-hand swing and felt a "snap" sensation in her back. She had physiotherapy and acupuncture with temporary relief. The back pain prevented her from playing sports and interfered with her ability to walk and sit for long periods. When seen on Oct. 30, 2008, she described pain in the right low back and buttock with radiation down the lateral thigh, skipping the knee and then into the lateral calf. There was no numbness or paresthesia. NRS pain was 4/10 (varying from 2-6/10, average night pain 5/10); SFMcGill 14/45; Oswestry 21/50; FMQ 24.8/80; and Whitmore-Gordons score of 33/60.

Past health included chronic sinusitis. She was a nonsmoker who drank alcohol occasionally. Family history included a daughter with non-Hodgkin's lymphoma. Physical exam revealed height 5'4 1/4" weight 130lbs. BP 112/79mm Hg. 1+ tenderness over right sacroiliac joint and trigger points in the iliopsoas and quadratus lumborum. There was 3+ instability of the right SI joint. Neurological exam and neural tension tests were negative. MRI revealed solid bone graft fusion from L4 to sacrum with severe degenerative changes in the SI joint, bone graft harvest from right ilium. Mild anterolisthesis of L4 on S1. Facet osteoarthritis and diffuse disc bulging from L1 to S1. L5-S1 central disc protrusion eccentric to right and displacing right S1 nerve root. EMG study including H-reflex studies was unremarkable. MRI pelvis revealed bilateral hip joint effusions with moderate articular cartilage loss and marginal osteophytes. She was treated with prolotherapy injections with sodium morrhuate (on Dec. 9, 2008; Jan. 6, Feb. 10 and Mar. 10, 2009)

without any improvement. She attempted to reduce inflammation by taking omega-3 fish oil capsules (her omega-3 FA profile blood test was abnormal with marked elevation of arachadonic acid to eicosapentanoic acid (29.4:1). She took supplements and improved her 25 (OH) vitamin D3 level from 89 to 178 nmol/L; serum ascorbic acid 42 (23-114) umol/L; serum zinc 14.4 (8.7-19.1) umol/L; IGF-1 60 (72-206) ug/L; serum B12 324 pmol/L; and ferritin 130 ug/L.

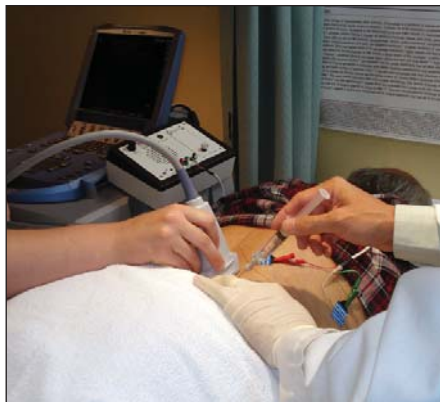
She underwent PRPP injections on April 14, 2009 at right Hackett's B point (5cc) and Hackett's C point (3.5cc). Ultrasound-guidance helped in localization. Noted clinical improvement "feeling back to normal" by one month later. A second PRPP was done on May 12, 2009, but directed to the left SI ligaments. She responded so well that she agreed to go on television to share her story. By November 2009, she was hiking in the Galapagos Islands and swimming with the sharks without any difficulty. Post-PRPP scores: NRS 1/10, ShortFM 2/45 and Oswestry 8/50, FIQ 6.86/ 70.

**Case 3**

A 29-year-old female single occupational therapist and avid dragon boat competitor developed gradual onset of right-sided low back pain. She was very physically active as a runner, and also participated in competitive basketball, hockey, and rock-climbing. She noted pain referral along the iliac crest and gluteus medius muscles (she knew her anatomy) along with a "popping" out feeling of her right sacroiliac joint. She was initially referred to a rheumatologist in September 2009 and underwent extensive bloodwork (including negative HLA-B27) and x-rays (normal spine, SI joints; mild OA right great toe MTP joint).

Past medical history includes inappropriate sinus tachycardia for which she takes Lopressor and cervical dysplasia. Family history includes father and grandparents with colon cancer. She was a nonsmoker and non-drinker. Physical examination revealed a measured height of 5'4 1/2", weight 136 lbs. BP 125/85 mm Hg. Pulse 60bpm regular. Back examination revealed full flexion with normal Schober's test and a Whitmore-Gordons score of 40/60. There was grade 3 instability of the right sacroiliac joint with spondylolisthesis of L4 on L5 > L5 on S1. Compensatory overuse of the gluteus





**FIGURE 4.** Ultrasound-guided injections are done for deeper structures (such as the hip joint, psoas and piriformis muscles). This is shown with Sonosite Inc.'s Micromaxx portable unit here. Other agents may be incorporated such as Botulinum-Toxin A, analgesic traumeel and intra-articular visco-supplements.



**FIGURE 5.** EMG guided injections (into muscle) can be done incorporating the hand-held Myoguide portable unit that provides both visual and auditory feedback. It also allows for E-stim to accurately localize muscles, motor points and peripheral nerves.

maximum and medius was noted. Despite efforts with myofascial therapy, core strengthening, IMS acupuncture, use of a sacroiliac belt, her progress with rehabilitation plateaued. Her NRS pain was 7/10; SFMcGill 26/45; and Oswestry 32/50.

She underwent two series of PRPP injections directed into the right sacroiliac ligaments at Hackett's A (1cc), B (4cc), C (3cc) and L4-5 and L5-S1 supra and interspinous ligaments (0.5cc each) and adjacent facets (0.5cc each) on Oct. 13 and Dec. 8, 2009. She estimates improving by 90% after her first treatment. The instability improved to a grade 1 rating. After the second treatment, she reported in

March 2010, that her NRS pain was 0/10, SFMcGill 0/45 and Oswestry 0/50. She was back to full sports and successfully competed in a world cup dragon boat competition in China.

#### Case 4

A 40-year-old married mother of four, a floral arranger and bookkeeper, was seen on Jan. 16, 2006, with a three-year history of gradual onset chronic low back pain. Symptoms began with a burning sensation in the lateral hips after intercourse. Pain was severe enough that she was prescribed Vioxx. She had trouble walking and became almost bedridden. Besides Vioxx, she also had chiropractic manipulation and physiotherapy. Ice would help to numb her back pain. Tylenol #3 helped minimally. She eventually was treated with Hydromorph Contin. She tried acupuncture. She had a flare-up of pain after an anesthesiologist cortisone epidural injection. She also had 4-5 sessions of osteopathy and neural therapy injections. Past medical history included a school bus accident over 20 years ago with a concussion but no back injury. She did not smoke and only drank alcohol socially.

Physical examination revealed a height 5'3" weight 155 lbs. BP 119/85mm Hg. Pulse 84bpm. She had full lumbar flexion 90 with limited painful extension 12 (normal is 30). Side flexion Lt 14, Rt 18 (normal is 30). She had tenderness in the SI joints bilaterally, but stability was normal. There was accompanying neuropathic pain signs with brush allodynia, pinprick hyperalgesia with wind-up phenomenon over the low back. Neural tension tests and neurologic exam of the legs were otherwise normal. Her NRS pain was 6-7/10 (best 3, worst 9, night 8-9/10); SFMcGill 36/45; feelings of anxiety, depression 5/10; fatigue 5/10; and Oswestry 34/50. Her allodynia was too severe for even topical rubs. This was controlled by first using a topical anesthetic spray (ketamine 10%, bupivacaine 0.75%). After 30 minutes, the topical gel (ketamine 10%, clonidine 0.2%, lidocaine 5% in lipoderm) could then be applied and was found to be helpful. With this, she was then able to undergo a series of marcaine injections (temporary relief), Botox injections q 3 months into the paraspinal muscles and piriformis muscles (helpful from March 9, 2006 to June 4, 2009). With this, she was able to wean off her hydro-

morph contin and progress with her physiotherapy. She then started seeing a chiropractor for neck pain and with spinal manipulations three times a week and noted improvement in her neck pain but increased pain in her low back. She described clicking and clunking sensations in her left hip. Whitmore-Gordons score of 40/60. Further back examination revealed a 'grade 2' right SI joint instability and hypermobility in the L4 to S1 segments.

She underwent PRPP injections (July 21, 2009) at Hackett's A point (1cc), B point (5cc), C point (3cc) and L5-S1 supra-interspinous ligaments (0.5cc) and facets (0.5cc each). She had increased pain for one week but then responded well to this with NRS down to 0-1/10 and overall report of 90% improvement. A repeat PRPP was done Sep. 15, 2009 with further improvement. She then unfortunately slipped and fell in late October, twisting her right ankle and re-injuring her low back. A third PRPP treatment was done on Jan. 12, 2010 with focus on the unstable left SI joint (grade 2) instability. In March 25, 2010, she reported that she still had residual pain in the left side with NRS 1/10; SFMcGill 5/45; and Oswestry 9/50. She was pleased to report, however, that her right side was completely pain-free. She continues to function at a high level, working full time and is off all her topical and oral pain medications.

#### Case 5

A 48-year-old former environmental industry executive and current fourth year naturopathic medicine student was seen on May 26, 2006 upon referral from a teaching hospital pain clinic anesthesiologist. She had a three year history of persistent chronic low back pain (localized to the left SI joint) following a fall on the left hip while rollerblading. Subsequent x-rays were negative for any fracture. CT and MRI scans revealed no sacroiliac joint pathology, but did show concentric disc bulges and facet osteoarthropathy at L3-4, L4-5, L5-S1. Grade 1 anterolisthesis noted at L4-5 and spondylolysis at L5. Bone scan showed mild increased activity consistent with arthritic changes in the left side of the hip and pelvis. EMG studies were unremarkable. She underwent extensive sports medicine physiotherapy and had massage and chiropractic treatment. The use of low dose pregabalin (25mg bid) was

**APPENDIX A.  
WHITMORE-GORDONS SACROILIAC INSTABILITY TOOL**

Please circle ONE number corresponding to the statement in EACH question that BEST describes your low back pain.

	NEVER	RARELY	SOMETIMES	OCCASIONAL	OFTEN	ALWAYS
1. I have pain in my buttock.	0	1	2	3	4	5
2. My back feels unstable.	0	1	2	3	4	5
3. I get pain (in the low back-buttock area) when I turn in bed.	0	1	2	3	4	5
4. I get pain (same area) when I get out of a low chair.	0	1	2	3	4	5
5. I get pains (same area) when I bend the leg up (such as to put on my sock).	0	1	2	3	4	5
6. I get pain (same area) when going up or down stairs.	0	1	2	3	4	5
7. I feel clicking/ clunking/ popping (same area) when I move.	0	1	2	3	4	5
8. I have had the following injuries to my low back:						
___ a) motor vehicle accident with foot on brake at time of impact (score as 5)						
___ b) fall on the same buttock or hip (score as 5)						
___ c) women: pregnancy-related pelvic pain (score as 5)						
___ c) men: unexplained pain (normal urology studies) referred into the testicle (score as 5)						
___ d) temporary relief with spinal manipulation or sacroiliac belt (score as 5)						
___ e) sports or work-related twisting-lifting injury—e.g., bowling, figure skating, etc. (score as 3)						
___ f) history of hypermobile “loose” joints (score as 2)						
<b>Total Score</b> ___/60						

**Scoring:** Preliminary data on consecutive patients suggests a score over 30 has a sensitivity of 85% and specificity close to 100% (with exclusion of fibromyalgia patients) in correlating with an unstable sacroiliac joint that would respond to the PRP prolotherapy treatment.<sup>43</sup> (This is to be further studied with multivariate logistic stepwise regression analysis on a larger number of patients.)

helpful in reducing pain including sciatica symptoms in the left leg. She took extensive herbals including Devil’s Claw, fish oil, tumeric, glucosamine chondroitin sulfate.

Past medical history included previous mild scoliosis documented at the T3 level, premenstrual syndrome, and fractures of the left first and second toes. She was a non-smoker, drank alcohol occasionally and ate a mostly vegetarian diet. Her NRS pain 7/10; SFMcGill 23/45; and Oswestry 36/50. Pain was in the midline lower lumbar and parasacral region with radiation into both groins and down the left lateral thigh. Sitting and standing tolerance was limited to 5 to 15 minutes. Physical exam revealed a height of 5’1” and weight 148 lbs. BP 101/67mm Hg. Pulse 84bpm. Straight leg raising was limited to 75 degrees on the left with back pain (no sciatica). Maneuvers of the SI joints provoked pain (including Patrick’s, Faber, Gaenslen, Gillett, Yeomen and shear tests), primarily on the left side. Stability testing revealed 2+ instability in the left SI joint.

She underwent PRPP injections to the left SI joint (Hackett’s B and C points) with 15% dextrose (July 29, 2008—complicated by increased pain which was treated with traumeel-marcaine injections into the piriformis muscles) and then with sodium morrhuate (Hackett’s A,B,C and L4-5 facets, interspinous ligaments for five sessions on Aug. 19, Oct. 14, Nov. 4, Dec. 9, 2008, Feb. 10, 2009) with good results and improved stability. NRS was down to 3/10 and she felt 80% improved. Unfortunately, this was all set back when she was rear-ended in a car accident on April 25, 2009 with NRS pain back up to 7/10. Her right SI joint (foot on brake side) was 3+ unstable. Whitmore-Gordons score 41/60. She received approval from the insurer for PRPP and this was administered on July 14, 2009 (Rt. Hackett’s A, B, C points and L4-5 interspinous and facet ligaments) and repeated on the left side Sept. 18, 2009 (in which additional PRPP to the C6-7 facets also helped to resolve the post-MVA neck pain). Her low back pain measures on March 2010 (6 months post-PRPP) were NRS 1.5/10; SFMcGill 2/45; and Oswestry 4/50. She successfully got married, graduated from naturopathic college and returned back to full activity and sport (pool and weight exercises, cross country skiing).



**Conclusion**

These case studies suggest a role for PRP prolotherapy in the management of chronic low back pain—particularly in those with sacroiliac joint pain and instability. Such cases studies and the newly-described screening tool need to be validated with more research, including double-blind randomized controlled trials.■

**Acknowledgements**

Special thanks to the multidisciplinary team at the Canadian Centre for Integrative Medicine: Scott Whitmore, BScPT, FCAMT; Gordon Lawson, MSc, DC; Mark Tsai, MScPT, FCAMT; Thomas Hein, BScPT, FCAMT; Rob McDonald, BSc, RMT DiplOsteo; Kevin Ho, RN, DC; Leigh Arsenneau, BSc, ND; Melanie Eitel, RMA; and Rebecca Chau, RNA.

*Gordon D. Ko, MD, CCFP(EM), FRCPC, FABPMR, FABPM, is Medical Director, Physiatry Interventional Pain clinics at Sunnybrook Health Sciences Centre, University of Toronto and the Canadian Centre for Integrative Medicine (CCIM, Markham). He is Associate Professor, Rutherford University and Lecturer, Department of Medicine, University of Toronto. His expertise integrates neuropathic pain medications, functional medicine (including bio-identical hormone therapy) with EMG-guided Botox, Xeomin and ultrasound-guided viscosupplements/Platelet Rich Plasma prolotherapy. In CCIM, he leads a multidisciplinary team including specialized physiotherapists, chiropractors, osteopaths, psychotherapist and naturopathic doctors. He is author of an upcoming book “Pain-Free Healthy Aging: Fibromyalgia—Moving from Pain to Optimal Function” which will be available later this year on his website, www.DrKoPRP.com*

**References**

1. Dreyfuss P, Michaelsen M, Pauza K, et.al. The value of medical history and physical examination in diagnosis of sacroiliac joint pain. *Spine*. 1996. 21: 2594-2602.
2. Slipman CW, Sterenfild EB, Chou LH, et.al. The predictive value of provocative sacroiliac joint stress maneuvers in the diagnosis of sacroiliac joint syndrome. *Arch Phys Med Rehabil*. 1998. 79: 288-292.
3. Maigne JY, Aivaliklis A, and Piefer F. Results of sacroiliac joint double block and value of sacroiliac pain provocation tests in 54 patients with low back pain. *Spine*. 1996. 21: 1889-1892.
4. Schwarzer AC, Wang SC, Bogduk N, et.al. The sacroiliac joint in chronic low back pain. *Spine*. 1995. 20: 31-37.
5. Lee JH, Lee SH, and Song SH. Clinical effectiveness of Botulinum Toxin A compared to a mixture of steroid and local anesthetics as a treatment for sacroiliac joint pain. *Pain Med*. 2010. 11: 692-700.

6. Alderman D and Sweeting RC. Prolotherapy for sacroiliac joint laxity. *Pract Pain Manag*. May 2009. 9(4): 44-46.
7. Vleeming A, Snijders CJ, Stoeckart R, et.al. The role of the sacroiliac joints in coupling between spine, pelvis, legs and arms. In: Vleeming A et al. (eds). *Movement, stability and low back pain*. Churchill Livingstone. Edinburgh. 1997.
8. Goldthwait JE and Osgood RB. A consideration of the pelvic articulations from an anatomical, pathological and clinical standpoint. *Boston Med & Surg J*. 1905. CLII No. 21.
9. Stuesson B, Selvik G, and Uden A. Movements of the sacroiliac joints. A roentgen stereophotogrammetric analysis. *Spine*. 1989. 14: 162-165.
10. Kissling RO and Jacob HAC. The mobility of sacroiliac joints in healthy subjects. In: Vleeming A et al (eds). *Movement, stability and low back pain*. Churchill Livingstone. Edinburgh. 1997.
11. Smidt GL, Wei SH, McQuade K, et al. Sacroiliac motion for extreme hip positions. A fresh cadaver study. *Spine*. 1997. 22: 2073-2082.
12. Wang M and Dumas GA. Mechanical behavior of the female sacroiliac joint and influence of the anterior and posterior sacroiliac ligaments under sagittal loads. *Clin Biomech*. 1998. 13: 293-299.
13. Liu YK, Tipton CM, et.al. An in situ study of the influence of a sclerosing solution in rabbit medial collateral ligaments and its junction strength. *Connective Tissue Research*. 1983. 11: 95-102.
14. Maynard JA, Pedrini VA, et.al. Morphological and biochemical effects of sodium morrhuate on tendons. *J Orthop Res*. 1985. 3: 236-248.
15. Klein RG, Dorman TA, and Johnson CE. Proliferant injections for low back pain: histologic changes of injected ligaments & objective measurements of lumbar spine mobility before & after treatment. *J Neurol Orthop Med Surg*. 1989. 10: 141-144.
16. Gedney E. Special technic hypermobile joint: a preliminary report. *Osteopathic Profession*. 1937. 4(9):30-31.
17. Topol GA, Reeves KD, and Hassanein K. Efficacy of dextrose Prolotherapy in elite male kicking-sport athletes with chronic groin pain. *Arch Phys Med Rehabil*. 2005. 86: 697-702.
18. Centeno CJ, Elliott J, Elkins WL, and Freeman M. Fluoroscopically guided cervical Prolotherapy for instability with blinded pre and post radiographic reading. *Pain Physician*. 2005. 8: 67-72.
19. Reeves KD. Treatment of consecutive severe fibromyalgia patients with prolotherapy. *J Orthop Med*. 1994. 3: 84-89.
20. Reeves KD and Hassanein K. Randomized prospective double-blind placebo-controlled study of dextrose prolotherapy for knee osteoarthritis with or without ACL laxity. *Altern Ther Health Med*. 2000. 6: 68-80.
21. Reeves KD and Hassanein K. Randomized, prospective, placebo-controlled double-blind study of dextrose prolotherapy for osteoarthritic thumb and finger (DIP, PIP, and Trapeziometacarpal) joints: evidence of clinical efficacy. *J Altern Complement Med*. 2000. 6: 311-320.
22. Ongley MJ, Klein RG, Dorman TA, and Eck BC. A new approach to the treatment of chronic low back pain. *Lancet*. 1987. 2: 143-146.
23. Klein RG, Bjorn CE, DeLong B, and Mooney V. A randomized double-blind trial of dextrose-glycerine-phenol injections for chronic low back pain. *J Spinal Disord*. 1993. 6: 23-33.
24. Marx RE. Platelet-rich plasma: evidence to support its use. *Clinical Controversies in Oral and Maxillofacial Surgery: Part two. J Oral Maxillofac Surg*. 2004. 62: 489-496.

25. Sampson S, Gerhardt M, and Mandelbaum B. Platelet rich plasma injection grafts for musculoskeletal injuries: a review. *Curr Rev Musculoskelet Med*. 2008. 1-10.
26. Mishra A, Woodall J, and Vieira A. Treatment of tendon and muscle using platelet-rich plasma. *Clin Sports Med*. 2009. 28: 113-125.
27. Crane D, Everts P. Platelet Rich Plasma Matrix Grafts. *Pract Pain Manag*. Jan-Feb 2008. 8(1): 1-10.
28. Elder CL, Dahners LE, and Weinhold PS. A cyclooxygenase-2 inhibitor impairs ligament healing in the rat. *Amer J Sports Med*. 29: 801-805.
29. Ferrari M, Zia S, Valbonesi M, et.al. A new technique for hemodilution, preparation of autologous platelet-rich plasma and intraoperative blood salvage in cardiac surgery. *Int J Artif Org*. 1987. 10: 47-50.
30. Mishra A and Pavelko T. Treatment of chronic elbow tendinosis with buffered platelet-rich plasma. *Am J Sports Med*. 2006. 34:1774-1778.
31. Peerbooms JC, Sluimer J, Bruijn DJ, and Gosens T. Positive effect of an autologous platelet concentrate in lateral epicondylitis in a double-blind randomized controlled trial. *Am J Sports Med*. 2010. 38: 255-262.
32. Sanchez M, Anitua E, Azofra J, et.al. Comparison of surgically repaired achilles tendon tears using platelet-rich fibrin matrices. *Am J Sports Med*. 2007. 35: 245-251.
33. Virchenko O and Aspenberg P. How can one platelet injection after tendon injury lead to a stronger tendon after 4 weeks? *Acta Orthopaedics*. 2006. 77: 806-812.
34. deVos RJ, Weir A, vanSchie HTM, et.al. Platelet-rich plasma injection for chronic Achilles tendinopathy: a randomized controlled trial. *JAMA*. 2010, 303: 144-149.
35. Barrett SL and Erredge SE. Growth factors for chronic plantar fasciitis? *Podiatry Today*. 2004. 17:37-42.
36. Ventura A et al. Use of growth factors in ACL surgery: preliminary study. *J Orthop Traumatology*. 2005. 6: 76-79.
37. Murray MM, Spindler KP, Devin C, et al. Use of a collagen-platelet rich plasma scaffold to stimulate healing of a central defect in the canine ACL. *J Orthop Res*. 2006. 24: 820-830.
38. Sanchez M, Azofra J, Anitua E, et.al. Plasma rich in growth factors to treat an articular cartilage avulsion: a case report. *Med Sci Sports Exerc*. 2003. 35(3): 1648-1652.
39. Koerner J, Abdelmessieh P, Azad V, et al. Platelet-rich plasma and its uses in foot and ankle surgery. *Techniques in Foot & Ankle Surgery*. 2008. 7: 72-78.
40. Gruber R, Kandler B, Fischer MB, and Watzek G. Osteogenic differentiation induced by bone morphogenetic proteins can be suppressed by platelet-released supernatant in vitro. *Clin Oral Implants Res*. 2006. 17: 188-193.
41. Gamradt SC, Rodeo SA, and Warren RF. Platelet rich plasma in rotator cuff repair. *Techniques in Orthopaedics*. 2007. 22: 26-33.
42. Alderman D and Sweeting R. Prolotherapy for sacroiliac joint laxity. *Pract Pain Manag*. May 2009. 9(4): 44-46.
43. Ko GD, Whitmore S, Lawson GE, Greenberg C, Arseneau L, and Fung M. Platelet-rich plasma injections for sacroiliac joint pain: case series with preliminary screening tool and literature review. *Clin J Pain*. 2010. (in press).
44. Hauser RA, Philips HJ, and Maddella H. Platelet Rich Plasma Prolotherapy as First-Line Treatment For Meniscal Pathology. *Pract Pain Manag*. Jul/Aug 2010. 10(6): 53-64, 75.