

## FANTASTIC FINDINGS

# The Case for Utilizing Prolotherapy as First-Line Treatment for Meniscal Pathology:

## A Retrospective Study Shows Prolotherapy is Effective in the Treatment of MRI-Documented Meniscal Tears and Degeneration

Ross A. Hauser, MD, Hilary J. Phillips, and Havil S. Maddela

### ABSTRACT

Meniscus injuries are a common cause of knee pain, accounting for one sixth of knee surgeries. Tears are the most common form of meniscal injuries, and have poor healing ability primarily because less than 25% of the menisci receive a direct blood supply. While surgical treatments have ranged from total to partial meniscectomy, meniscal repair and even meniscus transplantation, all have a high long-term failure rate with the recurrence of symptoms including pain, instability, locking, and re-injury. The most serious of the long-term consequences is an acceleration of joint degeneration. This poor healing potential of meniscus tears and degeneration has led to the investigation of methods to stimulate biological meniscal repair. Research has shown that damaged menisci lack the growth factors to heal. In vitro studies have found that growth factors, including platelet derived growth factor (PDGF), transforming growth factor (TGF), and others, augment menisci cell proliferation and collagen growth manifold. Animal studies with these same growth factors have confirmed that meniscal tears and degeneration can be stimulated to repair with various growth factors or solutions that stimulate growth factor production. The injection technique whereby the proliferation of cells is stimulated via growth factor production is called Prolotherapy. Prolotherapy solutions can include dextrose, human growth hormone, platelet rich plasma, and others, all of which stimulate connective tissue cells to proliferate.

A retrospective study was done involving 24 patients, representing 28 knees, whose primary knee complaints were due to meniscal pathology documented by MRI. The average number of Prolotherapy visits was six and the patients were followed on average 18 months after their last Prolotherapy visit. Prolotherapy caused a statistically significant decline in the patients' knee pain and stiffness. Starting and ending knee pain declined from 7.2 to 1.6, while stiffness went from 6.0 to 1.8. Prolotherapy caused large improvements in other clinically relevant areas such as range of motion, crepitation, exercise,

and walking ability. Patients stated that the response to Prolotherapy met their expectations in 27 out of the 28 knees (96%). Only one out of the 28 patients ended up getting surgery after Prolotherapy. Based on the results of this study, Prolotherapy appears to be an effective treatment for meniscal pathology. While this is only a pilot study, the results are so overwhelmingly positive that it warrants using Prolotherapy as first-line therapy for meniscal pathology including meniscal tears and degeneration.

*Journal of Prolotherapy*. 2010;2(3):416-437.

**KEYWORDS:** human growth hormone, meniscal degeneration, meniscal tear, meniscus, platelet rich plasma, Prolotherapy.

### EPIDEMIOLOGY OF MENISCAL INJURIES

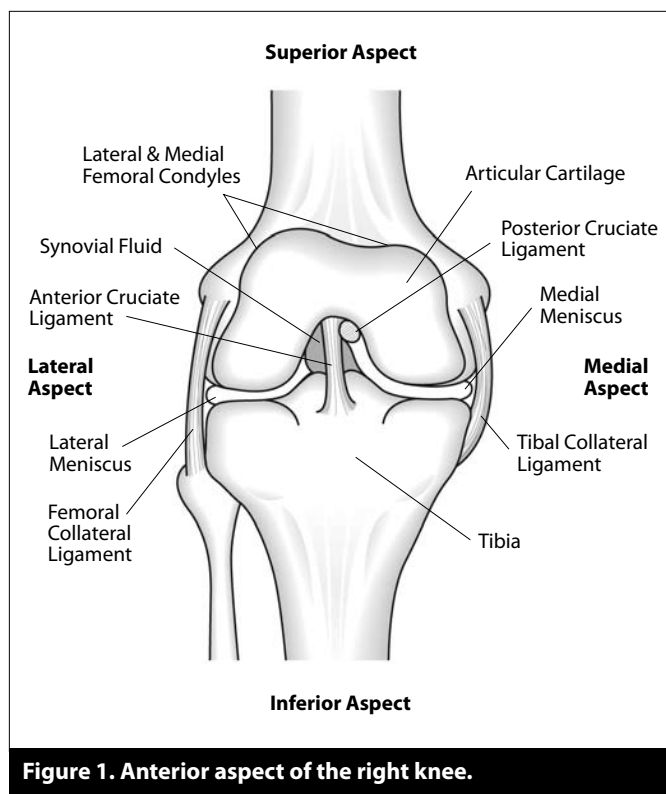
**K**nee injuries are a common concern resulting in over 1 million surgeries performed to the knee in the United States every year.<sup>1-3</sup> According to the National Athletic Trainers' Association, knee injuries account for 10% to 19% of high school sports injuries and 60.3% of all high school athletic-related surgeries.<sup>4</sup> Similar studies of collegiate sports have shown that knee injuries make up 7% to 54% of athletic injuries, varying by the nature of the sport.<sup>5-9</sup> The leading injuries to the knee, in both adults and children alike, are primarily patellofemoral derangements or ligament strains and tears.<sup>10-12</sup> Secondary to these injuries are meniscal tears, which have generated particular interest in both the young and elderly population as studies over the past several decades have revealed a rise in both degenerative and traumatic meniscal injuries. Meniscal tears occur as early as childhood, where they serve as the leading cause of pediatric arthroscopy, and increase with age and activity.<sup>13,14</sup> An estimated one sixth of knee surgeries are

performed for lesions of the meniscus, and it is likely that many more remain untreated every year.<sup>15, 16</sup> In one study of cadaver knees, untreated meniscal lesions were found in 34% of the autopsied subjects.<sup>17</sup>

A significant percentage of meniscal injuries result from athletic injury. On a professional level, meniscal tears accounted for 0.7% of all injuries sustained in the National Basketball Association, totaling 3,819 days missed by NBA athletes over a 10 year span.<sup>18</sup> In college sports, studies conducted over a 16 year span by the National Collegiate Athletic Association Injury Surveillance System found internal knee derangement was second only to ankle sprains in both men's and women's college basketball and men's and women's soccer.<sup>5-8</sup> An independent study of college football had equally devastating statistics, reporting injuries to the meniscus in roughly one in five elite college football athletes.<sup>9</sup> With participation in college sports on the rise, the number of meniscal injuries and subsequent surgeries are consequently rising at an alarming rate.<sup>19</sup> Although athletes appear to have the highest instance of injury, meniscus injuries can happen anywhere, regardless of a person's level of activity. A research study conducted in Greece showed that meniscal tears developed equally from traumatic and non-traumatic causes with 72% of all meniscal tears occurring during normal activities of daily living.<sup>20</sup>

#### ANATOMY & FUNCTION

The menisci (plural of meniscus) are a pair of C-shaped fibrocartilages which lie between the femur and tibia in each knee, extending peripherally along each medial and lateral aspect of the knee. (See Figure 1.) The anatomy of both menisci is essentially the same, with the only exception being that the medial meniscus is slightly more circular than its hemispherical lateral counterpart. Each meniscus has a flat underside to match the smooth top of the tibial surface, and a concave superior shape to provide congruency with the convex femoral condyle. Anterior and posterior horns from each meniscus then attach to the tibia to hold them in place. The meniscus is comprised of approximately 70% water and 30% organic matter. This organic matter is primarily a fibrous collagen matrix consisting of type I collagen, fibrochondrocytes, proteoglycans, and a small amount of dry noncollagenous matter.<sup>21, 27</sup> There has been a great deal of speculation and research dedicated to what exact function the meniscus serves, but today there is general consensus that the menisci provide stability in the joint, nutrition and



**Figure 1. Anterior aspect of the right knee.**

lubrication to articular cartilage, and shock absorption during movement.<sup>21-25</sup>

The menisci provide stability to the knee joint by both restricting motion and providing a contour surface for tibiofemoral bone tracking. The function of stability is shared with several ligaments which work together to prevent overextension of any motion. The transverse ligament connects the two menisci in the front of each knee and prevents them from being pushed outside of the joint at any point. Hypermobility is avoided through the connection of the medial collateral ligament (MCL) to the medial tibial condyle, femoral condyle, and medial meniscus, and the connection of the lateral collateral ligament (LCL) to the lateral femoral epicondyle and the head of the fibula; these ligaments provide tension and limit motion during full flexion and extension, respectively. The anterior and posterior meniscofemoral ligaments form an attachment between the lateral meniscus and the femur and remain taut during complete flexion. Lastly, the anterior cruciate ligament (ACL) and posterior cruciate ligament (PCL) are responsible for preventing too much backward or forward motion of the tibia.<sup>23, 24</sup>

The menisci also provide shock absorption and stability by equally distributing weight across the joint. It is

estimated that 45% to 70% of the weight-bearing load is transmitted through the menisci in a completely intact joint.<sup>21</sup> By channeling the majority of this weight evenly, the meniscus is able to avoid placing too much direct stress at any one point of the knee. In turn, proper weight transmission in the knee reduces stress on any other joints in the body affected by load bearing.<sup>25</sup>

One of the most vital roles of the meniscus is to provide lubrication to the knee, which it accomplishes through diffusing synovial fluid across the joint. Synovial fluid provides nutrition and acts as a protective measure for articular cartilages in the knee.<sup>26</sup> The femoral condyle in the knee is covered in a thin layer of articular cartilage, which serves to reduce motional friction and to withstand weight bearing. This cartilage is very susceptible to injury both because of its lack of proximity to blood supply and the high level of stress placed on it by excessive motion.<sup>27,28</sup> The meniscus, therefore, is able to provide a much-needed source of nutrition to the femoral and tibial articular cartilage by spreading fluid to that avascular area.

By acting as a spacer between the femur and tibia, the meniscus eliminates any direct contact between the bones, preventing any contact wear.<sup>29</sup> To see what effect the presence of the meniscus has on degeneration within the knee, researchers from the UK at the Institute of Medical and Biological Engineering conducted an in vitro study by mounting dissected bovine knee joints in a pendulum friction simulator and monitoring wear on knee cartilage both with and without a meniscus. Their results showed no change in surface integrity or loss of cartilage with

an intact meniscus, but removal of the meniscus resulted in immediate surface wear and cartilage deterioration.<sup>30</sup>

The ability to preserve the meniscus, unfortunately, is somewhat hampered by the fact that only a very small percentage (10% to 25% peripherally) of the meniscus receives direct blood supply.<sup>31</sup> This area is often referred to as the red zone, and the inner portion of the meniscus which does not receive blood supply is referred to as the white zone. (See Figure 2.) While the red zone has a moderate chance of healing from injury, the white zone is almost completely incapable of healing itself in the event of injury.<sup>32</sup>

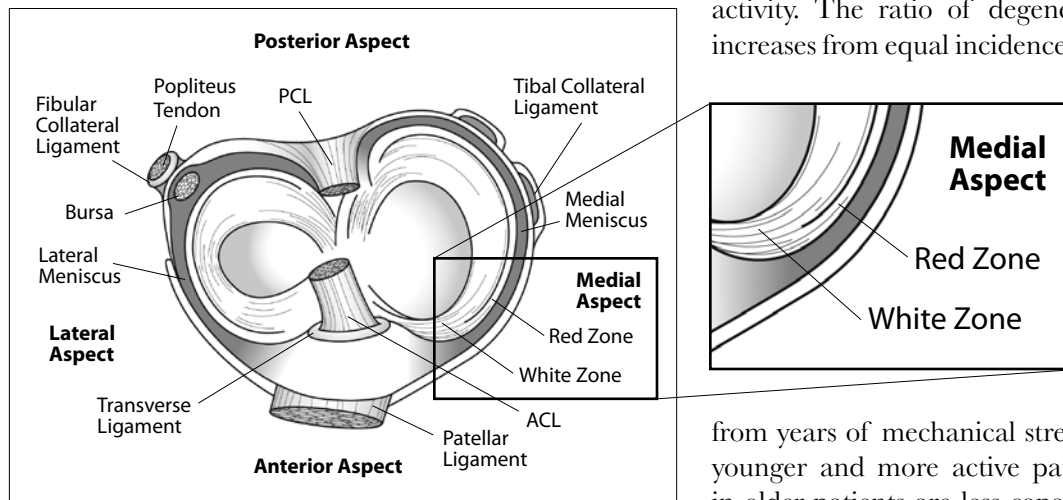
INJURY

Tears are the most common form of meniscal injury, and are generally classified by appearance into four categories: longitudinal tears (also referred to as bucket handle tears), radial tears, horizontal tears, and oblique tears.<sup>33</sup> (See Figure 3.) Research indicates that radial or horizontal tears are more likely to occur in the elderly population while younger patients have a higher incidence of longitudinal tears.<sup>34-36</sup> Each can be further described as partial thickness tears or complete thickness tears, depending on the vertical depth of the tear. (See Figure 4.)

Meniscal damage can be caused by either trauma or gradual degeneration. Traumatic injury is most often a result of a twisting motion in the knee or the motion of rising from a squatting position, both of which place particular strain and pressure on the meniscus. More often than not, traumatic injuries occur during athletic activity. The ratio of degenerative to traumatic tears increases from equal incidence in those under 20 years of

age to a ratio of 7:8 in the 30 to 39 age group, to nearly 4:1 in individuals over the age of 40.<sup>20</sup> This pattern of increased degenerative breakdown is to be expected with age, as joint wear will result

from years of mechanical stress. Unlike the anatomy of younger and more active patients, however, the fibers in older patients are less capable of healing themselves, due to decreased diffusion of synovial fluid with lessened motion.<sup>37</sup>



**Figure 2. Superior aspect of right knee showing red and white zones.**

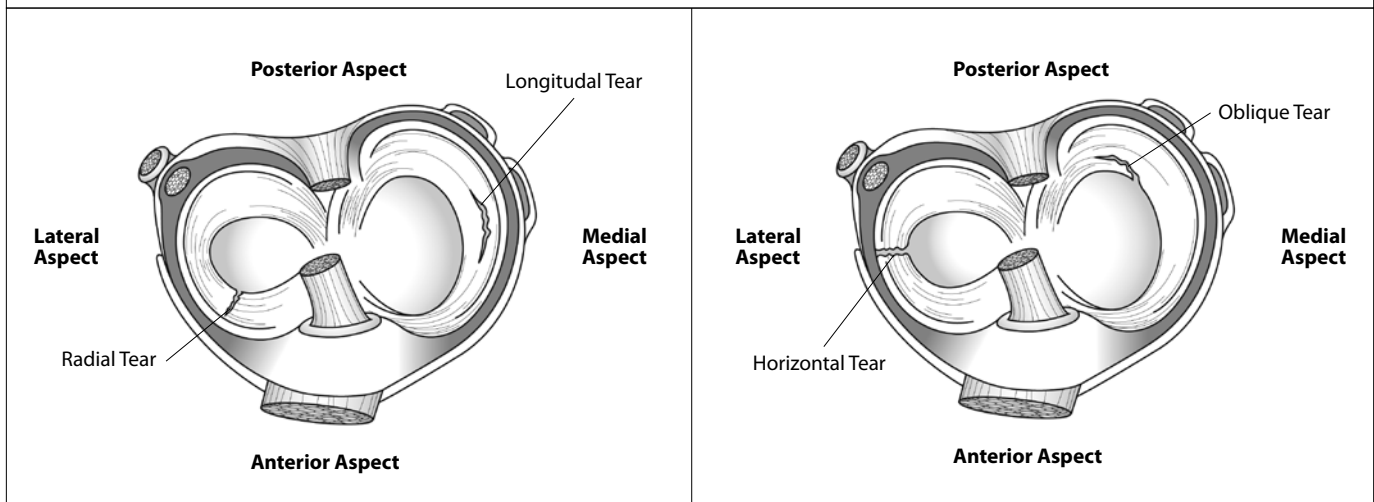
**Longitudinal (bucket handle) Tears** – vertical tear around the long axis of the meniscus often with displacement of the inner margin (bucket handle).

**Radial Tears** – extend from the medial rim toward the lateral rim of the meniscus.

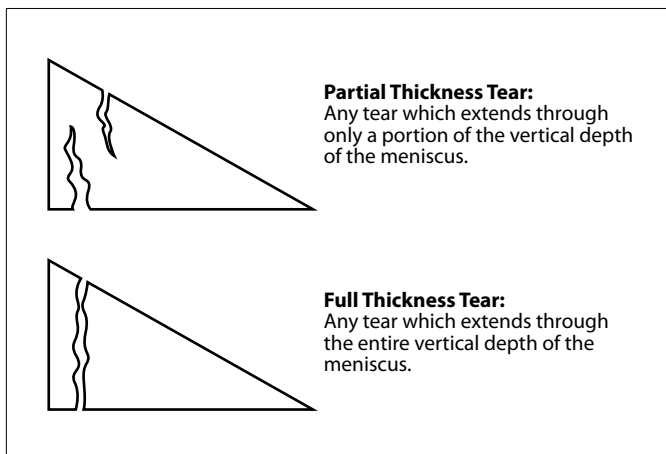
**Horizontal Tears** – tears that are in the same horizontal axis as the meniscus tissue.

**Oblique Tears** – full thickness tears running obliquely from the inner edge of the meniscus out into the body of the meniscus.

**Complex Tears** – more than one of the above patterns.



**Figure 3. Common types of meniscal tears.**



**Figure 4. Depths of tears in the meniscus.**

**Partial Thickness Tear:**  
Any tear which extends through only a portion of the vertical depth of the meniscus.

**Full Thickness Tear:**  
Any tear which extends through the entire vertical depth of the meniscus.

the onset of pain may be more gradual, with no definite moment of injury. In both cases, pain may be accompanied by swelling and subsequent limitation in range of motion. Another hallmark of meniscal tears is clicking, popping, or locking in the knee joint. These symptoms are most likely a result of a torn flap of meniscal tissue which catches in the joint during movement. Instability and weakness are also both common symptoms because a damaged meniscus, as well as damaged ligaments and tendons, inhibits normal mechanical function.

The severity of initiating trauma, as well as the nature and characteristics of the tear, plays an important role in the meniscus' ability to heal. (See Figure 6.) Tears that are shorter, partial thickness, and located in the vascular red zone have a much better chance of healing than extensive, complete thickness tears located in the white zone.<sup>38, 39</sup> When other cartilages and ligaments are injured in the knee, this can also have a detrimental effect on the meniscus' ability to heal on its own. Because of the interdependence of each of the knee's mechanisms,

A basic ability to identify meniscal tear symptoms is essential for diagnosis and treatment of injury. (See Figure 5.) The first symptom typically indicative of a meniscal tear is pain. In the case of a traumatic tear, pain may present immediately at the time of injury and is often accompanied by an audible pop. In a degenerative tear,

### Symptoms of Meniscus Tears

- Clicking or popping
- Decreased knee range of motion
- Instability
- Joint line tenderness
- Locking
- Pain
- Swelling
- Weakness

**Figure 5. Symptoms of meniscus tears.**

### More Likely to Heal

- Males
- Patients <50 years old
- Patients with BMI < 40
- Traumatic tears
- Red zone tears
- Radial or oblique tears
- Partial thickness tears
- Shorter tears
- Lateral meniscus
- Isolated tears

### Less Likely to Heal

- Females
- Patients 50+ years old
- Patients with BMI > 40
- Degenerative tears
- White zone tears
- Horizontal or longitudinal tears
- Complete thickness tears
- Longer tears
- Medial meniscus
- Tears with associated injuries

**Figure 6. Factors affecting the healing of a torn meniscus.**

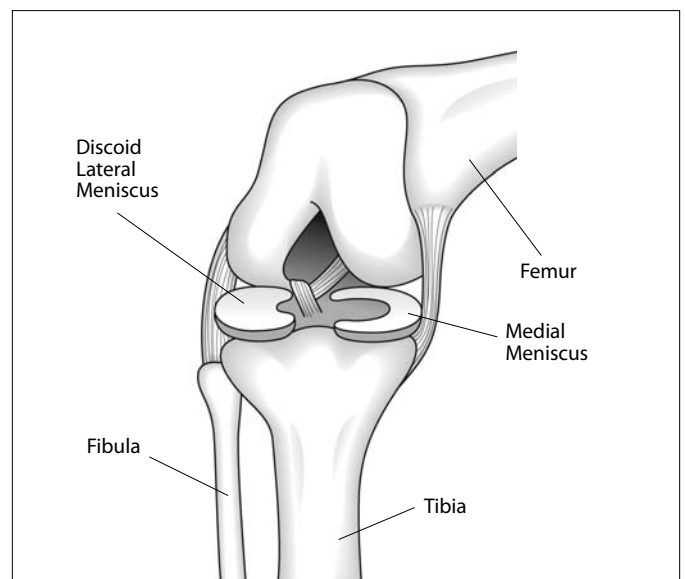
meniscal injuries often occur in conjunction with other internal ligament damage; the most common example of this is O’Donoghue’s “unhappy triad,” the correlated injury of the meniscus (debatably either medial or lateral), tibial collateral ligament, and ACL.<sup>40-42</sup> The severity of meniscal lesions has been found to increase in direct proportion to ACL injury and/or laxity, and create less favorable conditions for repair.<sup>43</sup> Furthermore, previous injury to either the meniscus or any other ligament inside the knee can increase the risk of future injury to the meniscus, even if the injury has healed or been surgically repaired.

Another condition which can be both a cause and complication of meniscal tears is a discoid meniscus. (See Figure 7.) A discoid meniscus occurs when the lateral meniscus takes on the shape of a disc, rather than a crescent, and is most often manifested in adolescence.<sup>44</sup> Although the cause has never been officially determined, the repercussions of a discoid meniscus have been widely documented. Often referred to as “snapping knee syndrome,” this condition is identified with its only symptom, snapping on extension. The “snap” is caused when the femur and the meniscus are not able to move in sync with each other and the femur either slips over a

ridge in the meniscus or off of the meniscus altogether.<sup>45</sup> Unlike the normal meniscus, which is shaped to fit the condyle of the femur, a discoid meniscus lacks the configuration to serve as a stable surface for motion. This abnormal tracking adds stress on the meniscus, increasing the probability of lateral meniscus tears.<sup>46</sup> Unfortunately, discoid menisci often remain undetected when no symptoms present prior to injury, and the only other way to identify a discoid meniscus is by magnetic resonance imaging (MRI).

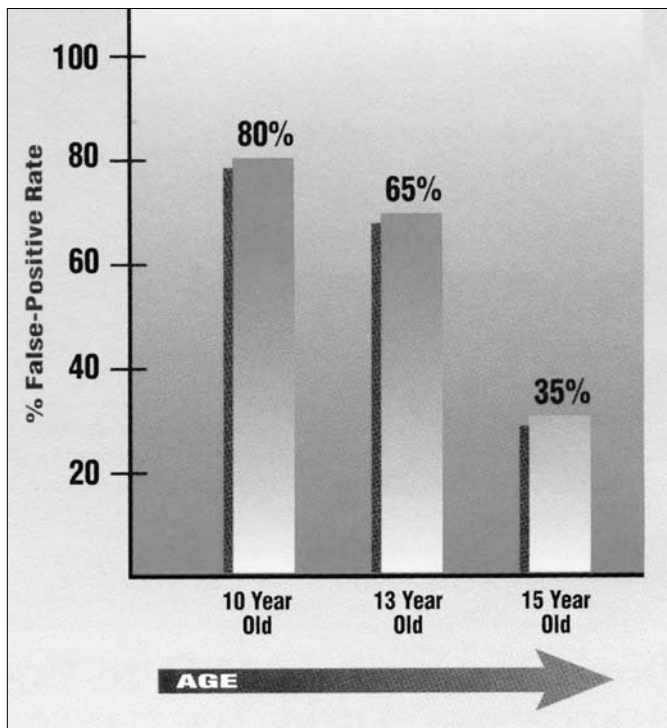
### IMAGING

For decades, MR imaging has been used as a primary determinant for meniscal injuries. MR imaging uses magnetic frequency to read radio waves given off by protons in the body; through these waves, the MRI is able to identify different tissues in the body and produce a semi-accurate picture of these tissues. The fact that MR imaging is more sensitive to some tissues than others, however, can prevent it from producing a completely accurate picture of an injured area. This can cause injured tissues to remain undetected, or other “abnormalities” on the MRI to be misread as actual injuries. These errors include shadows, truncation artifacts, and even foreign tissues, such as scar tissue, that can have the appearance of an injury on an MRI film. As a result, relying on MR imaging alone, especially as it relates to meniscal tears, will very often lead to an improper diagnosis and, subsequently, improper treatment.



**Figure 7. Discoid meniscus of right knee.**

One study that brought these issues into the spotlight was performed on college basketball players at Duke University who displayed no clinical symptoms of knee abnormality. Internal irregularities of the knee including cartilage defects, joint effusions, bone marrow edema, and even discoid menisci were found on the MRIs of 75% of subjects, who never displayed any symptoms of meniscal abnormality.<sup>47</sup> When an MRI shows a tear or meniscal degeneration when the person has no symptoms, this is called a false positive. The MRI is falsely positive. Kornick and associates investigated 64 volunteers, between the ages of 10 and 74, and found that over 25% had abnormal signals in their menisci, despite being totally asymptomatic.<sup>48</sup> More distressing is the fact that in another study on children, mean age 12.2 years, 66% showed a high signal intensity within the menisci.<sup>49</sup> A high signal intensity is one of the criterion to diagnose degenerative menisci. (See Figure 8.) Perhaps the best study to date to document abnormal meniscal MRI findings in asymptomatic individuals was published in the *New England Journal of Medicine* in 2008.<sup>50</sup> In this study, MRI



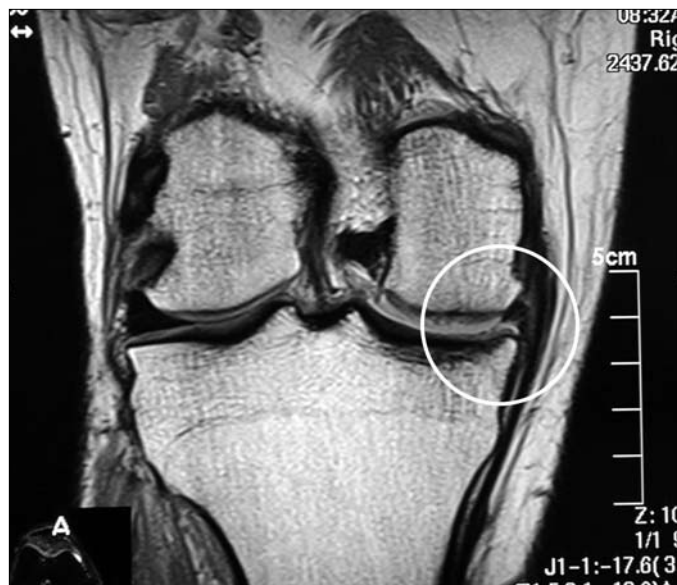**Figure 8. False-positive MRIs of the knee in teenagers.** Because significant abnormalities show up in the menisci on MRI in teenagers, when no true injury exists, relying on this modality to make a diagnosis is a scary proposition, especially if surgery is contemplated.

Used with permission of Beulah Land Press © 2001 Oak Park, IL. *Prolo Your Sports Injuries Away!*, fig. 16-10.

scans on 991 knees were taken and compared to clients responses about pain and disability in those knees. The prevalence of meniscal tear or of meniscal destruction in the knee as detected on MRI ranged from 19% among women 50 to 59 years of age to 56% among men 70 to 90 years of age. The MRIs in these patients ages 50 to 90 showed that over 60% had meniscal tears documented on MRI and that 61% of subjects who had meniscal tears did not have any pain, aching, or stiffness in their knees.

Not only do MRI findings often fail to correlate with the associated symptoms of meniscal injury, they are also frequently found to be inaccurate in correctly predicting meniscal pathology found on arthroscopy.<sup>51-54</sup> This was the case in a study in which clinical examination correctly identified 97% of medial meniscal tears and 85% of lateral meniscal tears found on arthroscopy, as opposed to MRI predictions, which were 10% less accurate in each category.<sup>55</sup> Gelb et al. found that, when compared to arthroscopic findings, clinical examination was 100% accurate in the diagnosis of ACL injuries, 91% accurate for meniscal tears, and 100% accurate for articular cartilage damage. MR imaging, on the other hand, was 95% sensitive for ACL injuries, 82% sensitive for meniscal tears, and only 33% accurate in predicting articular cartilage injuries.<sup>56</sup> Other published studies by Liodakis and his colleagues found similar results when studying the preoperative MRI scans of 2,000 arthroscopic meniscectomy patients. Their patients' MRI findings only correlated with the intraoperative arthroscopic findings a mean of 52% of the time.<sup>57</sup> One study published in the *Journal of Arthroscopic Surgery* reported that 35% of their patients would have undergone unnecessary surgery if the examiner had relied on just MRI findings of meniscal tear alone, leading the researchers to conclude that MRIs are "an expensive, unnecessary procedure."<sup>58</sup> (See Figure 9.)

Just as MRIs can lead to false-positive readings, they may also produce false-negative findings by failing to detect an actual meniscal injury. This was the case in one study of 254 human knees, where the researchers found that 13% of their patients presented with normal MRIs, despite exhibiting symptoms of meniscal injury confirmable on arthroscopy.<sup>59</sup> In studying the correlation between arthroscopy, clinical examination, and MR imaging, Stanitski found that 71% of his patients were given inaccurate MRI readings, with 24% showing false-positive evidence of meniscal tears, while actual ACL, meniscal, and cartilage injuries went undetected in half of the patients.<sup>60</sup>



Excerpt from radiologist's MRI report.

**FINDINGS:**

Post surgical changes are demonstrated in medial meniscus with smaller than expected size of body of medial meniscus. Altered signal intensity in body and posterior horn of medial meniscus extending to inferior articular surface demonstrates similar appearance to previous outside MR. This either represents residual changes from prior surgery and meniscal tear or recurrent tear persistent from prior exam.

**Figure 9. MRI of the right knee without contrast.** Noted are changes in the medial meniscus. See how even the radiologist cannot determine whether this represents a recurrent meniscal tear or is just post surgical changes.

Part of the reason there are so many “abnormalities” in the menisci in asymptomatic individuals is because structures that attach to the menisci can cause an increased signal, which produces the false appearance of a meniscal tear. This was demonstrated in a study in which 109 patients had both arthroscopy and MR imaging of the knee, and the two were correlated.<sup>61</sup> It was found that 42 people (39%) had a normal menisiofemoral ligament attaching onto the lateral meniscus that was appearing on the MR scan as a lateral meniscal tear (high-signal intensity). As seen by these and numerous other studies, MR imaging often disagrees with patients’ clinical symptoms or arthroscopic findings, making it a poor tool for diagnosis. At an average cost of \$2,500 per scan, MR imaging is an unnecessary expense, especially when incorrect results initiate unnecessary surgeries. It is clear from the knowledge that we have that MRIs are not helping solve the problem of knee pain but can be *part* of the problem.

## TREATMENTS

The traditional management of a torn meniscus most often involves some measure of surgical treatment, such as partial or total meniscectomy, meniscal repair, or meniscal transplant. There are an estimated 650,000 arthroscopic meniscal procedures and a total number of 850,000 meniscal surgeries performed in the United States every year.<sup>1-3</sup>

The most aggressive surgical treatment is meniscectomy, which involves either complete or partial removal of the meniscus depending on the horizontal extent of the tear. Guided by arthroscopy, the damaged portion of the meniscus is surgically debrided and removed. In either operation, a peripheral rim of the meniscus must be kept to preserve any form of normal function within the knee. The decision of whether to remove all or part of the meniscus is based on the severity of the tear, the restriction of activity caused by the tear, and the age of the tear. Total meniscectomy is generally performed on the most severe and avascular tears which cannot be otherwise repaired.<sup>62, 63</sup>

Short-term follow-up of meniscectomy has generated some positive results. For example, a meniscectomy can provide temporary pain relief in early stages following the operation, especially when an acute tear had caused excessive pain or popping preoperatively. Another immediate result may be a greater feeling of stability, if the tear had previously been a source of instability. On long-term follow-up, however, these initial improvements have rarely been shown to last.<sup>63-65</sup> Complete pain relief from meniscectomy is nearly unheard of after more than 10 years and, at that point, more complex issues including limited range of motion, radiographic degeneration, crepitation, and severe functional impairment have usually begun to surface. In many cases, a simple meniscus tear, if operated on, can become a career-ending injury.<sup>63-66</sup> In long-term follow-up studies, four to 14 years after a meniscectomy, nearly 50% of patients had to decrease or stop their typical sporting activities.<sup>63, 64</sup> This included the adolescents who underwent total meniscectomy. The X-ray progression of the degenerative change paralleled the reduction in activity. Some 17 years after follow-up after total meniscectomy, the incidence of degenerative arthritis as documented by X-ray was 300% more likely in the knee that had the meniscectomy versus the non-operated knee.<sup>64</sup>

Joint instability is a common result of meniscectomy, which is not surprising considering that the meniscus is a primary stabilizing component of the knee. One of the principle reasons for meniscal operation is to improve joint stability, yet meniscectomy often appears to have the opposite effect, eliciting even more instability, crepitation, and degeneration than the injury produced prior to operation. This is why reoperation rates after meniscectomy can be as high as 29% to improve the joint instability that the meniscectomy caused.<sup>65-67</sup> A knee joint becomes unstable when ligaments, cartilages, or bone structures are weakened and unable to carry out the level of function of a healthy knee. Such is the case when the meniscus is removed from the knee and unable to perform the usual weight-bearing and tracking functions, placing additional stress on the rest of the knee.<sup>68, 69</sup> Common physical symptoms of instability after meniscectomy are crepitation, such as cracking or popping, and locking in the joint. On radiographic examination, this postoperative deterioration of the joint is evidenced by narrowing of joint space and flattening of the tibiofemoral surfaces. Because the knee is a joint designed for rotational motion, the shape of the bone structures is a vital part of mobility, and when those rotational mechanisms are altered, proper motion is not possible, causing the crepitation in the joint. For example, one study following over 1,000 meniscectomy patients found that 10 to 20 years after the surgery, 27% had more crepitus in the knees which underwent meniscectomy than they had in the untreated knees.<sup>66</sup> In this same group of patients, degenerative changes ranging from flattened tibial and femoral bone surfaces to significant joint space narrowing were found in 62.5% of the patients with X-ray evaluation of their knees. These researchers concluded that there was a direct correlation between the degeneration of these tibiofemoral surfaces and complaints on clinical examination.<sup>65</sup> A similar study found that 10 years after undergoing meniscectomy, 65% of patients had radiographic evidence of joint space narrowing greater than 50%.<sup>69</sup>

The greatest risk of partial and total meniscectomy is in the development of long term degenerative osteoarthritis. Numerous studies have confirmed that a large percentage of the meniscectomy population experience joint osteoarthritis later in life.<sup>70-76</sup> One study found that 15 to 22 years after having a meniscectomy, the odds ratio of knee degenerative arthritis was 2.6 after medial meniscectomy and 5.3 after lateral meniscectomy, using the non-operated knee as the control.<sup>71</sup> In one study, 20

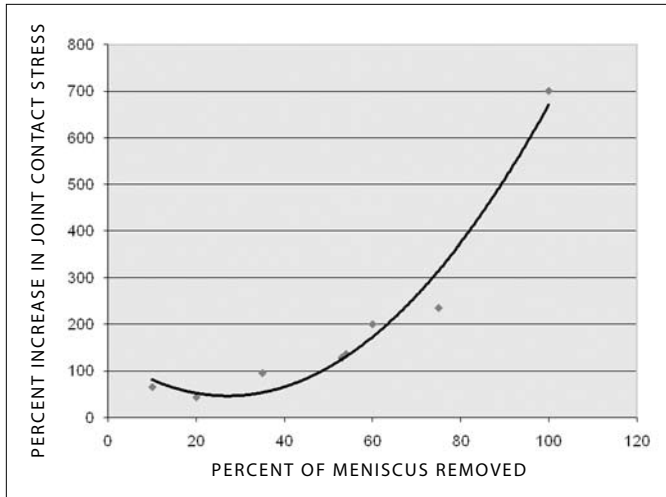
to 29 years after meniscectomy, X-rays showed 53% had significant progression of degenerative arthritis compared to 13% of the non-operated knees.<sup>72</sup> Another group of researchers found that 21 years after meniscectomy, 71% of operated knees showed signs of at least mild degeneration and 48% showed signs of moderate or severe joint degeneration.<sup>74</sup> Another study found that 40% of meniscectomies resulted in degenerative osteoarthritis, and many were accompanied by other injuries, including a large number of ligament tears.<sup>75</sup> One study noted, that “although risk factors for post-traumatic osteoarthritis are multifactorial, the primary risk factor that stood out in this study was if a meniscectomy had been performed.” In this study the risk of developing osteoarthritis in the knee after meniscectomy was 100%.<sup>76</sup>

**Joint instability** is a common result of meniscectomy.

Biomechanically, the development of osteoarthritis can be explained, in part, by the increased stress placed on the tibia and femur post meniscectomy. It is a known fact that reducing the size of contact area on a surface increases pressure in the remaining area. Therefore, by removing all or part of the meniscus from the knee, the area through which weight is transmitted in the joint is reduced, thus increasing the pressure on both the tibia and the femur, and their articular cartilage. The amount of contact stress on the tibiofemoral joint can increase by 65% with only a 10% reduction in contact area, and this percentage increases in proportion to the amount of meniscus removed. Complete removal of the meniscus can increase contact stress by as much as 700%.<sup>74-77</sup> (See Figure 10.) What this means for any knee without a meniscus is that it now bears the pressure proportional to carrying seven extra people on one knee.

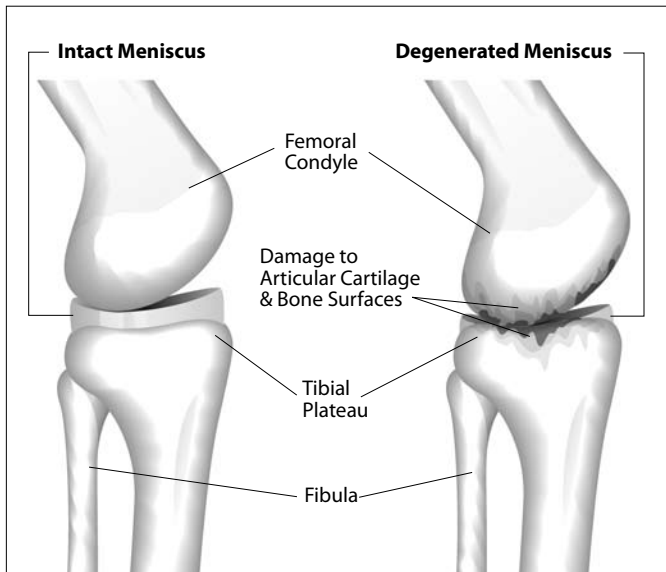
An additional aspect contributing to the acceleration of the osteoarthritic process is through structural wear of the articular cartilage. (See Figure 11.) By depriving the joint of the ability to lubricate the articular cartilage, the motion of the femur against the tibia will begin to break down the cartilage. When these articular cartilage cells, which are metabolically active, degenerate faster than they can regenerate, the result is the accelerated breakdown (degeneration) within the joint.<sup>76</sup> One study which followed rabbits in three-month intervals after varying levels of injury, found that the amount of cartilage damage sustained was greatest in the meniscectomy subjects, proving this treatment to be even more damaging than





**Figure 10. Increase in joint contact stress versus percent of meniscus removed.** As the percentage of meniscus removed during surgery increases, joint contact stress increases exponentially. Thus arthroscopic meniscectomy dramatically increases the incidence of future degenerative knee arthritis.

Source: 1. Baratz ME, et al. Meniscal tears: the effect of meniscectomy and of repair on intraarticular contact areas and stress in the human knee. A preliminary report. *Am J Sports Med.* 1986;14:270-275.  
 2. Lee SJ, et al. Tibiofemoral contact mechanics after serial medial meniscectomies in the human cadaveric knee. *Am J Sports Med.* 2006;34(8):1334-1344.



**Figure 11. Healthy knee joint with intact meniscus and degenerated knee joint without meniscus.** The removal of part or all of the meniscus during arthroscopic surgery accelerates the degeneration of the articular cartilage.

non-treatment.<sup>77</sup> Although osteoarthritis (OA) may have a reputation as a slowly developing disease only prevalent in the elderly, this is clearly not the case. Cartilage loss can develop from adolescent injuries and appear as early as a

few years after a meniscectomy.<sup>78-81</sup> Precursors to OA, such as evidence of biological cartilage alterations, can appear in as little as three months post meniscectomy.<sup>82,83</sup> Because OA develops steadily with time, this can have devastating effects by just five to 10 years after the procedure. The articular cartilage in a knee deteriorates at an average rate of 4.1% per year after meniscectomy.<sup>84</sup> This rate is about twice the rate of normal cartilage loss with aging.<sup>85</sup> After OA forms, the articular cartilage continues to deteriorate in the knee joint at a rate of about four to five percent per year.<sup>86,87</sup>

The results of total meniscectomy have led to a more cautious approach to meniscal excision, particularly with surgical techniques removing only the damaged portion of the meniscus.<sup>85-88</sup> The thought is that if a portion of the meniscus is preserved, then meniscal function will be more normal as well. Studies have confirmed that removing only the torn portion of a meniscus lowers the severity of postoperative complications, shortens the length of hospital recovery and therapy, and reduces overall pain levels, but the nature of postoperative complications remains the same. These risks include degenerative osteoarthritis, joint instability, femoral and tibial surface damage, and risk of re-injury requiring re-operation.<sup>87,88</sup>

Partial meniscectomy, like total meniscectomy, was found via MRI volume measurement to cause cartilage loss at a rate of 4.1% per year; a rate that is 78% faster than controls.<sup>89</sup> Other researchers noted when meniscal integrity is compromised, such as with partial meniscectomy, the likelihood of developing degenerative arthritis is large.<sup>90,91</sup> One of the main reasons for this, is that partial meniscectomy by definition puts additional strain on the ligamentous support of the knee to provide stability. Follow-up studies, show that ligament laxity in the medial and lateral collateral ligaments and anterior cruciate ligaments is increased with meniscectomies.<sup>92-94</sup> In regard to degenerative symptoms, one study reported that one year after undergoing an operation, 9% of partial meniscectomy patients experienced functional impairment, versus 28% of total meniscectomy patients. Almost seven years later, these numbers had increased to 62% in partial meniscectomy patients and 52% in total meniscectomy patients.<sup>95</sup> McGinity et al. documented in his study of post surgical function that “athletes who have undergone partial meniscectomy and total meniscectomy were equally likely to give up sports altogether as a direct result of the operation.”<sup>96</sup>

As the importance of maintaining complete intact menisci has become more widely recognized, the desire for a less invasive and more curative treatment has been sought out for meniscal injuries. For this reason, many have turned to meniscal repair as their treatment of choice. Meniscal repair utilizes one of several suturing techniques to reattach a torn flap of the meniscus, rather than removing it. In preparation for meniscal repair, the meniscus is generally debrided to remove any tissue that is rendered too loose or “contaminated” to heal, and then the procedure is performed either open or through incision under arthroscopy.<sup>97</sup> Meniscal repair is generally reserved for peripheral tears that extend into the red zone, because the likelihood of healing is greater in that region.<sup>97, 98</sup>

The short-term results of meniscal repair have varied significantly, with a range of both promising and disappointing outcomes.<sup>99, 100</sup> As the ability to track long-term results has become possible, repair failures and associated symptoms have been observed in large numbers, proving the effectiveness of this treatment to be questionable at best. Preoperative symptoms have been shown to resurface as early as six months following meniscal repair, and can lead to long-term joint damage prevalent decades later.<sup>101, 102</sup> Specifically, as documented by CT arthrogram, completely healing from meniscal repair was found in only 58% of the menisci.<sup>101</sup> After a 13 year follow-up the failure rate in one Swedish study was 29%.<sup>102</sup> In this same study, knee function showed a statistically significant decline in the meniscal-repaired knee compared to the non-operated knee. The authors noted, “We conclude that 13 years after repair, knee function is good but not better than after meniscectomy and not as good as in an uninjured knee.”

A failed meniscal repair is generally defined as lack of improvement after operation or, more specifically, any re-injury and subsequent re-operation. Re-injury after meniscal repair is not uncommon, affecting the original site of injury as well as new areas of the meniscus. Six independently performed studies, conducted an average of eight years after a repair, found that 10% to 38% of all meniscal repairs were considered failures.<sup>103-108</sup> The 38% failure rate was in patients under the age of 18. It is also worth noting that these injuries were not isolated, but in many cases occurred in addition to the return of multiple preoperative symptoms, such as joint pain, instability, weakness, and swelling. In summary, it can be concluded that about 25% of all meniscal repairs are failures.

In more practical terms, for 25% of all patients undergoing meniscal repair, the surgery will either not relieve their symptoms or the repair will fail and their symptoms will again return and need another operation or some other form of therapy. For instance, in one study, meniscectomy was needed in 10% of the patients after meniscal repair.<sup>109</sup> Considering the average follow-up for these groups of studies was eight years, imagine what the failure rate of meniscal repairs would be at 16 or 24 years!

Another concern associated with meniscal repair is, not surprisingly, long-term degenerative osteoarthritis.<sup>109-112</sup> This makes sense since a great percentage of meniscal repairs do not heal completely. One study found that only 30% of patients after meniscal repair showed no signs of osteoarthritis, whereas 83% of patients exhibited no signs of osteoarthritis before the treatment.<sup>109</sup> Although meniscal repair is most frequently performed in regions of greater vascularity, the treatment does not actually stimulate meniscal healing through vascular supply.<sup>110</sup> There was a 12% re-injury rate after meniscal repair in this study.

The most recent contribution to surgical treatment of meniscus injuries has been the advent of the meniscal transplant. Transplantation can be performed either with human allograft or artificial collagen implants, with the majority utilizing deep-frozen cryopreserved allografts extracted from human cadaver knees. Before a transplant can be conducted, the patient must undergo arthroscopic removal of any remaining meniscal tissue to prepare for the new implant. Using one of two techniques, a bone plug or a bridge, the implant is then placed inside the knee in alignment with the femur and tibia, and then sutured into place. This procedure requires careful measurement of the meniscus and precision in matching the size and placement of a new meniscus, as even the slightest error in measurement could cause improper tracking and damage to the knee.<sup>113</sup>

This method has been monitored closely for short-term results, but because it is a relatively new treatment and methods between studies have varied, long-term results are difficult to assess. Based on what information we do have, however, hope for long-term relief remains questionable. In a number of studies spanning from two to seven years after allograft transplantation, failure rates ranged from 28% to 58%, where symptoms such as allograft deterioration, new tears, and unresolved pain

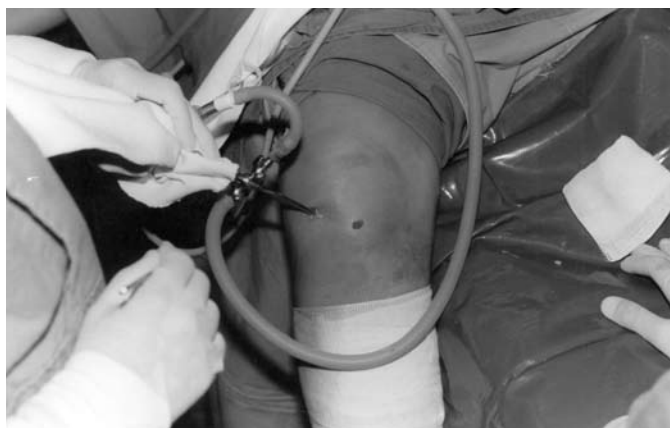
symptoms resulted in premature removal of allografts or additional arthroscopic surgeries.<sup>113-115</sup> As one study states, “[patients] should be advised that the procedure is not curative in the long term, and additional surgery will most likely be required.”<sup>113</sup> (See *Figure 12*.) Recovery time is another important issue in assessing any treatment, and transplants have a longer rehabilitation time than other meniscal operations. In documented transplantation cases, patients did not begin physical rehabilitation until eight weeks post operation, at which time they were started on non-strenuous activities such as cycling, followed by swimming and walking, between nine and 12 weeks post operation. Even in the most successful knees, patients were informed that they should never return to arduous physical activity, including athletics.<sup>114</sup> Meniscal transplantation with such a high failure rate, diminishes the hope that anyone, especially athletes, would have for maintaining an active lifestyle.

Although there is some short term improvement in aspects such as pain control, the long term effects of meniscectomy, meniscal repair, and meniscal allograft transplantation reveal that symptoms, such as pain and instability, will persist for years afterward. The main reason that these and other treatments are ineffective in healing the meniscus can simply be attributed to the fact that, regardless of what is done to structurally repair the meniscus, it is still primarily an avascular cartilaginous structure which cannot heal without a sufficient supply of nutrition. The poor healing potential of meniscal tears has led to the investigation of methods to provide blood supply to the injured area. The methods include vascular access channels and synovial pedicle flaps. Unfortunately,

no surgical treatment to date has been shown to stimulate healing of the meniscus. On the contrary, surgeries often have the opposite effect. They initiate additional damage to the joint, further decreasing the probability of healing. Current surgical techniques for meniscal injuries accelerate menisci and joint degeneration. Perhaps Lohmander et al. in their comprehensive review of surgical procedures for meniscal pathology said it best, “there is a lack of evidence to support a protective role of repair or reconstructive surgery of the anterior cruciate ligament or meniscus against osteoarthritis development...Osteoarthritis developed in the injured joints is caused by intraarticular pathogenic processes initiated at the time of injury, combined with long-term changes in dynamic joint loading.”<sup>116</sup> The bottom line is surgical procedures do not initiate the regenerative process needed in these traumatized knee joints. Left alone or treated by the surgery, the degenerative process initiated by the initial trauma continues, unless something is done to initiate regeneration. The reverse of degeneration is simply regeneration. In other words, a degenerative process can only be reversed when stimulated to repair itself. Degeneration of the meniscus is initiated by a damaged meniscus’ inability to repair itself, and the surgical procedures themselves accelerate the degenerative process. The ideal treatment for the damaged meniscus is one that can stimulate regeneration of the degenerated or torn meniscus. The injection technique whereby the proliferation of cells is stimulated via growth factor production is called Prolotherapy. (See *Figure 13*.)

#### PROLOTHERAPY FOR MENISCAL PATHOLOGY

In order to understand how growth factors affect the treatment of meniscus injuries, it is first important to understand the role that they play in the natural process of healing. The preliminary steps of healing begin with the attraction of blood cells to the site of an injured tissue. When a tissue is injured, bleeding will naturally occur in that area. A specialized type of blood cell called platelets, rush to the area to cause coagulation, or the clotting of blood cells, to prevent excessive bleeding from an injury. In addition, platelets also release growth factors which are an integral part of the healing process. Each platelet is made up of an alpha granule and a dense granule which contain a number of proteins and growth factors; the growth factors contained in the alpha-granule are an especially important component to healing. When activated by an injury, the platelets will change shape and develop branches to spread over injured tissue to



**Figure 12. Arthroscopy of the knee.** Arthroscopy of the knee for meniscal injury is often non-curative and can lead to long term problems, including degenerative arthritis.

**Figure 13. Effects of treatments for meniscal tears.** Only Prolotherapy stimulates the repair of injured meniscal tissue.

Effects of treatment	Meniscal removal	Meniscal repair	Meniscal transplant	Untreated injury	Prolotherapy
Articular cartilage deterioration	YES	YES	YES	YES	NO
Bone deformity	YES	YES	YES	YES	NO
Chronic pain	YES	YES	YES	YES	NO
Continuing instability	YES	YES	YES	YES	NO
Joint space narrowing on MRI	YES	YES	YES	YES	NO
Likely to be re-injured	YES	YES	YES	YES	NO
Long term osteoarthritis	YES	YES	YES	YES	NO
Restricted motion	YES	YES	YES	YES	NO
Weakened ligaments	YES	YES	YES	YES	NO
Stimulates meniscus repair	NO	NO	NO	NO	YES

person reaches the age of 40 years, meniscal healing is generally incomplete.<sup>117</sup> Once torn, the menisci, because of its low cellularity and incomplete healing response, is unable to fully repair itself.<sup>118, 119</sup> In one study, upon a five-year follow up after meniscal allograft transplantation, transplanted menisci were found to have decreased growth factor production indicating decreased biological function. Furthermore, the transplanted menisci were repopulated with fewer cells than even an untreated

help stop the bleeding in a process called aggregation, and then release growth factors, primarily from the alpha granules.

At this point, the healing process then proceeds in three simple stages: inflammatory, fibroblastic, and maturation. After growth factors are released from the platelets, they stimulate the inflammatory stage, each growth factor playing a key role. (See Figure 14.) This stage is marked by the appearance of monocytes which are white blood cells that respond quickly to inflammatory signals and elicit an immune response. Growth factor production is at its highest level immediately following the inflammatory stage. Fibroblasts begin to enter the site within the first 48 hours after an injury and become the most abundant cells in that area by the seventh day. The fibroblasts deposit collagen, the main material of tissues such as the meniscus, for up to many weeks afterward. The maturation of collagen may then continue for up to one to two years after the initial inflammatory event.

It is important to understand that each of these stages stimulates the next. If the inflammatory stage does not occur, neither will the fibroblastic stage, and so on. *If there is not a significant enough immune response to completely regenerate the damaged tissue in any of these stages, the injury will be unable to heal completely, leaving the person with a chronic degenerated knee.*

In the case of the injured meniscus, it is clear that the damaged tissue can not repair itself. Healing in the meniscus depends on the having enough of a blood supply and/or growth factors at the site of the injury. Since less than 20% of the meniscus is vascularized by the time a

torn meniscus.<sup>120, 121</sup> It has also been shown that the number of cells in the meniscus decreases with age.<sup>122</sup>

IN VIVO AND IN VITRO STUDIES ON GROWTH FACTORS IN STIMULATING MENISCAL REPAIR

Because growth factors are known to be a basic component of healing, the adjunct use of growth factors to stimulate connective tissue repair has been studied as a potential for the treatment of injured soft tissues, including the meniscus. Direct exposure of connective tissues to fibroblastic growth factors can indeed cause new cell growth and formation of collagen. Therefore, injecting growth factors at the site of a soft tissue injury allows the damaged tissue to heal itself.

Before any treatment is tested on humans, it is common practice to investigate the effect of that treatment, in this case growth factors, on cells (see side bar), as well as on animal models with similar pathology to humans. The

**Figure 14. Various growth factors found in platelets and their actions.**

Platelet-Derived Growth Factor (PDGF)	Attracts immune system cells to the area and stimulates them to proliferate. Has been shown to enhance ligament and tendon healing.
Transforming Growth Factor-β (TGF-β)	Secreted by and affects all major cell types involved in healing. Similar affects as PDGF.
Vascular Endothelial Growth Factor (VEGF)	Helps new blood vessel formation, thereby increasing vascularity in injured areas.
Fibroblast Growth Factor (FGF)	Promotes the growth of the cells involved in collagen and cartilage formation.

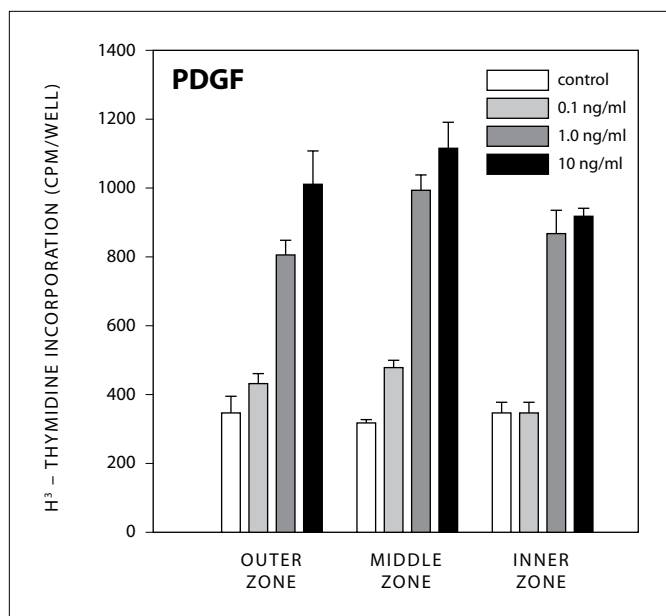
primary objective of these studies is to determine if and how a poorly vascularized tissue, such as the meniscus, can be stimulated for reliable cellular and tissue repair. In such studies, growth factors, such as the ones extracted and secreted from the platelets

**in vivo** - experimentation done on live isolated cells.

**in vitro** - experimentation done in an artificial environment outside the living organism.

are incubated with meniscal cells and then injected into injured meniscal tissue to see if cellular repair and regeneration occurs. Many studies demonstrate that injection of various growth factors can increase meniscal cell activity and stimulate repair, in this tissue and other connective tissues.<sup>123-140</sup> As with other tissues that have a poor blood supply, like cartilage, meniscal cells are sparse. They are best categorized as fibrochondrocytes, as they have cellular characteristics of chondrocytes, cartilage cells, and fibroblasts that synthesize connective tissues such as ligaments.<sup>141</sup> The meniscal cells are responsible for maintaining the extracellular matrix. The ideal mode of treatment for meniscal tears and degeneration would stimulate the production of meniscal fibrochondrocytes and its synthesis of extracellular matrix (ECM). Increased ECM synthesis would render the generated meniscal tissue more able to withstand the forces placed on the knee. For it is the collagen, proteoglycans and glycoproteins in the ECM which give the meniscus its compressive properties to withstand tensile loads.<sup>142</sup>

Platelet-derived growth factor (PDGF) is one growth factor commonly used in animal meniscus studies. One recent study measured both cell proliferation and extracellular collagen matrix formation in each of the inner, middle, and outer regions of sheep menisci, in the presence of PDGF-AB. After one week, meniscal cell proliferation was apparent in all three meniscal zones, reaching an 800% increase in the inner vascular zone compared to control. The formation of the collagen matrix had increased by 450% in the middle zone and by 300% in the outer zone. (See Figure 15.) An increase in the production of glycosaminoglycans, a main component of synovial fluid, in each of the three zones was observed.<sup>132</sup> Meniscal cell migration was also stimulated. A similar in vitro study found that cell production of sheep menisci increased with proportion to the increased concentration of PDGF-AB used. This study observed a 2.5-fold increase in cell production.<sup>133</sup> Another in vitro study placed bovine meniscal cells in different solutions containing cytokines and measured the effect of each on the synthesis of new



**Figure 15. Effect of platelet-derived growth factor-AB on DNA synthesis in cells from the three zones of the meniscus.** Results are mean + SEM (N = 12). Platelet-derived growth factor at 1 and 10 ng/ml increased DNA synthesis (in both the middle and inner zones) by over 400% compared with control.

Source: Bhargava MM, et al. The effect of cytokines on the proliferation and migration of bovine meniscal cells. *Am J Sports Med.* 1999;27:636-643.

cells in each of the three meniscal zones. The authors reported that significant DNA synthesis occurred in meniscal cells treated with PDGF-AB, hepatocyte growth factor, and bone morphogenetic protein-2, in all three regions.<sup>134</sup> Similar results were found when analyzing the effect of basic fibroblastic growth factor (bFGF) on meniscal cells from sheep. When cultured in the bFGF, the formation of DNA increased by as much as seven-fold, and protein synthesis increased by as much as 15-fold in the inner (avascular) zone of the meniscus. The results of the outer and middle zones likewise yielded statistically significant cell growth.<sup>135, 138</sup> The synthesis of proteoglycans, the principle component of the extracellular collagen matrix, was specifically measured in another study on sheep menisci. In all meniscal zones, transforming growth factor beta (TGF- $\beta$ ) stimulated proteoglycan production by up to 100% and the proteoglycans were larger than controls. TGF- $\beta$  also stimulated cell division in the fibrochondrocyte cultures.<sup>137</sup> Other authors have also confirmed that meniscal fibrochondrocytes from all three zones, including the avascular zone, can proliferate and generate new extracellular matrix given the proper stimuli.<sup>128, 129, 139, 140</sup> Such findings have been the basis of the integration of growth factors in the treatment of meniscal pathology.

One study involved the use of growth factors TGF- $\beta$ 1 and insulin-like growth factor (IGF-1) as an aid in the insertion of meniscal plugs into the avascular portion of the meniscus. This study found that TGF- $\beta$ 1 was effective in forming an attachment between the actual meniscus and the plugs, and IGF-1 was effective in cell proliferation. Both growth factors also significantly increased the cell density of the plugs.<sup>127</sup> Canine menisci with a defect in the avascular portion documented a 10-fold increase in healing by the addition of a fibrin sealant and endothelial cell growth factor.<sup>137</sup> In this study, the ingrowth of new blood vessels (neovascularization) and granulation tissue (connective tissue) to the avascular portion of the meniscus was noted. Growth factors have even been introduced into surgical treatments, particularly meniscal transplantation, to preserve and enhance joint tissue.<sup>143, 144</sup>

The evidence that avascular cells are capable of regeneration, when properly stimulated to do so, serves as the basis and rationale for Prolotherapy in the treatment of meniscal pathology.

#### PROLOTHERAPY STIMULATES GROWTH FACTOR FORMATION

The primary objective of Prolotherapy injections is to initiate or recreate the inflammatory stage of the healing process. It does so by raising the levels of growth factors to resume or initiate a repair sequence that has prematurely aborted or never started.<sup>145</sup> Cells in the area of exposure, such as fibroblasts, chondrocytes and fibrochondrocytes, can also be expected to respond if the growth factors are those that proliferate such cells.<sup>146</sup> By triggering this cascade of anabolic events, Prolotherapy stimulates the new growth of cells and is indirectly responsible for rebuilding depleted tissues.

Typical Prolotherapy solutions use a hypertonic solution of dextrose (glucose) as its base. Studies have shown that even a brief exposure to small amounts of glucose molecules causes an elevation in growth factors such as IGF-1, TGF- $\beta$ , TFG- $\beta$ , bFGF, and PDGF-B.<sup>145-150</sup> Another substance used in Prolotherapy, especially for degenerative knee conditions, is human growth hormone (HGH).<sup>151</sup> HGH stimulates the production of IGF-1 in the liver, but it can also have an important role in the localized treatment of degenerate cartilage cells. Circulating and locally produced IGF-1 can stimulate DNA synthesis, cell replication, and proteoglycan and glycosaminoglycan synthesis in articular chondrocytes.<sup>152</sup> Additional studies

show that HGH and IGF-1 have both been shown to cause growth and repair of articular cartilage cells.<sup>153-155</sup> One reason for this cartilage growth can be that cartilage cells have HGH receptors.<sup>156</sup> Anecdotal radiographic evidence of the regeneration of articular cartilage has been seen with and without the use of HGH with Prolotherapy to the knee.<sup>157, 158</sup> Other published studies have documented symptomatic improvement in patients with degenerative knee arthritis with Prolotherapy.<sup>159-161</sup>

Another emerging technique in the field of Prolotherapy is Platelet Rich Plasma Prolotherapy (PRPP), which utilizes the injection of human autologous blood components to facilitate healing of degenerative tissue injuries. In this technique a small amount of whole blood is drawn and is separated into platelet poor plasma and platelet rich plasma. The latter is used in PRPP and consists of plasma, which is the liquid component of blood, containing a high concentration of platelets. Because platelets are the storehouses of growth factors, platelet rich plasma is abundant in growth factors. PRPP though not only provides a higher concentration of growth factors to the tissue than is provided by normal blood supply, it stimulates the injured tissues to increase their own innate growth factor production.<sup>162-164</sup> PRPP has shown in one controlled study to give statistically significantly better results for knee osteoarthritis than hyaluronan injection.<sup>165</sup>

In actual clinical practice, there are a host of solutions available to the doctor performing Prolotherapy. Although there have been no studies to date directly addressing the use of Prolotherapy for meniscal injuries, Prolotherapy has a long history of treating degenerative knee conditions including meniscal pathology.<sup>166-169</sup> For seventeen years the primary author (R.H.) has treated meniscal pathology successfully with Prolotherapy. This retrospective study was done to document the degree of improvement in meniscal tears and degeneration with Prolotherapy.

#### PATIENTS AND METHODS

All patients were treated at the primary author's private practice, Caring Medical and Rehabilitation Services in Oak Park, Illinois. A premedical student (H.M.) reviewed in-house medical charts of patients who had completed their last Prolotherapy treatment at least one year ago and had MRI documented meniscal pathology. This criterion was chosen to give adequate time to determine if the positive effects of the Prolotherapy treatments



continued once they were finished. H.M. completed phone interviews asking the patients a series of questions with an emphasis on the effect Prolotherapy had on their knee pain, stiffness, and quality of life.

All patients received the Hackett-Hemwall technique of dextrose Prolotherapy to the knee. This included a 15% dextrose, 10% Sarapin and 0.2% lidocaine solution as the base solution. Each patient was given an intraarticular injection of 5-10cc of solution. Twenty-four of 28 knees received 2IU of human growth hormone added to this base solution. Two patients received 3.5cc of Platelet Rich Plasma Prolotherapy (PRPP) injected inside the joint. One patient received only base solution and one patient received manganese as an additive. Injections were also given along the tender points about the knee, including the medial collateral ligament. Patients typically received a total of 30-40cc of solution per treatment visit. Patients were seen every four to six weeks. (See Figure 16.)

All data was analyzed by an independent computer consultant (D.G.), who had no previous knowledge of Prolotherapy. A matched sample paired t-test was used to determine statistically significant improvements in the before and after Prolotherapy measurements for pain and stiffness.

PATIENT CHARACTERISTICS

Data was tabulated on 28 knees in 24 patients. Of the 24 patients, 71% (17) were male and 29% (7) were female with an average age of 45 years. Eighteen knees had MRI

documented meniscal tears of which eight were acute and ten were chronic (over six months since the tear). The medial meniscus was torn in sixteen of the knees and the lateral meniscus in two. According to the radiographic reports, four of the tears were complex, three were vertical, three were horizontal, two were bucket handle, and one was complete. The other five were nondescript meniscal tears. Arthroscopy had been previously performed on ten of the knees. Ten of the knees had MRI documented meniscal degeneration without tears. (See Table 1.)

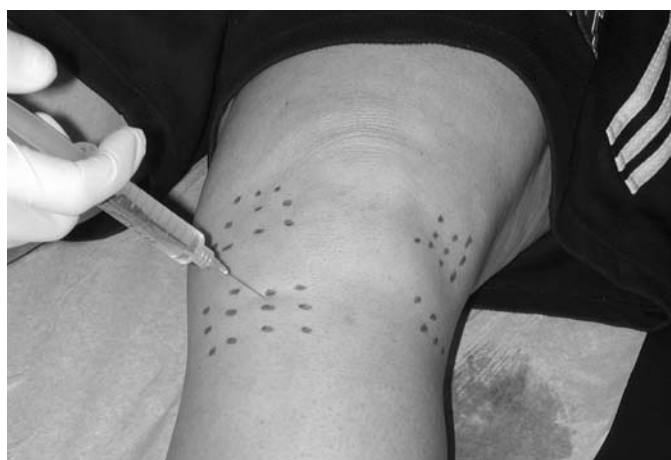**Table 1. Patient characteristics prior to Prolotherapy.**

Injured knees	n=28
Percentage of male patients	71%
Percentage of female patients	29%
Average age of patients	45
Left knees treated	14
Right knees treated	14
Knees with MRI documented meniscal tears	18
Number of complex tears	4
Number of vertical tears	3
Number of horizontal tears	3
Number of bucket handle tears	2
Number of complete tears	1
Number of non-descript tears	5
Arthroscopy previously performed	10
MRI documented meniscal degeneration	10

TREATMENT OUTCOMES

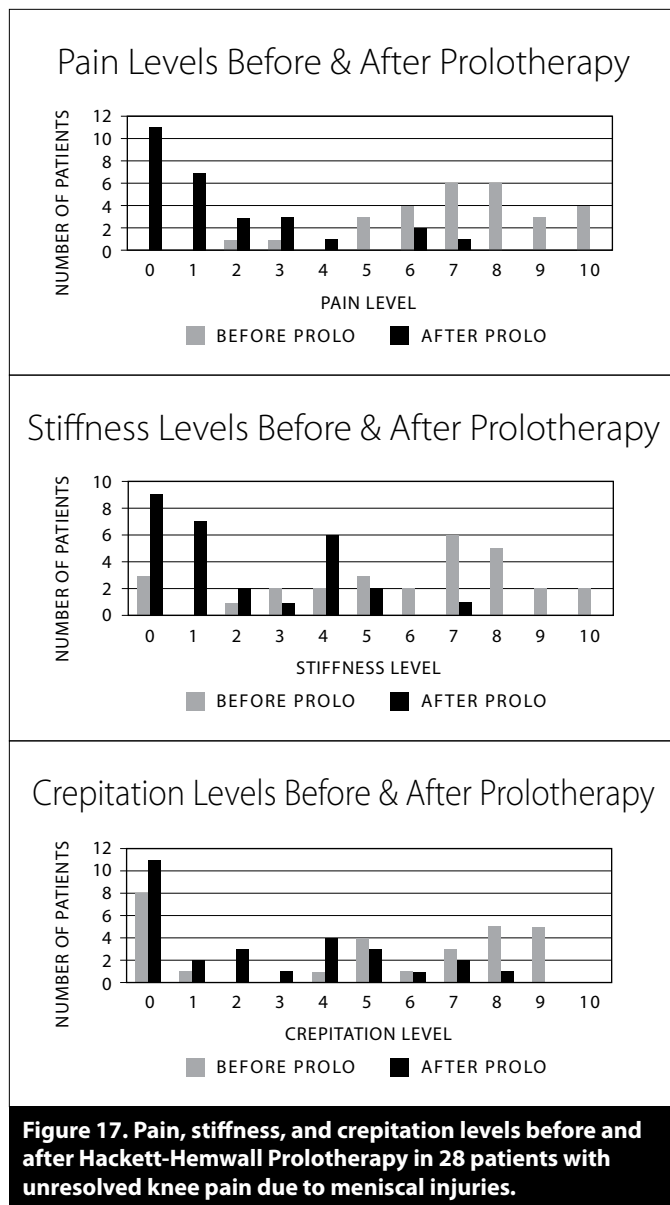
Patients received an average of 6.2 Prolotherapy treatments per knee. The average time since their last Prolotherapy treatment was 18.6 months.

Patients were asked to rate their knee pain, stiffness, and crepitation (crunching sensation) levels on a scale of 0 (none) to 10 (severe crippling). For the 28 knees the average starting pain level was 7.2, stiffness 5.8, and crepitation 4.9 which improved to levels of 1.6, 2.0, and 2.5 respectively, after Prolotherapy. (See Figure 17.) Before Prolotherapy, 17 patients were taking one or more pain medications, but after Prolotherapy only three were taking one pain medication.



**Figure 16. Typical injection sites for Hackett-Hemwall dextrose Prolotherapy of the knee.**

Source: Hauser R, et al. A retrospective study on dextrose Prolotherapy for unresolved knee pain. *Journal of Prolotherapy*. 2009;1:11-21.



Patients were also asked to rank their knee range of motion with 0 being normal motion and 10 representing no motion. The average range of motion improved from a level of 4.1 to 1.1 after Prolotherapy. Only 25.9% of the patients had normal motion (0 or 1) before Prolotherapy, but after Prolotherapy this increased to 75%. Before Prolotherapy only four (14.3%) patients had normal walking ability (0% compromised), but this increased to 20 (71.4%) after Prolotherapy. (See Figure 18.) In regard to exercise ability, before Prolotherapy 14.2% of patients could exercise greater than 60 minutes, but after Prolotherapy this increased to 85.7%. (See Figure 19.)

In regard to the question “*Did the improvements with Prolotherapy last?*” 96.4% of the patients stated they still have lasting pain relief in their knees as a result of the Prolotherapy. Eighty-six percent reported lasting improvement in stiffness, while 100% of the patients noted their improvement in walking ability continues to this day.

To the question “*Did Prolotherapy meet your expectations?*” 96.4% (27 out of 28) of the patients treated answered “yes.” In regard to the question “*Did you end up getting surgery on your knee?*” only one patient answered “yes.”

STATISTICAL ANALYSIS

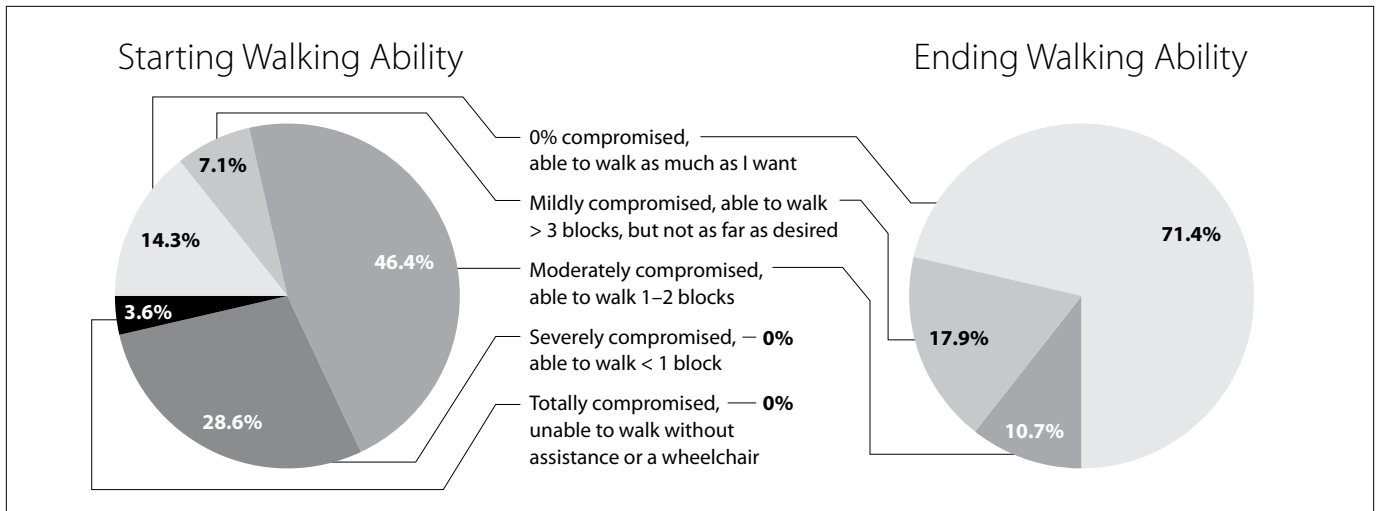
A matched sample paired t-test was used to calculate the difference in responses between the before and after measures for pain and stiffness for the 24 patients (representing 28 knees). Using the paired t-test, the p values for pain and stiffness for the two groups reached statistical significance to the p<.000001 level.

DISCUSSION: PRINCIPLE FINDINGS

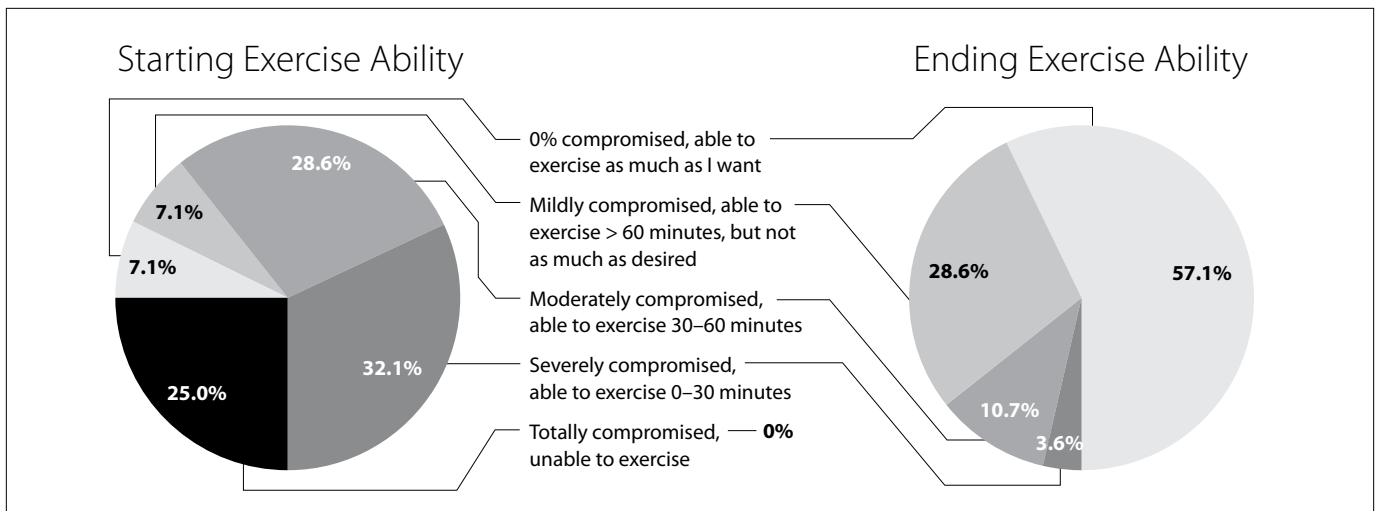
The results of this pilot, retrospective, uncontrolled study show that Prolotherapy helps decrease pain and stiffness and improve the quality of life in patients with meniscal tears and degeneration. This includes tears in all three meniscal zones, as well complete and complex meniscal tears. The Hackett-Hemwall dextrose Prolotherapy, including those with human growth hormone or platelet rich plasma added to the intraarticular injection, improved pain and stiffness to a statistically significant level. From the patient’s point of view there were noticeable improvements in crepitation and range of motion of their knees. Ninety-six percent (27 out of 28 knees) improved to the point that the patients felt that Prolotherapy met their expectations and no surgery for meniscal pathology was needed. Major improvements in other quality of life issues, including walking ability, exercise ability, and decreased medication usage was also reported with Prolotherapy.

One patient underwent a total knee replacement in February 2010. In reviewing this patient’s chart, his initial MRI revealed “a degenerative tear involving the anterior horn and body of the lateral meniscus which extends in a longitudinal fashion to the apex and superior surface.” The patient’s dates of Prolotherapy treatment were 10/18/06, 2/5/07, 3/19/07 and 7/26/07. At the





**Figure 18. Walking ability before and after Hackett-Hemwall Prolotherapy in 28 patients with unresolved knee pain due to meniscal injuries.**



**Figure 19. Exercise ability before and after Hackett-Hemwall Prolotherapy in 28 patients with unresolved knee pain due to meniscal injuries.**

third visit he said his overall improvement was 70% and at his last visit his overall improvement was 80%. He was not seen after 7/26/07. While this patient ended up needing a total knee replacement in February 2010, our review found that the patient did not comply with the recommended Prolotherapy treatment course, to be received every four to six weeks until his pain resolved or he was satisfied with the improvements. It is not known why this patient did not continue to follow-up and receive more Prolotherapy after the July 2007 visit, if his pain returned, as reported.

While this study cannot be compared to a clinical trial in which an intervention is investigated under controlled

conditions, clearly the findings are extremely positive. The level of improvement with pain and stiffness met a highly statistically significant level and more importantly the Prolotherapy met the expectations of the patient in 27 of 28 knees to the point that surgery was not required. The marked decrease in pain and stiffness was accompanied by similar improvements in walking and exercise ability, suggestive that the Prolotherapy was indeed repairing the meniscus tear. Another plausible explanation for the extremely high success rate of this study is that the treatment given was Hackett-Hemwall Prolotherapy. In this type of Prolotherapy, not only are the meniscal injuries treated, but also any joint instability, ligament weakness or tear, as well as any tendinopathy.

In regard to the patients with degeneration of the menisci, Prolotherapy strengthened the menisci to the point that they could function properly under load. As previously mentioned, various types of tears were treated and showed improvement with Prolotherapy, including the tears of the white zone (with little or no blood supply). One reason to do this study was to determine if a certain type of meniscal tear did not respond to Prolotherapy. But in this pilot study, all type of tears (including vertical, horizontal, complex and oblique) and locations (lateral, medial, posterior, and anterior) responded. In the future, MRI documentation of meniscal repair with Prolotherapy would confirm these conclusions.

## CONCLUSIONS

The Hackett-Hemwall technique of dextrose Prolotherapy used on patients with MRI documented meniscal pathology including tears and degeneration, interviewed an average of 18 months after their last Prolotherapy treatment, was shown in this retrospective pilot study to improve patients' quality of life. Most patients reported statistically significantly less pain and stiffness and major improvements in range of motion, crepitation of the knee, medication usage, walking ability, and exercise ability. The improvements with Prolotherapy met the expectations of the patients in over 96% of the knees to the point where surgery was not needed. Prolotherapy improved knee pain and function regardless of the type or location of the meniscal tear or degeneration. The improvements were so overwhelmingly positive that Hackett-Hemwall Prolotherapy should be considered as a first-line treatment for pain and disability caused by meniscal tears and degeneration. If these results are confirmed by further studies under more controlled circumstances, with larger patient populations, and with MRI confirmation, surely Hackett-Hemwall Prolotherapy *will* become a first-line treatment for meniscal tears and degeneration. ■

## BIBLIOGRAPHY

- Baker BE, et al. Review of meniscal injury and associated sports. *Am J Sports Med.* 1985;13(1):1-4.
- DeFrances CJ, et al. 2006 National Hospital Discharge Survey. National Center for Health Statistics. National Health Statistics Reports No. 5. 2008.
- Owings MF, et al. Ambulatory and inpatient procedures in the United States, 1996. Vital and health statistics. Series 13. No 139. Hyattsville, Md.: National Center for Health Statistics, November 1998. (DHHS publication no (PHS) 99-1710.)
- Powell JW, et al. Injury patterns in selected high school sports: a review of the 1995-1997 Seasons. *Journal of Athletic Training.* 1999;34(3):277-284.
- Dick R, et al. Descriptive epidemiology of collegiate men's basketball injuries: National Collegiate Athletic Association Injury Surveillance System, 1988-1989 through 2003-2004. *Journal of Athletic Training.* 2007;42(2):194-201.
- Agel J, et al. Descriptive epidemiology of collegiate women's basketball injuries: National Collegiate Athletic Association Injury Surveillance System, 1988-1989 through 2003-2004. *Journal of Athletic Training.* 2007;42(2):202-210.
- Agel J, et al. Descriptive epidemiology of collegiate men's soccer injuries: National Collegiate Athletic Association Injury Surveillance System, 1988-1989 through 2002-2003. *Journal of Athletic Training.* 2007;42(2):270-277.
- Dick R, et al. Descriptive epidemiology of collegiate women's soccer injuries: National Collegiate Athletic Association Injury Surveillance System, 1988-1989 through 2002-2003. *Journal of Athletic Training.* 2007;42(2):278-85.
- Bradley J, et al. Incidence and variance of knee injuries in elite college football players. *American Journal of Orthopaedics.* 2008;37(6):310-314.
- Adirim TA, et al. Overview of injuries in the young athlete. *Sports Medicine.* 2003;33(1):75-81.
- Luhmann SJ. Acute traumatic knee effusions in children and adolescents. *Journal of Pediatric Orthopaedics.* 2003;23(2):199-202.
- Arendt EA, et al. Anterior cruciate ligament injury patterns among collegiate men and women. *Journal of Athletic Training.* 1999;34(2):86-92.
- Hope PG. Arthroscopy in children. *Journal of the Royal Society of Medicine.* 1991;84:29-31.
- Clark CR, et al. Development of the menisci of the human knee joint; morphological changes and their potential role in childhood meniscal injury. *Journal of Bone and Joint Surgery America.* 1983;65(4):538-547.
- Majewski M, et al. Epidemiology of athletic knee injuries: a 10-year study. *The Knee Journal.* 2006;13(3):184-188.
- Hede A, et al. Epidemiology of meniscal lesions in the knee: 1,215 open operations in Copenhagen 1982-84. *Acta Orthop Scand.* 1990;61(5):435-437.
- Noble J. Lesions of the menisci: autopsy incidence in adults less than fifty-five years old. *Journal of Bone and Joint Surgery.* 1977;59-A(4):480-483.
- Starkey C. Injuries and illnesses in the National Basketball Association: a 10-year perspective. *Journal of Athletic Training.* 2000;35(2):161-167.
- Hootman J, et al. Epidemiology of collegiate injuries for 15 sports: summary and recommendations for injury prevention and initiatives. *Journal of Athletic Training.* 2007;42(2):311-319.
- Drosos GI, et al. The causes and mechanism of meniscal injuries in the sporting and non-sporting environment in an unselected population. *The Knee.* 2003;11:143-149.
- Brindle T, et al. The meniscus: review of basic principles with application to surgery and rehabilitation. *Journal of Athletic Training.* 2001;36(2):160-169.

22. King D. The function of semilunar cartilages. *Journal of Bone and Joint Surgery America*. 1936;18(4):1069-1076.
23. Brantigan OC, et al. The mechanics of the ligaments and menisci of the knee joint. *Journal of Bone and Joint Surgery America*. 1941;23:44-66.
24. Last RJ. Some anatomical details of the knee joint. *Journal of Bone and Joint Surgery*. 1948;30(4):683-688.
25. Bourne RB, et al. The effect of medial meniscectomy on strain distribution in the proximal part of the tibia. *J Bone Joint Surg Am*. 1984;66-A(9):1431-1437.
26. Davies DV, et al. The blood supply of the synovial membrane and intra-articular structures. *Ann R Coll Surg Engl*. 1948;2(3):142-156.
27. Trias A. Effect of persistent pressure on articular cartilage: an experimental study. *J Bone Joint Surg*. 1961;43-B(2):376-386.
28. Mankin HJ. The response of articular cartilage to mechanical injury. *J Bone Joint Surg*. 1982;64-A(3):460-466.
29. Messner K, et al. The menisci of the knee joint: anatomical and functional characteristics, and a rationale for clinical treatment. *J Anat*. 1998;193:161-178.
30. McCann L, et al. Influence of the meniscus on friction and degradation of cartilage in the knee joint. Available at: <http://www.ncbi.nlm.nih.gov/pubmed/19328878>. Accessed June 4, 2009.
31. Arnoczky SP, et al. Microvasculature of the human meniscus. *Am J Sports Med*. 1982;10(2): 90-95.
32. King D. The healing of semilunar cartilages. *J Bone Joint Surg Am*. 1936;18(2):333-342.
33. Greis PE, et al. Meniscal injury I: basic science and evaluation. *J Am Acad Orthop Surg*. 2002;10(3):168-176.
34. Shakespeare DT, et al. The bucket-handle tear of the meniscus: a clinical and arthrographic study. *J Bone Joint Surg Br*. 1983;65-B(4):383-387.
35. Andrich H. Meniscal injuries in children and adolescents: diagnosis and management. *J Am Acad Orthop Surg*. 1996;4(5):231-237.
36. Englund M, et al. Incidental meniscal findings on knee MRI in middle-aged and elderly persons. *N Engl J Med*. 2008;359(11):1108-1115.
37. Petersen W, et al. Age-related blood and lymph supply of the knee menisci. *Acta Orthop Scand*. 1995;66(4):308-312.
38. Belzer JP, et al. Meniscus tears: treatment in the stable and unstable knee. *J Am Acad Orthop Surg*. 1993;1(1):41-47.
39. Scott GA, et al. Combined posterior incision and arthroscopic intra-articular repair of the meniscus: an examination of factor affecting healing. *J Bone Joint Surg Am*. 1986;68(6):847-861.
40. O'Donoghue DH. Surgical treatments of fresh injuries to the major ligaments of the knee. *J Bone Joint Surg Am*. 1950;32:721-738.
41. Shelbourne KD, et al. The O'Donoghue triad revisited: combined knee injuries involving anterior cruciate and medial collateral ligament tears. *Am J Sports Med*. 1991;19:474-477.
42. De Pablos Fernandez J, et al. The O'Donoghue terrible triad observations on 34 anterior cruciate ligament (ACL) injuries in adolescents and pre-adolescents. *J Bone Joint Surg Br*. 2006;88-B:118.
43. Cipolla M, et al. Different patterns of meniscal tears in acute anterior cruciate ligament (ACL) ruptures and in chronic ACL-deficient knees. *Knee Surg, Sports Traumatol, Arthroscopy*. 1995;3:130-134.
44. Yaniv M, et al. The discoid meniscus. *J Child Orthop*. 2007;1(2):89-96.
45. Smillie IS. The congenital discoid meniscus. *J Bone Joint Surg*. 1948;30-B(4):671-682.
46. Rohren EM, et al. Discoid lateral meniscus and the frequency of meniscal tears. *Skeletal Radiology*. 2001;30(6):316-320.
47. Major NA, et al. MR imaging of the knee: findings in asymptomatic collegiate basketball players. *AJR*. 2002;179:641-644.
48. Kornick J. Meniscal abnormalities in the asymptomatic population at MR imaging. *Radiology*. 1990;177:463-465.
49. Takeda Y. MRI high-signal intensity in the menisci of asymptomatic children. *The Journal of Bone and Joint Surgery*. 1998;80B:463-467.
50. Englund M, et al. Incidental meniscal findings on knee MRI in middle-aged and elderly persons. *The New England Journal of Medicine*. 2008;359P:1108-1115.
51. Rose NE, et al. A comparison of accuracy between clinical examination and magnetic resonance imaging in the diagnosis of meniscal and anterior cruciate ligament tears. *Arthroscopy: The Journal of Arthroscopic and Related Surgery*. 1996;12(4):389-405.
52. Zanetti M, et al. Patients with suspected meniscal tears: prevalence of abnormalities seen on MRI of 100 symptomatic and 100 asymptomatic contralateral asymptomatic knees. *AJR*. 2003;181:635-641.
53. Madhusudhan TR, et al. Clinical examination, MRI and arthroscopy in meniscal and ligamentous knee injuries- a prospective study. *Journal of Orthopaedic Surgery and Research*. 2008;3(19).
54. Jah AAE, et al. Accuracy of MRI in comparison with clinical and arthroscopic findings in ligamentous and meniscal injuries of the knee. *Acta Orthop Belg*. 2005;71(2):189-196.
55. Gelb HJ, et al. Magnetic resonance imaging of knee disorders. Clinical value and cost effectiveness in a sports medicine practice. *Am J Sports Med*. 1996;24(1):99-103.
56. Liodakis E, et al. The role of preoperative MRI in knee arthroscopy: a retrospective analysis of 2,000 patients. *Knee Surg Sports Traumatol Arthrosc*. 2009;17(9):1102-1106.
57. Miller GK. A prospective study comparing the accuracy of the clinical diagnosis of meniscus tear with magnetic resonance imaging and its effect on clinical outcome. *Arthroscopy: The Journal of Arthroscopic and Related Surgery*. 1996;12(4):406-413.
58. Quinn SF, et al. Meniscal tears diagnosed with MR imaging versus arthroscopy: how reliable a standard is arthroscopy? *Radiology*. 1991;181(3):843-847.

59. Stanitski CL. Correlation of arthroscopy and clinical examination with magnetic resonance imaging findings in injured knees in children and adolescents. *Am J Sports Med.* 1998;26(1):2-6.
60. MedNews. X-ray often better and cheaper than MRI in knee diagnostics. 2008. <http://mednews.com/mri-xray-knee-diagnostics>. Accessed May 12, 2010.
61. Vahey T. MR imaging of the knee: pseudotear of the lateral meniscus caused by the meniscofemoral ligament. *American Journal of Radiology.* 1990;154:1233-1235.
62. McCarty EC, et al. Meniscal tears in the athlete: operative and non-operative management. *Phys Med Rehabil Clin N Am.* 2000;11(4):867-880.
63. Jorgensen U, et al. Long-term follow-up of meniscectomy in athletes. *J Bone Joint Surg.* 1987;69-B(1):80-83.
64. McNicholas MJ, et al. Total meniscectomy in adolescents: a thirty-year follow-up. *J Bone Joint Surg Br.* 2000;82-B(2):217-221.
65. Hoser C, et al. Long-term results of arthroscopic partial lateral meniscectomy in knees without associated damage. *J Bone Joint Surg Br.* 2001;83-B(4):513-516.
66. Tapper EM, et al. Late results after meniscectomy. *J Bone Joint Surg Am.* 1969;51-A(3):517-603.
67. Sharma L, et al. Relationship of meniscal damage, meniscal extrusion, malalignment, and joint laxity to subsequent cartilage loss in osteoarthritic knees. *Arthritis & Rheumatism.* 2008;58(6):1716-1726.
68. Roos E. Joint injury causes knee osteoarthritis in young adults. *Curr Opin Rheumatol.* 2005;17(2):195-200.
69. Aglietti P, et al. Arthroscopic meniscectomy for discoid lateral meniscus in children and adolescents: a 10-year follow-up. *Am J Knee Surg.* 1999;12(2):83-87.
70. Allen PR, et al. Late degenerative changes after meniscectomy: factors affecting the knee after operation. *J Bone Joint Surg.* 1984;66-B(5):666-671.
71. Englund M, et al. Patellofemoral osteoarthritis coexistent with tibiofemoral osteoarthritis in a meniscectomy population. *Ann Rheum Dis.* 2005;64:1721-1726.
72. Jackson JP. Degenerative changes in the knee after meniscectomy. *Brit Med J.* 1968;2:525-527.
73. Rangger C. Osteoarthritis after arthroscopic partial meniscectomy. *Am J Sports Med.* 1995;23(2):240-241.
74. Roos H, et al. Knee osteoarthritis after meniscectomy: prevalence of radiographic changes after twenty-one years, compared with matched controls. *Arthritis & Rheumatism.* 1998;41(4):687-693.
75. Dandy DJ, et al. The diagnosis of problems after meniscectomy. *J Bone Joint Surg.* 1975;57-B(3):349-352.
76. Neuman P, et al. Prevalence of tibiofemoral osteoarthritis 15 years after nonoperative treatment of anterior cruciate ligament injury: a prospective cohort study. *American Journal of Sports Medicine.* 2008; 36:1717-1725.
77. Hoshino A, et al. Impact-absorbing properties of the human knee. *J Bone Joint Surg.* 1987;69-B(5):807-811.
78. Wilson W, et al. Pathways of load-induced cartilage damage causing cartilage degeneration in the knee after meniscectomy. *Journal of Biomechanics.* 2003;36:825-851.
79. Baratz MA, et al. Meniscal tears: the effect of meniscectomy and of repair on intraarticular contact areas and stress in the human knee: a preliminary report. *Am J Sports Med.* 1986;14:270-275.
80. Lee SJ, et al. Tibiofemoral contact mechanics after serial medial meniscectomies in the human cadaveric knee. *Am J Sports Med.* 2006;34(8):1334-1344.
81. Hunter DJ, et al. The association of meniscal pathologic changes with cartilage loss in symptomatic knee osteoarthritis. *Arthritis & Rheumatism.* 2006;54(3):795-801.
82. Sandell L, et al. Articular cartilage and changes in arthritis: cell biology of osteoarthritis. *Arthritis Research & Therapy.* 2001;3(2):107-113.
83. Hede A, et al. Articular cartilage changes following meniscal lesions: repair and meniscectomy studied in the rabbit knee. *Acta Orthop Scand.* 1991;62(4):319-322.
84. Krause WR, et al. Mechanical changes in the knee after meniscectomy. *J Bone Joint Surg Am.* 1976;58-A(5):599-604.
85. Hanna F. Factors influencing longitudinal change in knee cartilage volume measured from magnetic resonance imaging in healthy men. *Annals of Rheumatic Diseases.* 2005;64:1038-1042.
86. Fairbank TJ. Knee joint changes after meniscectomy. *J Bone Joint Surg.* 1948;30-B(4):664-670.
87. Gelber AC, et al. Joint injury in young adults and risk for subsequent knee and hip osteoarthritis. *Annals of Internal Medicine.* 2000;133(5):321-328.
88. Appleyard RC, et al. Biomechanical, histological, and immunohistological studies of patellar cartilage in an ovine model of osteoarthritis induced by later meniscectomy. *Osteoarthritis and Cartilage.* 1999;7(3):281-294.
89. Cincutini FM, et al. Rate of knee cartilage loss after partial meniscectomy. *Journal of Rheumatology.* 2002;29(9):1954-1956.
90. Raynauld JP, et al. Long term evaluation of disease progression through the quantitative magnetic resonance imaging of symptomatic knee osteoarthritis patients: correlation with clinical symptoms and radiographic changes. *Arthritis Research & Therapy.* 2006;8(1):R21.
91. Wluka A, et al. Knee cartilage loss in symptomatic knee osteoarthritis over 4.5 years. *Arthritis & Research Therapy.* 2006;8(4):R90.
92. Johnson RJ, et al. Factors affecting late results after meniscectomy. *J Bone Joint Surg.* 1974;56-A(4):719-729.
93. Tapper EM, et al. Late results after meniscectomy. *J Bone Joint Surg Am.* 1969;51-A(3):517-603.
94. Williams RJ, et al. MRI evaluation of isolated arthroscopic partial meniscectomy patients at minimum five-year follow up. *HSS J.* 2007;3(1):35-43.
95. Hede A, et al. Partial versus total meniscectomy: a prospective, randomized study with long-term follow-up. *J Bone Joint Surg.* 1992;74-B(1):118-121.

96. McGinity JB, et al. Partial or total meniscectomy: a comparative analysis. *J Bone Joint Surg Am.* 1977;59-A(6):763-766.
97. Greis PE, et al. Meniscal injury II: management. *J Am Acad Orthop Surg.* 2002;10(3):177-187.
98. Cannon WD, et al. Meniscal repair: part II: arthroscopic repair techniques. *J Bone Joint Surg Am.* 1994;76:294-311.
99. O'Shea JJ, et al. Repair of locked bucket-handle meniscal tears in knees with chronic anterior cruciate ligament deficiency. *Am J Sports Med.* 2003;31(2):216-219.
100. Bach BR, et al. Arthroscopic meniscal repair: analysis of treatment failures. *Journal of Knee Surgery.* 2005;18(4).
101. Pujol N, et al. Meniscal healing after meniscus repair: a CT arthrography assessment. *Am J Sports Med.* 2008;36(8):1489-1495.
102. Rockborn P, et al. Results of open meniscus repair: long-term follow-up study with a matched uninjured control group. *J Bone Joint Surg Br.* 2000;82-B(4):494-498.
103. DeHaven KE, et al. Open meniscus repair. *Am J Sports Med.* 1989;17(6):788-795.
104. DeHaven KE, et al. Long-term results of open meniscal repair. *Am J Sports Med.* 1995;23:524-530.
105. Eggli S, et al. Long-term results of arthroscopic meniscal repair: an analysis of isolated tears. *Am J Sports Med.* 2008;36:1489-1495.
106. Morgan CD, et al. Arthroscopic meniscal repair evaluated by second-look arthroscopy. *Am J Sports Med.* 1991;19:632-638.
107. Rubman MH, et al. Arthroscopic repair of meniscal tears that extend into the avascular zone: a review of 98 single and complex tears. *Am J Sports Med.* 1998;26:87-95.
108. Krych AJ, et al. Arthroscopic repair of isolated meniscal tears in patients 18 years and younger. *Am J Sports Med.* 2008;36(7):1283-1289.
109. Abdelkafy A, et al. Two to nineteen years follow-up of arthroscopic meniscal repair using the outside-in technique: a retrospective study. *Archives of Orthopaedic and Trauma Surgery.* 2007;127(4):245-252.
110. Hamberg P, et al. Suture of new and old peripheral meniscus tears. *J Bone Joint Surg Am.* 1983;65-A(2):193-197.
111. Kurosaka M, et al. Repeat tears of repaired menisci after arthroscopic confirmation of healing. *J Bone Joint Surg Br.* 2002;84-B(1):34-37.
112. Falazare JJ, et al. Meniscal repair of the knee. *Orthopaedics.* 2002;32:199-206.
113. Farr J, et al. Current meniscal allograft transplantation. *Sports Med Arthroscop Rev.* 2004;12(1):69-82.
114. Noyes FR, et al. Meniscal transplantation in symptomatic patients less than fifty years old. *J Bone Joint Surg.* 2004;86-A(7):1392-1404.
115. Cole B, et al. Allograft meniscal transplantation: background techniques and results. *Journal of Bone and Joint Surgery.* 2002;84A:1236-1250.
116. Lohmander LS, et al. The long-term consequences of anterior cruciate ligament and meniscal injuries: osteoarthritis. *American Journal of Sports Medicine.* 2007;35:1756-1769.
117. Peters TJ, et al. Studies on the chemical composition of the menisci of the knee joint with special reference to the horizontal cleavage lesion. *Clinical Orthopaedics.* 1972;86:245-252.
118. Rodkey WG. Basic biology of the meniscus and response to injury. *Instructional Course Lecture.* 2000;49:189-193.
119. Koski JA, et al. Meniscal injury and repair: clinical status. *Orthop Clin North America.* 2000; 31:419-436.
120. Rath E, et al. Meniscal allograft transplantation: Two-to eight-year results. *Am J Sports Med.* 2001;29(4):410-414.
121. Van Arkel ERA, et al. Survival analysis of human meniscal transplantation. *J Bone Joint Surg Br.* 2002;84-B(2):227-231.
122. Merkel KH. The surface of human menisci and its aging alterations during age. A combined scanning and transmission electron microscopic examination. *Archives of Orthopaedic and Trauma Surgery.* 1980;97:185-191.
123. Crane D, et al. Platelet rich plasma (PRP) matrix grafts. *Practical Pain Management.* 2008;12-26,
124. Marx RE. Platelet-rich plasma: Evidence to support its use. *Journal of Oral Maxillofacial Surgery.* 2004;62:489-496.
125. Sampson S, et al. Platelet-rich plasma injection grafts for musculoskeletal injuries: a review. *Current Reviews in Musculoskeletal Medicine.* 2008;1:165-174.
126. McNulty AL, et al. Integrative repair of the meniscus: lessons from in vitro. *Biorheology.* 2008;45:487-500.
127. Izal I, et al. In vitro healing of avascular meniscal injuries with fresh and frozen plugs treated with TGF-BA and IGF-1 in sheep. *International Journal of Experimental Pathology.* 2008;1:426-434.
128. Pangborn CA, et al. Growth factors and fibrochondrocytes in scaffolds. *Journal of Orthopaedic Research.* 2010;23:1184-1190.
129. Pangborn CA, et al. Effects of growth factors on meniscal fibrochondrocytes. *Tissue Engineering.* 2005;11:1141-1148.
130. Cook JL. The current status of treatment of large meniscal defects. *Clinical Orthopaedics and Related Research.* 2005;435:88-95.
131. Angel MJ. Meniscus repair and future directions. In: *Knee Arthroscopy.* New York: Springer; 2009. p. 25-52.
132. Bhargava MM, et al. The effect of cytokines on the proliferation and migration of bovine meniscal cells. *The American Journal of Sports Medicine.* 1999;27:636-643.
133. Spindler KP, et al. Regional mitogenic response of the meniscus to platelet-derived growth factor (PDGF-AB). *Journal of Orthopaedic Research.* 2005;13:201-207.
134. Bhargava MM, et al. Effect of hepatocyte growth factor and platelet-derived growth factor on the repair of meniscal defects. *In Vitro Cellular & Developmental Biology- Animal.* 2005;41(8/9):305-310.
135. Murray MM, et al. Enhanced histologic repair in a central wound in the anterior cruciate ligament with a collagen-platelet-rich plasma scaffold. *Journal of Orthopaedic Research.* 2007;25:1007-1017.
136. Collier S, et al. Effects of transforming growth factor beta on proteoglycan synthesis by cell and explant cultures derived from knee joint meniscus. *Osteoarthritis and Cartilage.* 1995;3:127-138.

137. Hashimoto J, et al. Meniscal repair using fibrin sealant and endothelial growth factor. *The American Journal of Sports Medicine*. 1992;20:537-541.
138. Tumia NS, et al. Promoting the proliferative and synthetic activity of knee meniscal fibrochondrocytes using basic fibroblast growth factor in vitro. *The American Journal of Sports Medicine*. 2004;32:915-920.
139. Tumia NS, et al. Platelet derived growth factor-AB enhances knee meniscal cell activity in vitro. *The Knee*. 2009;16:73-76.
140. Webber RJ, et al. Cell culture of rabbit meniscal fibrochondrocytes: proliferative and synthetic response to growth factors and ascorbate. *Journal of Orthopaedic Research*. 2005;3:36-42.
141. Ghadially FN, et al. Ultrastructure of rabbit semilunar cartilages. *Journal of Anatomy*. 1978;125:499-517.
142. McDevitt CA, et al. The ultrastructure and biochemistry of meniscal cartilage. *Clinical Orthopaedics*. 1990;Mar(252):8-18.
143. Martinek V, et al. Second generation of meniscus transplantation: in vivo study with tissue engineered meniscus replacement. *Archives of Orthopaedic and Trauma Surgery*. 2006;126:228-234.
144. Sclafani AP, et al. Modulation of wound response and soft tissue ingrowth in synthetic and allogenic implants with platelet concentrate. *Arch facial plast surg*. 2005;7:163-169.
145. Reeves KD. Technique of Prolotherapy. In Lennard T. *Physiatric Procedures in Clinical Practice*. Philadelphia, PA: Hanley & Belfus; 1995. p. 57-70.
146. Reeves KD. Prolotherapy: Basic Science, Clinical Studies, and Technique. In Lennard, T. *Pain Procedures in Clinical Practice, Second Edition*. Philadelphia, PA: Hanley & Belfus; 2000. p. 172-190.
147. Okuda Y, et al. Increased production of PDGH by angiotensin and high glucose in human vascular endothelium. *Life Sciences*. 1996;59:455-461.
148. Pugliese G, et al. Increased activity of the insulin-like growth factor system in mesangial cells cultured in high glucose conditions. Relation to glucose-enhanced extracellular matrix production. *Diabetologia*. 1996;39:775-784.
149. Kolm-Litty V, et al. High glucose-induced transforming growth factor beta 1 production is mediated by the hexosamine pathway in porcine glomerular mesangial cells. *Journal of Clinical Investigation*. 1998;101:160-169.
150. Liu X, et al. High glucose upregulates connective tissue growth factor expression in human vascular smooth muscle cells. *BMC Cell Biology*. 2007;8:1-14.
151. Hauser R. The regeneration of articular cartilage with Prolotherapy. *Journal of Prolotherapy*. 2009;1(1):39-44.
152. Barkan A. Acromegalic arthropathy and sleep apnea. *Journal of Endocrinology*. 1997;155:S41-S44.
153. Chrisman OD. The effect of growth hormone on established cartilage lesions. *Clinical Orthopaedics*. 1975;107:232-238.
154. Sledge CB. Growth hormone and articular cartilage. *Federation Proceedings*. 1973;32:2503-1505.
155. Smith R. Growth hormone stimulates insulin-like growth factor action on adult articular chondrocytes. *Journal of Orthopaedic Research*. 1989;7:198-207.
156. Werther G. Visual demonstration of growth hormone receptors on human growth plate chondrocytes. *Journal of Clinical Endocrinology & Metabolism*. 1990;70:1725-1731.
157. Hauser R, et al. Standard clinical X-ray studies document cartilage regeneration. *Journal of Prolotherapy*. 2009;1:22-28.
158. Reeves K. Randomized, prospective, double-blind placebo-controlled study of dextrose Prolotherapy for knee osteoarthritis with or without ACL laxity. *Alternative Therapies*. 2000;6:311-320.
159. Jo DH, et al. The effects of Prolotherapy on knee joint pain due to ligament laxity. *Korean Pain Society*. 2004;17(1):47-50.
160. Kim JM. The effect of Prolotherapy for osteoarthritis of the knee. *J Korean Acad Rehabil Med*. 2002;26(4):445-448.
161. Jacks A, et al. A retrospective audit of patients with osteoarthritic knees treated with Prolotherapy in a general practice. *International Musculoskeletal Medicine*. 2008;30(2):61-66.
162. Pietrzak W, et al. Scientific foundations platelet rich plasma: biology and new technology. *Journal of Craniofacial Surgery*. 2005;16:1043-1054.
163. Sampson S, et al. Platelet rich plasma injection grafts for musculoskeletal injuries: a review. *Current Review in Musculoskeletal Medicine*. 2008;1:165-174.
164. Antigua E, et al. Autologous preparations rich in growth factors promote proliferation and induce VEGF and HGF productions by human tendon cells in culture. *Journal of Orthopaedic Research*. 2005;23:281-286.
165. Sanchez, et al. Intra-articular injection of an autologous preparation rich in growth factors for the treatment of knee OA: a retrospective cohort study. *Clinical Experimental Rheumatology*. 2008;26:910-913.
166. Hackett GS. *Ligament and tendon relaxation treated by Prolotherapy*, Third Edition. Springfield, IL: Charles C Thomas; 1956.
167. Hauser R, et al. *Prolo Your Pain Away!* Third Edition. Oak Park, IL: Beulah Land Press; 2007.
168. Hauser R, et al. *Prolo Your Sports Injuries Away!* Oak Park, IL: Beulah Land Press; 2001.
169. Hauser R, et al. A retrospective study on dextrose Prolotherapy for unresolved knee pain. *Journal of Prolotherapy*. 2009;1(1):11-21.