

# Intratendinous Injection of Autologous Adipose Tissue-Derived Mesenchymal Stem Cells for the Treatment of Rotator Cuff Disease: A First-In-Human Trial

CHRIS H. JO <sup>a,b</sup>, JEE WON CHAI,<sup>c</sup> EUI CHEOL JEONG,<sup>d</sup> SOHEE OH,<sup>e</sup> PAUL S. KIM,<sup>a</sup> JEONG YONG YOON,<sup>a</sup> KANG SUP YOON<sup>a</sup>

**Key Words.** Rotator cuff disease • Rotator cuff tear • Mesenchymal stem cells • Intratendinous injection • Clinical trial

<sup>a</sup>Department of Orthopedic Surgery, <sup>c</sup>Department of Radiology, <sup>d</sup>Department of Plastic and Reconstructive Surgery, <sup>e</sup>Department of Biostatistics, Seoul National University College of Medicine, SMG-SNU Boramae Medical Center, Seoul, Korea; <sup>b</sup>Department of Translational Medicine, Seoul National University College of Medicine, Seoul, Korea

Correspondence: Chris H. Jo, M.D., Ph.D., Department of Orthopedic Surgery, Seoul National University College of Medicine, SMG-SNU Boramae Medical Center, 20 Boramae-ro 5-gil, Dongjak-gu, Seoul 07061, Korea. Telephone: 82-2-870-2315; e-mail: chrisjo@snu.ac.kr

Received February 19, 2018; accepted for publication May 11, 2018; first published online in *STEM CELLS EXPRESS* May 23, 2018.

<http://dx.doi.org/10.1002/stem.2855>

## ABSTRACT

Despite relatively good results of current symptomatic treatments for rotator cuff disease, there has been an unmet need for fundamental treatments to halt or reverse the progress of disease. The purpose of this study was to assess the safety and efficacy of intratendinous injection of autologous adipose tissue-derived mesenchymal stem cells (AD MSCs) in patients with rotator cuff disease. The first part of the study consists of three dose-escalation cohorts; the low- ( $1.0 \times 10^7$  cells), mid- ( $5.0 \times 10^7$ ), and high-dose ( $1.0 \times 10^8$ ) groups with three patients each for the evaluation of the safety and tolerability. The second part included nine patients receiving the high-dose for the evaluation of the exploratory efficacy. The primary outcomes were the safety and the shoulder pain and disability index (SPADI). Secondary outcomes included clinical, radiological, and arthroscopic evaluations. Twenty patients were enrolled in the study, and two patients were excluded. Intratendinous injection of AD MSCs was not associated with adverse events. It significantly decreased the SPADI scores by 80% and 77% in the mid- and high-dose groups, respectively. Shoulder pain was significantly alleviated by 71% in the high-dose group. Magnetic resonance imaging examination showed that volume of the bursal-side defect significantly decreased by 90% in the high-dose group. Arthroscopic examination demonstrated that volume of the articular- and bursal-side defects decreased by 83% and 90% in the mid- and high-dose groups, respectively. Intratendinous injection of autologous AD MSCs in patient with a partial-thickness rotator cuff tear did not cause adverse events, but improved shoulder function, and relieved pain through regeneration of rotator cuff tendon. *STEM CELLS* 2018;36:1441–1450

## SIGNIFICANCE STATEMENT

Rotator cuff disease is the leading cause of shoulder pain. Despite favorable results of current symptomatic treatments for rotator cuff disease, there has been an unmet need for fundamental treatments to halt or reverse the progress of disease. This study shows that intratendinous injection of autologous adipose tissue-derived mesenchymal stem cells for the treatment of rotator cuff disease is feasible, safe, and effective with evidences of regeneration of tendon defect without surgery. It is believed that this study could be a start point for shifting the current paradigm of rotator cuff disease treatment, that is, from “undergo surgery after tear” to “inject stem cells before tear.”

## INTRODUCTION

Shoulder pain has been known as the third most common musculoskeletal pain (16%) next to back (23%) and knee (19%) pain in the general population [1]. However, it is the most common in the age group of the highest productivity, 40–59 years, posing a substantial socioeconomic burden [2]. Rotator cuff disease or tendinopathy is the leading cause of

shoulder pain accounting for up to 70% with more than 4.5 million physician visits and 300,000 repairs per year in the U.S. [3,4].

Whereas there has been considerable controversy among physicians on the optimal treatment for rotator cuff disease, initial treatment for patients with rotator cuff disease, even for patients with a full-thickness tear, would be conservative treatments such as rest, physiotherapy, non-steroidal anti-inflammatory

drugs, and corticosteroid injection. But, despite generally favorable outcomes after conservative treatments, a considerable number of patients (41%) showed persistent symptoms after 1 year of nonoperative treatments [5]. Especially, subacromial corticosteroid injection, one of the most heavily used conservative treatments, has been reported to provide only short-term pain relief without modifying the natural course of the disease, or even, it may be worse in the intermediate and long terms [6]. Of further concern, corticosteroid could induce non-tenogenic differentiation and depletion of tendon stem cells resulting in tendon tear [7]. Unrepaired tears would progress in size, develop symptoms, and deteriorate in muscle quality over time. Surgery can be considered in patients who failed conservative managements and in young patients with a repairable full-thickness tear. But, unpredictable retear rate up to 94% still remained as an unsolved problem. These limitations of current treatments suggest a need to look for more fundamental approaches toward tendon regeneration.

Mesenchymal stem cells (MSCs) have received tremendous attention for promising candidates for cell-based tendon regeneration [8]. The majority of *in vivo* studies used acute transection or window defects models simulating surgical application of MSCs with or without scaffold and demonstrated positive results [9]. However, a few studies in horses adopted intratendinous injection of MSCs and demonstrated its safety and beneficial effects in reducing the re-injury rate [10]. Application of MSCs via injection, not surgery, should provide invaluable treatment opportunity to patients if it could be translated into routine clinical practice as it would avoid surgery and concomitant risks as well expedite recovery. Despite these potentials, no clinical trial using injection of MSCs for rotator cuff disease has been reported.

Therefore, we conducted a clinical trial to assess the safety and exploratory efficacy of intratendinous injection of autologous adipose tissue-derived MSCs (AD MSCs) in patients with rotator cuff disease. We report the clinical, radiological, and arthroscopic results.

## MATERIALS AND METHODS

### Study Designs and Participants

This study was an open-label, single-center, dose-escalation trial with no active control conducted between July 2015 and November 2016 at SMG-SNU Boramae Medical Center, Seoul, Korea. The protocol was approved by the institutional review board of our institute and the Ministry of Food and Drug Safety (MFDS) of Korea. The trial was conducted in accordance with Good Clinical Practice and the Declaration of Helsinki. All participants provided written informed consent. The study contained two consecutive parts (Fig. 1). The first part of the study consisted of three dose-escalation cohorts; the low-, mid-, and high-dose group with 3 patients each. Patients in each dose group received  $1.0 \times 10^7$ ,  $5.0 \times 10^7$ , and  $1.0 \times 10^8$  cells in 3 ml of saline, respectively. After three patients in each cohort were followed up for 28 days after injection, a safety review was done before moving to the next dose. The second part of the study included 9 patients receiving the high-dose. Therefore, totally 18 patients were planned to be consecutively enrolled in the study. Eligible patients were those aged 19 years and over with unilateral shoulder pain for more than

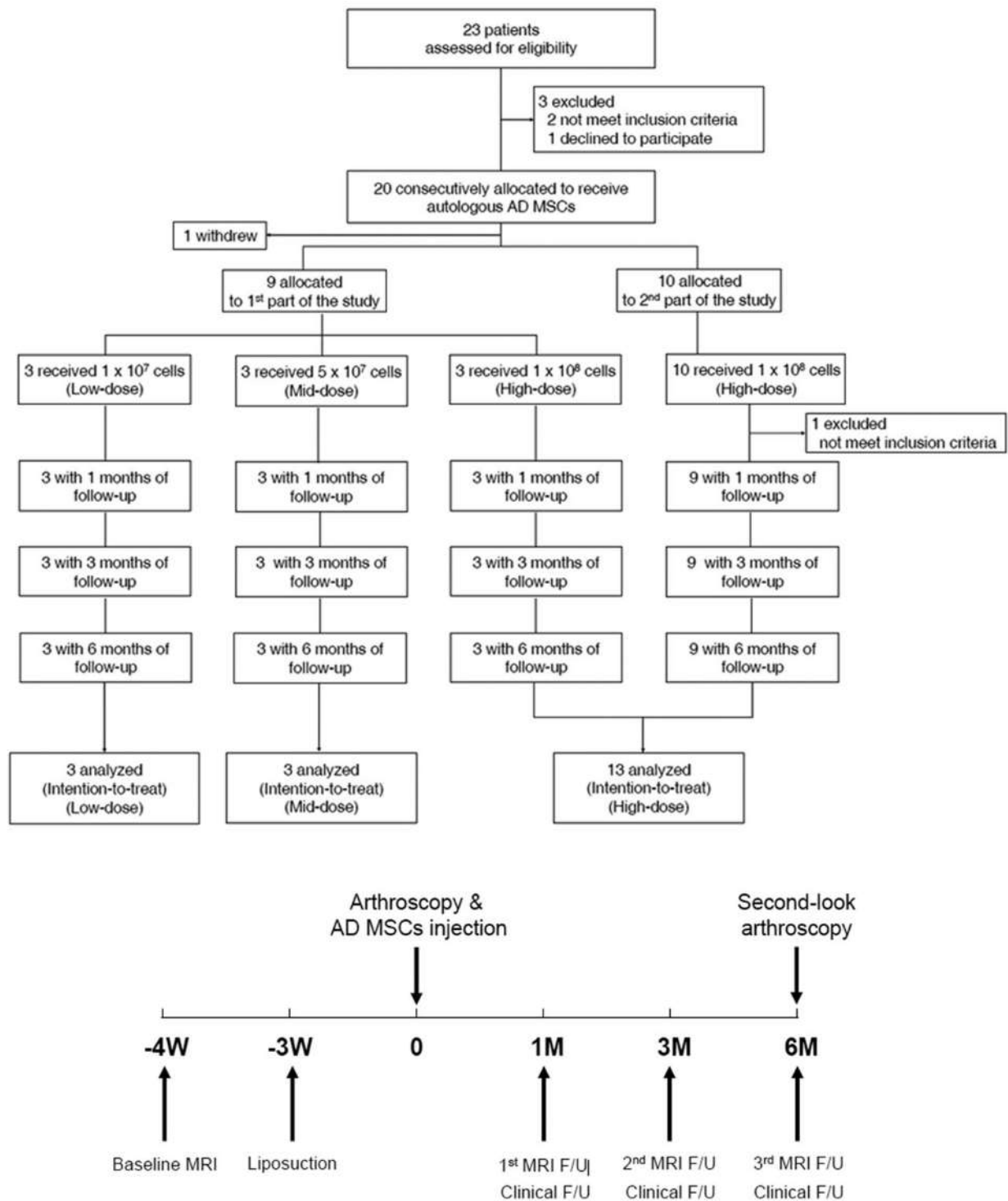
3 months of symptom duration, and were discovered to have a partial-thickness rotator cuff tear identified with ultrasonography or magnetic resonance imaging (MRI). Details of dose-escalating method and inclusion and exclusion criteria are described in the Supporting Information. Patients underwent physical examination, laboratory tests, including routine blood and urine tests, serologic tests, and the pregnant test if indicated, and MRI of the affected shoulder at screening after providing informed consent. Eligible patients returned to the hospital within 1 week for liposuction. Arthroscopic examination and AD MSCs injection were performed at 3 weeks after liposuction. Patients were followed up at 1, 3, and 6 months after injection. At each visit, the safety and efficacy assessments were performed. Furthermore, MRI of the shoulder was also obtained at 1, 3, and 6 months after injection. Second-look arthroscopy was performed at 6 months after injection. Independent safety and data monitors oversaw the overall trial process.

### Mesenchymal Stem Cell Preparation

AD MSCs were prepared from the abdominal subcutaneous fats by liposuction under current good manufacturing practice (cGMP) conditions, as previously described [11]. Briefly, liposuction was performed 3 weeks before injection. Harvested fat tissues were enzymatically digested and cells from stromal vascular fraction were isolated and cultured in Keratinocyte-SFM (Invitrogen)-based media containing 0.2 mM ascorbic acid, 0.09 mM calcium, 5 ng/ml recombinant epidermal growth factor, and 5% fetal bovine serum. When reached 90% confluence, cells were passaged. Characteristics of the culture-expanded mesenchymal stem cells including stability, toxicity, tumorigenicity, and the ability of multi-lineage differentiation were reported previously.

### Arthroscopy and Intratendinous AD MSCs Injection Under Ultrasonographic Guidance

All the arthroscopic and injection procedures were performed by single surgeon. After systematic glenohumeral joint and subacromial exploration, the rotator cuff defect on the articular and bursal side was carefully examined, and the anteroposterior and mediolateral sizes and the depth of defect were documented with a calibrated probe. If intratendinous defects were suspicious in the preoperative MRI, the bubble sign was checked. No synovectomy or debridement of any tissues was performed during arthroscopy, and no drainage was used. After thorough exploration, AD MSCs were injected through the lateral aspect of the shoulder under ultrasonographic guidance (Fig. 2A–2C). Briefly, rotator cuff tendon between the acromion and greater tuberosity of the humerus was visualized by applying sterilized transducer to the anterolateral aspect of the shoulder. A 22G needle was introduced under the transducer while visualizing it in real-time as a thin hyperechoic line. AD MSCs in 3 ml of saline was injected into the anterior, center, and posterior one third of the torn end of rotator cuff. After injection, the shoulder was immobilized for 4 weeks using an abduction brace. Shrugging, protraction, and retraction of shoulder girdles; intermittent exercise of the elbow, wrist, and hand; and external rotation of the arm to neutral with the brace were encouraged as tolerated, usually immediately after injection. Further passive range of motion (ROM) and active assisted ROM exercises were allowed after the



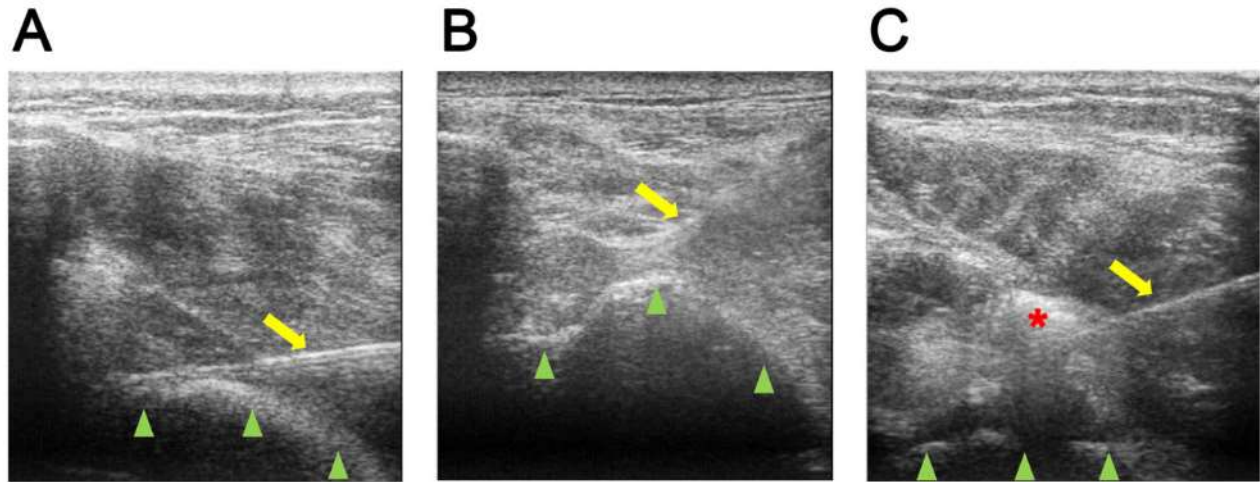
**Figure 1.** Study flow diagram. Abbreviations: AD MSC, adipose tissue-derived mesenchymal stem cells; F/U, follow-up; MRI, magnetic resonance imaging.

patient was gradually weaned off the abduction brace from 4 weeks after injection. Patients began strengthening exercises as soon as ROM was recovered.

**Outcome Measures**

The primary outcomes of the trial were the safety and the shoulder pain and disability index (SPADI) at 6 months after injection. Safety was assessed with vital signs, physical

examination, laboratory tests, and adverse events. Adverse events were categorized using National Cancer Institute - Common Terminology Criteria for Adverse Events version 4.0 scale (NCI – CTCAE v4.0). The SPADI has been shown to be feasible, valid and highly responsive instrument for assessing shoulder pain and function. The secondary outcome consisted of three categories: clinical, radiological, and arthroscopic. Clinical outcomes included another commonly used shoulder functional



**Figure 2.** Ultrasonographic guided injection of adipose tissue-derived mesenchymal stem cells (AD MSCs) into tendon defect of rotator cuff. **(A):** Injection into the articular-side tendon defect. **(B):** Injection into the bursal-side tendon defect. The yellow arrow indicates 22G spinal needle approached through the subacromial space; arrow heads indicate the greater tuberosity; the red asterisk appearing hyperechoic indicates injected AD MSCs.

score, the Constant score, and a visual analog scale (VAS) for shoulder pain on motion that was on a scale from 0 to 10. Radiological outcome included changes of volume of tendon defects measured using MRI between the time of cell injection and 6 months after injection by a blinded musculoskeletal radiologist. See the Supporting Information for MRI protocol and assessment. Arthroscopic outcomes were changes of volume of rotator cuff defects measured with a calibrated arthroscopic probe between the time of cell injection and 6 months after injection.

### Statistical Analysis

The sample size was determined in consultation with the MFDS of Korea. Data analysis in clinical, radiological, and arthroscopic outcomes was performed according to the cell dosage. All primary analyses were done based on the intention-to-treat principle. For analyses of outcome measures, missing data were replaced with multiple imputation by chained equation (MICE) method under a missing-at-random assumption. Ten imputed datasets were generated and analyzed separately in each imputed dataset for each outcome measure. The results were then combined across imputations using Rubin's method. In addition, a complete case analysis and the last observation-carried forward (LOCF) method were conducted for a sensitivity analysis. As all of the three methods showed similar results, we presented only the imputation analyses. A paired *t* test was used to assess within group change from the baseline at each follow-up time point. The statistical significance level was set at  $p < .05$ . All statistical analyses were performed using SAS version 9.4 (SAS Institute, Inc., Cary, NC) and R version 3.4.2 (R Foundation for Statistical Computing, Vienna, Austria).

## RESULTS

### Demographics of Patients

Between July 7, 2015 and November 7, 2016, 23 patients were assessed for eligibility and of whom 3 patients were excluded

before allocation (Fig. 1). Twenty patients were consecutively allocated to treatment groups, and one patient withdrew his consent after liposuction. Nineteen patients were consecutively enrolled into the study and received AD MSCs. Baseline characteristics of patients were not significantly different between treatment groups except for the SPADI score (Table 1). All of patients were suffered from shoulder pain for at least more than seven months despite conservative treatments. No patient had a history of shoulder surgery. With MRI examination before injection, four articular-side tears (21%), 14 bursal-side tears (74%), three intratendinous tears (16%) were identified. Eighteen patients completed 6 months of follow-up whereas two patients in the mid- and high-dose groups refused to undergo second-look arthroscopy. One individual was excluded because he was found to have a focal full-thickness tear just after cell injection. He was later treated with arthroscopic rotator cuff repair.

### Safety

Adverse events occurred in one (33%), one (33%), and five (39%) patients in the low-, mid-, and high-dose group, respectively (Table 2). None of them was grade 3 or 4 by NCI-CTCAE scale or treatment-related (Supporting Information Table S1). There was no serious adverse event. The most common adverse event was back pain, which developed in three patients. One patient in the low-dose group had undergone surgery for lumbar intervertebral disc herniation 3 years before enrollment and have had low back pain from time to time. He also reported buttock and radiating pain down to the right lower extremity. He was treated with rescue drug (a tablet of tramadol HCl 18.75 mg/acetaminophen 162.5 mg) and local injection. Whereas back pain was much relieved after treatment, buttock and radiating pain was not improved completely until the completion of the follow-up. The other two patients with back pain were managed with physical therapy and rescue drug, respectively. No patients were discontinued from the study because of adverse events. There were no clinically important trends in the results of physical examination, vital signs, laboratory test during the study.

**Table 1.** Baseline characteristics of patients

|                                         | Low-dose (n = 3)    | Mid-dose (n = 3)    | High-dose (n = 13)  |
|-----------------------------------------|---------------------|---------------------|---------------------|
| Cells injected                          | 1 × 10 <sup>7</sup> | 5 × 10 <sup>7</sup> | 1 × 10 <sup>8</sup> |
| Age (years)                             | 65.7 (9.1)          | 50.3 (13.4)         | 56.9 (9.7)          |
| Sex                                     |                     |                     |                     |
| Male                                    | 1 (33%)             | 2 (67%)             | 2 (15%)             |
| Female                                  | 2 (67%)             | 1 (33%)             | 11 (85%)            |
| Height (cm)                             | 158.7 (15.1)        | 160.7 (13.5)        | 155.9 (5.6)         |
| Weight (Kg)                             | 60.5 (19.7)         | 65.0 (13.3)         | 58.0 (9.4)          |
| Body-mass index (kg/m <sup>2</sup> )    | 23.5 (3.3)          | 25.0 (1.1)          | 23.7 (2.6)          |
| Dominance                               |                     |                     |                     |
| Yes                                     | 2 (67%)             | 3 (100%)            | 13 (100%)           |
| No                                      | 1 (33%)             | 0                   | 0                   |
| Duration of symptoms (month)            | 23.0 (15.5)         | 7.4 (4.4)           | 28.8 (25.3)         |
| Previous treatment history <sup>a</sup> |                     |                     |                     |
| Surgery                                 | 0                   | 0                   | 0                   |
| Pharmaceutical                          | 3 (100%)            | 3 (100%)            | 13 (100%)           |
| Injection                               | 1 (33%)             | 2 (67%)             | 10 (77%)            |
| Physiotherapy                           | 1 (33%)             | 2 (67%)             | 7 (54%)             |
| Acupuncture                             | 1 (33%)             | 0                   | 4 (31%)             |
| SPADI score                             | 44.1 (11.8)         | 63.8 (8.5)          | 75.4 (9.9)          |
| Constant score                          | 60.8 (16.7)         | 60.9 (11.0)         | 55.7 (6.5)          |
| VAS pain                                | 76.7 (15.3)         | 90.0 (10.0)         | 90.0 (5.8)          |
| Tear location <sup>b</sup>              |                     |                     |                     |
| Articular-side                          | 0                   | 0                   | 4 (31%)             |
| Bursal-side                             | 3 (100%)            | 3 (100%)            | 8 (62%)             |
| Intratendinous                          | 1 (33%)             | 0                   | 2 (15%)             |

Data are number (%) or mean (SD).

<sup>a</sup>Each patient was asked whether he/she received surgery, pharmaceutical treatment, injection, physiotherapy, or acupuncture during last 3 months (yes or no).

<sup>b</sup>Identified with MRI examination before injection.

Abbreviations: SPADI, shoulder pain and disability index; VAS, visual analog scale.

**Table 2.** Summary of adverse events

|                                 | Low-dose (n = 3) | Mid-dose (n = 3) | High-dose (n = 13) |
|---------------------------------|------------------|------------------|--------------------|
| Patients with AEs <sup>a</sup>  |                  |                  |                    |
| All                             | 1 (33%)          | 1 (33%)          | 5 (39%)            |
| Treatment-related               | 0                | 0                | 0                  |
| Patients with SAEs <sup>b</sup> |                  |                  |                    |
| All                             | 0                | 0                | 0                  |
| Treatment-related               | 0                | 0                | 0                  |

Data are number (%).

<sup>a</sup>An AE is defined as any undesired medical incident which is not necessarily in cause-and-effect relationship to the treatment.

<sup>b</sup>A SAE is defined as any undesired medical incident which results in death, is life threatening, requires hospitalization, causes disability, or results in a congenital abnormality or birth defect.

Abbreviations: AE, adverse event; SAE, serious adverse events.

### Clinical Outcomes

AD MSCs injection significantly improved the SPADI scores of mid- and high-dose groups by 80% ( $p = .020$ ), and 77% decreases ( $p < .001$ ), respectively, at 6 months after injection as compared with those at baseline (Fig. 3A and Supporting Information Table S2). A nonsignificant 58% decrease was reported in the low-dose group ( $p = .0729$ ). The Constant score significantly increased in the mid- and high-dose groups by 27% ( $p = .014$ ), and 20% ( $p = .005$ ), respectively (Fig. 3B and Supporting Information Table S3). Patients in the low-dose group did not improve over 6 months. VAS pain on motion significantly decreased by 71% ( $p < .001$ ) in the high-dose group (Fig. 3C and Supporting Information Table S4). Nonsignificant

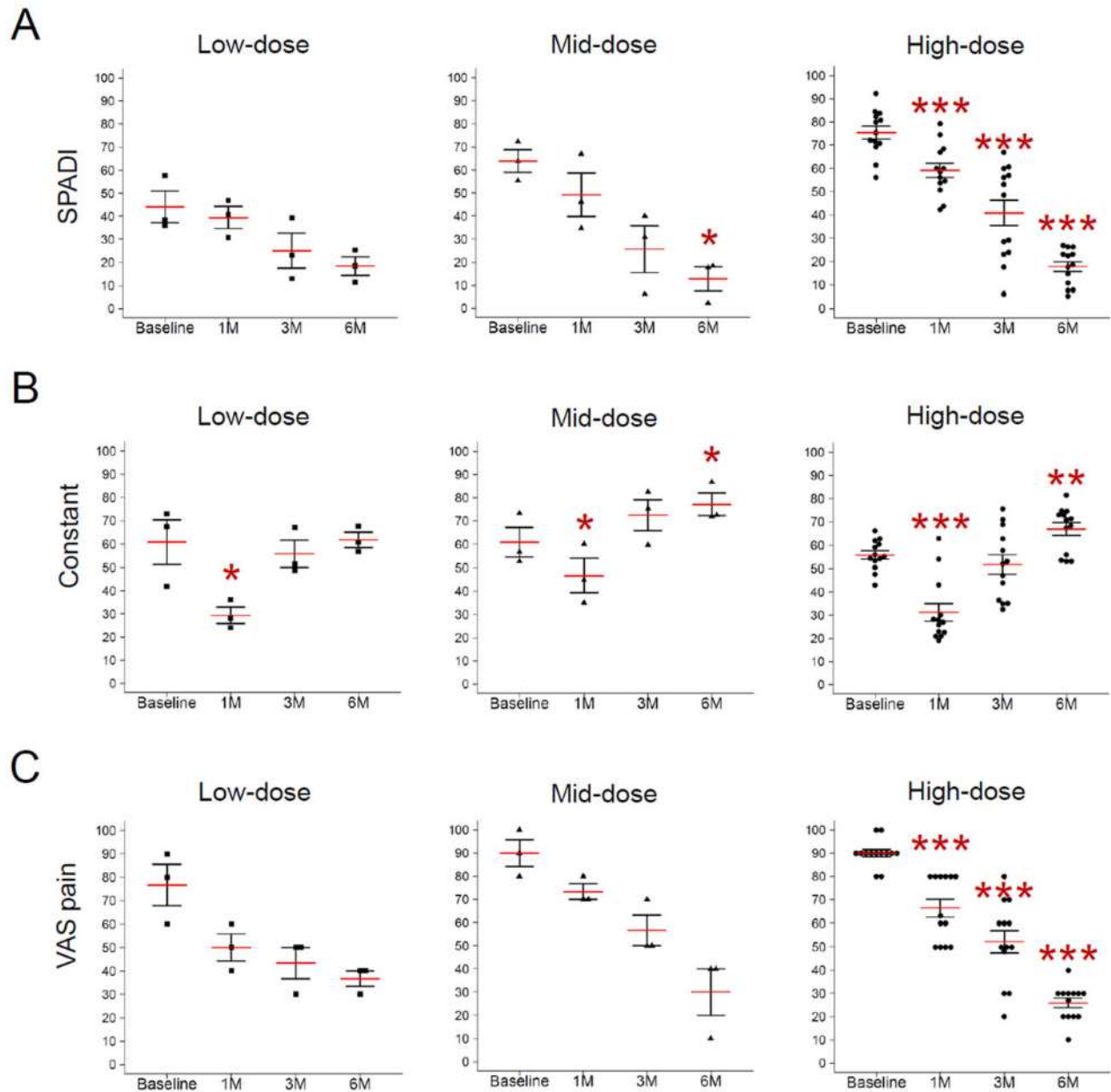
decreases of 52% ( $p = .074$ ), and 67% ( $p = .059$ ) were found in the low- and mid-dose groups, respectively.

### Radiological Outcomes

MRI assessment of tendon defect showed that volume of the bursal-side defect in the high-dose group significantly decreased by 90% over 6 months after injection (Fig. 4A, 4B, and Supporting Information Table S5). Nonsignificant decreases were also identified; 43% decrease of the articular-side defect were identified in the high-dose group ( $p = .512$ ); 69% decrease of the bursal-side defect in the mid-dose group ( $p = .321$ ); 71% decrease of the intratendinous defect the low-dose group ( $p = .423$ ); and 225% increase of the intratendinous defect the high-dose group ( $p = .135$ ).

### Arthroscopic Outcomes

Arthroscopy before and 6 months after AD MSCs injection showed consistent findings with clinical and radiological outcomes. Macroscopically, regenerated tendon tissues were identified in all the 16 patients who underwent second-look arthroscopy regardless of tear location and size, and there was no case of tear enlargement (Fig. 5A, 5B, and Supporting Information Table S6). Regenerated tendon tissues appeared glossy white with smooth surface and felt firm with a probe similar to healthy tendon. No loose body, hypertrophy, mass or abnormal calcification was identified. Volumes of the articular-side defect in the mid-dose group and bursal-side defect in the high-dose group significantly decreased by 83% ( $p = .022$ ) and by 90% ( $p < .001$ ), respectively, at 6 months after injection. Nonsignificant decreases over 6 months included 17% ( $p = .423$ ) and 54% ( $p = .190$ ) decreases of the articular-side



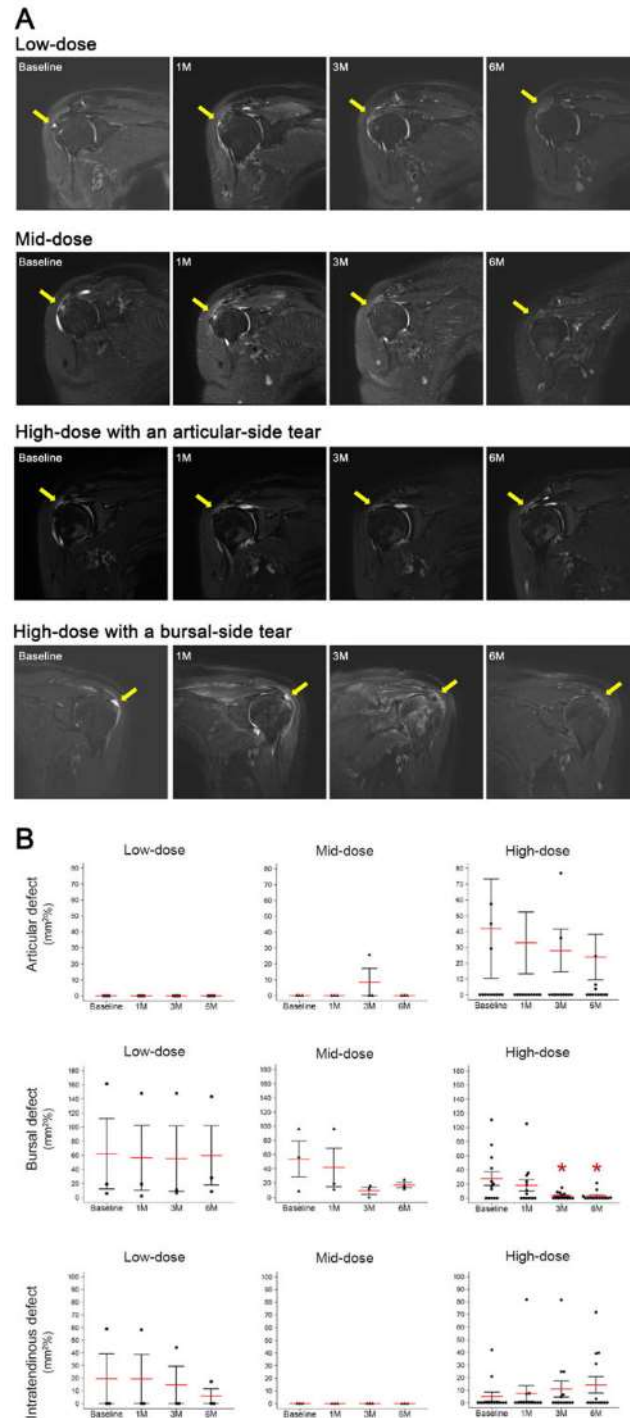
**Figure 3.** Clinical evaluation of the shoulder function during 6 months after intratendinous injection. **(A):** The SPADI score. **(B):** The Constant score. **(C):** The VAS pain on motion. \*,  $p < .05$ ; \*\*,  $p < .01$ , \*\*\*,  $p < .001$ . Abbreviations: SPADI, shoulder pain and disability index; VAS, visual analog scale.

defect in the low- and high-dose groups, respectively; 98% ( $p = .366$ ) and 100% ( $p = .208$ ) decreases of the bursal-side defect in the low- and mid-dose groups, respectively. As a gold standard assessment of rotator cuff disease, arthroscopic examination found associated lesions with rotator cuff tear (Supporting Information Table S7). Among them, subscapularis tear showed significant improvement after injection as 8 (62%) out of 13 patients had subscapularis tear before injection which was reduced to 1 (8%) after injection ( $p = .015$ ).

## DISCUSSION

This first-in-human clinical trial reached its predetermined primary outcomes. Intratendinous injection of AD MSCs for the

treatment of rotator cuff disease was not associated with adverse events. But, it significantly improved shoulder function measured with the SPADI and Constant scores beyond the minimal clinically important difference of both scores, approximately 20 and 10, respectively, in the mid- and high-dose groups [12,13]. Injection of AD MSCs also significantly alleviated shoulder pain with more than 70% reduction from the baseline in the high-dose group that is far beyond the clinically meaningful pain reduction of approximately 30%. MRI examination showed that volume of the bursal-side defect significantly decreased by 90% in the high-dose group. Arthroscopic examination demonstrated that volume of the articular- and bursal-side defects decreased by 83% in the mid-dose group, and 90% in the high-dose groups, respectively. Taken together, these results suggest that intratendinous injection of AD MSCs

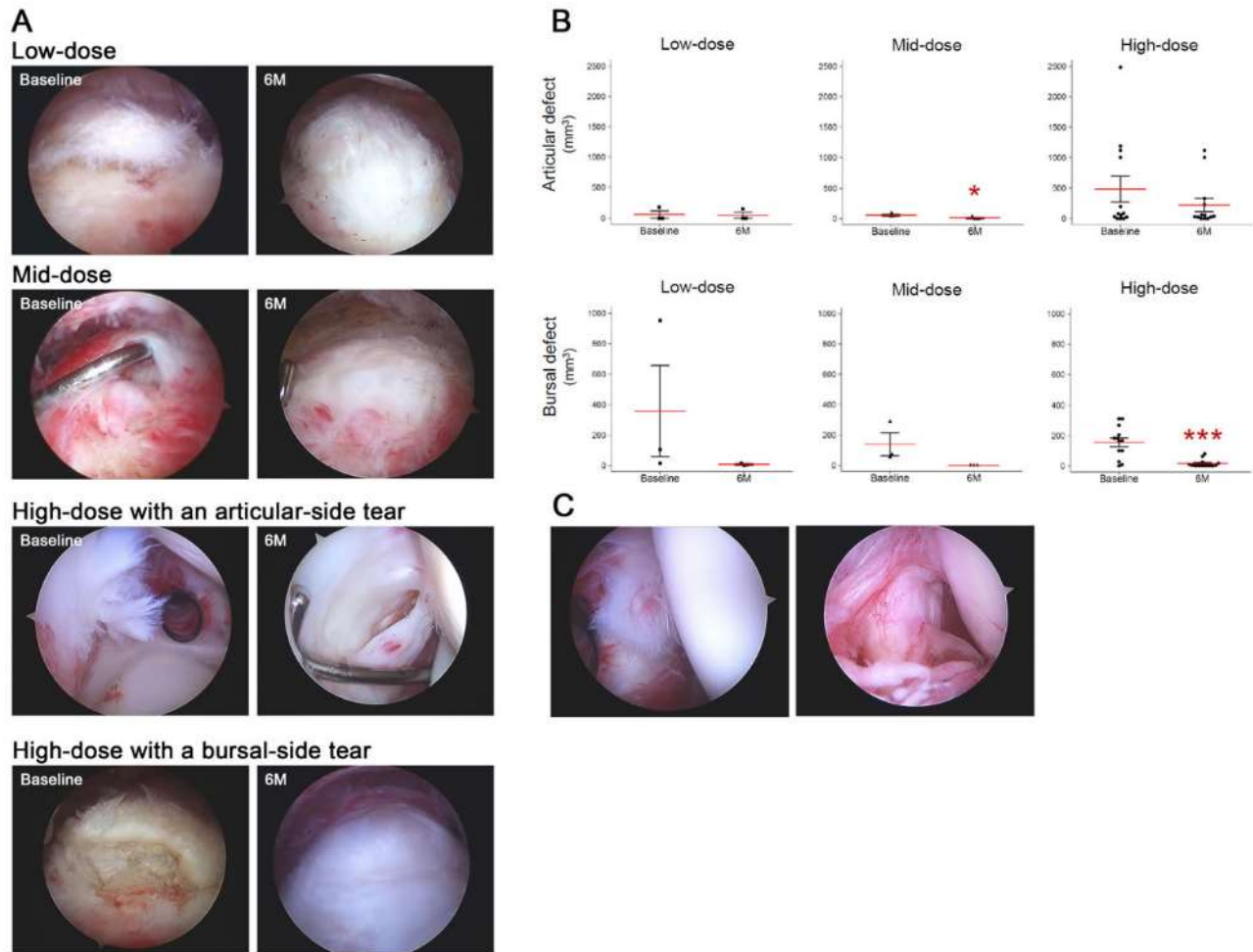


**Figure 4.** Radiological evaluation of tendon defect of rotator cuff during 6 months after intratendinous injection of adipose tissue-derived mesenchymal stem cells. **(A):** Oblique coronal magnetic resonance images. **(B):** Changes of the volume of tendon defects of articular- and bursal-side tear and intratendinous tear. The yellow arrows indicate tendon defects. \*,  $p < .05$ .

for the treatment of rotator cuff disease is safe, and effective with evidences of regeneration of tendon defect.

Whereas factors and fate related to tear progression have not been clearly elucidated, most studies demonstrated that rotator cuff disease progressed from tendinopathy to partial-thickness tear, and then eventually to fully-thickness tear whether it was symptomatic or not [14–16]. Progression of rotator cuff tear does not only mean the increase of the defect

size, but also results in the deterioration of the tendon quality, retraction degree, degeneration of rotator cuff muscles, local osteoporosis of the proximal humerus, and osteoarthritis of the glenohumeral joint [16–19]. Spontaneous healing of rotator cuff tear has been known to rarely occur [15,16]. Besides several in vivo studies that showed limited ability of rotator cuff for healing, clinical studies also have found limited spontaneous healing. Hyonen et al. reported that rotator cuff tears



**Figure 5.** Arthroscopic evaluation of tendon defect of rotator cuff during 6 months after intratendinous injection of adipose tissue-derived mesenchymal stem cells. **(A):** Arthroscopic view of tendon defect of rotator cuff tendon before and 6 months after injection. **(B):** Changes of the volume of tendon defects of articular- and bursal-side tear. **(C):** Arthroscopic view of the subscapularis tear before and 6 months after injection. \*,  $p < .05$ ; \*\*,  $p < .01$ , \*\*\*,  $p < .001$ .

were found 9 years after open acromioplasty in patients with impingement syndrome without tear at the time of surgery [20]. Weber reported no evidence of healing in patients treated with arthroscopic acromioplasty for partial-thickness rotator cuff tears with second-look arthroscopy [21]. Therefore, biological approaches, especially to furnish cells, for regeneration of tendon defect should be needed as degenerative torn end of rotator cuff would not contribute to healing. In this trial, we used autologous AD MSCs with proven safety [11]. Besides easiness of harvesting tissues in a large quantity with minimal invasiveness, one of the major strengths of AD MSCs is that they are less influenced by age or morbidity of patients in contrast to bone marrow MSCs or tendon stem/progenitor cells [22]. In addition, several experimental studies showed that AD MSCs prevented progression of tendon degeneration [10], increased the tensile strength and type I collagen in tendon repair [23], decreased fatty infiltration of muscle after repair [24], decreased tendon defects in human lateral epicondylitis [25], and reduced the re-injury rate in race horses [26]. While a recent systematic review reported no evidence for the use of stem cell therapy for tendon disorders currently [27], all of the two studies for rotator cuff tear in this review actually

did not use MSCs, but use bone marrow mononuclear cells between which there should be a huge gap. We find no clinical trial using injection of AD MSCs for rotator cuff disease in the literature so far. To our knowledge, there is one case series so far that reported effects of MSCs on rotator cuff disease [28]. In eight patients who undergoing arthroscopic rotator cuff repair, Havlas reported that autologous bone marrow MSCs application was safe, improved pain and function of the affected shoulder, and showed healing in MRI examination at 6 months after surgery. Meanwhile, this study provides the efficacy with clinical, radiological, and arthroscopic evidences of intratendinous injection of AD MSCs for the treatment of rotator cuff disease. Especially, using 2nd look arthroscopy, the gold standard of rotator cuff tear examination, this study showed that tear size decreased after AD MSCs injection in almost patients regardless of tear location and there was no case of tear enlargement.

Two major mechanisms of MSCs for regeneration are known to be direct differentiation and paracrine effects [29]. While serial MRI and arthroscopic evaluation of this study clearly showed that intratendinous injection of AD MSCs regenerated the tendon defect, the exact mechanism behind this is yet to be elucidated.



Meanwhile, we unexpectedly observed healing of the subscapularis tear located in the articular space in 7 out of 8 patients (88%) after AD MSCs injection. Cells were injected only into the supraspinatus and infraspinatus tendon through the subacromial (or bursal) approach under ultrasonographic guidance. Thus, even if injected cells leaked out of tendon, they would be more likely in the subacromial space rather than in the articular space. Furthermore, considering that some authors reported high initial cell loss up to 75% over 24 hours after intratendinous injection [30], minimal number of injected cells could be directly engrafted to the subscapularis tear for direct differentiation. This finding suggests the evidence and importance of paracrine effects in tendon regeneration, at least for the subscapularis tear of patients in this study. Nevertheless, further studies are necessary with respect to contribution and conditions of each mechanism.

There are several limitations of the study. First, the weaknesses inherent to the early phase clinical trial such as small sample size, the absence of the control group, no randomization, and short follow-up all of which would be drawbacks in finding efficacy of the treatment via statistical significance of the treatment. Nonetheless, as the first-in-human study, findings in this study would be promising encouraging subsequent larger scale clinical trials. Second, no histological evaluation of the regenerated tissue despite glossy, white and smooth with running strands of fibers resembling healthy tendon via arthroscopic examination. Third, additional evaluation of adjacent tissues including rotator cuff muscles, proximal humerus, and articular cartilage of the glenohumeral joint would be necessary in the longer-term study. And last, we did not examine tenogenic differentiation potentials of AD MSCs used in the study simultaneously.

## CONCLUSION

This first-in-human clinical trial reached its predetermined primary outcomes. Intratendinous injection of AD MSCs for In

conclusion, this study provides the proof-of-concept that intratendinous injection of AD MSCs is feasible, safe, and capable of regenerating tendon defect which, in turn, results in the improvement of function and pain of shoulder in a patient with rotator cuff disease. The findings of this study are sufficiently promising to perform larger randomized trials.

## ACKNOWLEDGMENTS

We thank the study participants for support of this trial. The authors are also deeply appreciative for the assistance provided by Jae Min Lee, Eun Mi Ahn, Mi Hye Baek, Tae Ri Lee, Ji Tae Jeong, Sung Yeon Won, Hanna Shim, and Ji Sun Shin, who contributed to the successful completion of this study. This research was supported by a grant (HI14C2748) of the Korea Health Technology R&D Project through the Korea Health Industry Development Institute and a grant (NRF-2015M3A9E6028412) of the Bio & Medical Technology Development Program of the National Research Foundation of Korea.

## AUTHOR CONTRIBUTIONS

C.H.J.: conception and design, data analysis and interpretation, manuscript writing, final approval of manuscript; J.W.C. and S.O.: data analysis and interpretation, final approval of manuscript; E.C.J.: provision of study material or patients, final approval of manuscript; P.S.K. and J.Y.Y.: administrative support, collection and/or assembly of data, final approval of manuscript; K.S.Y.: conception and design, final approval of manuscript.

## DISCLOSURE OF POTENTIAL CONFLICTS OF INTEREST

The authors indicated no potential conflicts of interest.

## REFERENCES

- 1 Urwin M, Symmons D, Allison T et al. Estimating the burden of musculoskeletal disorders in the community: The comparative prevalence of symptoms at different anatomical sites, and the relation to social deprivation. *Ann Rheumat Dis* 1998;57:649–655.
- 2 Choi K, Park JH, Cheong HK. Prevalence of musculoskeletal symptoms related with activities of daily living and contributing factors in Korean adults. *J Prev Med Public Health* 2013;46:39–49.
- 3 Colvin AC, Egorova N, Harrison AK et al. National trends in rotator cuff repair. *J Bone Joint Surg Am* 2012;94:227–233.
- 4 Hermans J, Luime JJ, Meuffels DE et al. Does this patient with shoulder pain have rotator cuff disease?: The Rational Clinical Examination systematic review. *JAMA* 2013;310:837–847.
- 5 van der Windt DA, Koes BW, Boeke AJ et al. Shoulder disorders in general practice: Prognostic indicators of outcome. *Br J Gen Pract* 1996;46:519–523.
- 6 Coombes BK, Bisset L, Vicenzino B. Efficacy and safety of corticosteroid injections

and other injections for management of tendinopathy: A systematic review of randomised controlled trials. *Lancet* 2010;376:1751–1767.

7 Zhang J, Keenan C, Wang JH. The effects of dexamethasone on human patellar tendon stem cells: Implications for dexamethasone treatment of tendon injury. *J Orthop Res* 2013;31:105–110.

8 Gaspar D, Spanoudes K, Holladay C et al. Progress in cell-based therapies for tendon repair. *Adv Drug Deliv Rev* 2015;84:240–256.

9 Docheva D, Muller SA, Majewski M et al. Biologics for tendon repair. *Adv Drug Deliv Rev* 2015;84:222–239.

10 Carvalho A, D M, Badial P, Álvarez LEC et al. Equine tendonitis therapy using mesenchymal stem cells and platelet concentrates: A randomized controlled trial. *Stem Cell Res Ther* 2013;4:85.

11 Jo CH, Lee YG, Shin WH et al. Intra-articular injection of mesenchymal stem cells for the treatment of osteoarthritis of the knee: A proof-of-concept clinical trial. *Stem Cells* 2014;32:1254–1266.

12 Ekeberg OM, Bautz-Holter E, Keller A et al. A questionnaire found disease-specific

WORC index is not more responsive than SPADI and OSS in rotator cuff disease. *J Clin Epidemiol* 2010;63:575–584.

13 Kukkonen J, Kauko T, Vahlberg T et al. Investigating minimal clinically important difference for Constant score in patients undergoing rotator cuff surgery. *J Shoulder Elbow Surg* 2013;22:1650–1655.

14 Jo CH, Shin WH, Park JW et al. Degree of tendon degeneration and stage of rotator cuff disease. *Knee Surg Sports Traumatol Arthrosc* 2017;25:2100–2108.

15 Mall NA, Kim HM, Keener JD et al. Symptomatic progression of asymptomatic rotator cuff tears: A prospective study of clinical and sonographic variables. *J Bone Joint Surg Am* 2010;92:2623–2633.

16 Tashjian RZ. Epidemiology, natural history, and indications for treatment of rotator cuff tears. *Clin Sports Med* 2012;31:589–604.

17 Hebert-Davies J, Teefey SA, Steger-May K et al. Progression of fatty muscle degeneration in atraumatic rotator cuff tears. *J Bone Joint Surg Am* 2017;99:832–839.

18 Oh JH, Song BW, Kim SH et al. The measurement of bone mineral density of bilateral proximal humeri using DXA in patients with

unilateral rotator cuff tear. *Osteoporos Int* 2014;25:2639–2648.

**19** Chalmers PN, Salazar DH, Steger-May K et al. Radiographic progression of arthritic changes in shoulders with degenerative rotator cuff tears. *J Shoulder Elbow Surg* 2016;25:1749–1755.

**20** Hyvonen P, Lohi S, Jalovaara P. Open acromioplasty does not prevent the progression of an impingement syndrome to a tear. Nine-year follow-up of 96 cases. *J Bone Joint Surg Br* 1998;80:813–816.

**21** Weber SC. Arthroscopic debridement and acromioplasty versus mini-open repair in the treatment of significant partial-thickness rotator cuff tears. *Arthroscopy* 1999;15:126–131.

**22** Veronesi F, Della Bella E, Torricelli P et al. Effect of adipose-derived mesenchymal stromal cells on tendon healing in aging and

estrogen deficiency: An in vitro co-culture model. *Cytotherapy* 2015;17:1536–1544.

**23** Uysal AC, Mizuno H. Tendon regeneration and repair with adipose derived stem cells. *Curr Stem Cell Res Ther* 2010;5:161–167.

**24** Oh JH, Chung SW, Kim SH et al. 2013 Neer Award: Effect of the adipose-derived stem cell for the improvement of fatty degeneration and rotator cuff healing in rabbit model. *J Shoulder Elbow Surg* 2014;23:445–455.

**25** Lee SY, Kim W, Lim C et al. Treatment of lateral epicondylitis by using allogeneic adipose-derived mesenchymal stem cells: A pilot study. *Stem Cells* 2015;33:2995–3005.

**26** Ricco S, Renzi S, Del Bue M et al. Allogeneic adipose tissue-derived mesenchymal stem cells in combination with platelet rich plasma are safe and effective in the therapy of superficial digital flexor tendonitis in the

horse. *Int J Immunopathol Pharmacol* 2013; 26:61–68.

**27** Pas H, Moen MH, Haisma HJ et al. No evidence for the use of stem cell therapy for tendon disorders: A systematic review. *Br J Sports Med* 2017;51:996–1002.

**28** Havlas V, Kotaska J, Konicek P et al. [Use of cultured human autologous bone marrow stem cells in repair of a rotator cuff tear: Preliminary results of a safety study]. *Acta Chir Orthop Traumatol Cech* 2015;82:229–234.

**29** Liang X, Ding Y, Zhang Y et al. Paracrine mechanisms of mesenchymal stem cell-based therapy: Current status and perspectives. *Cell Transplant* 2014;23:1045–1059.

**30** Smith RK, Werling NJ, Dakin SG et al. Beneficial effects of autologous bone marrow-derived mesenchymal stem cells in naturally occurring tendinopathy. *PLoS One* 2013;8:e75697.



See [www.StemCells.com](http://www.StemCells.com) for supporting information available online.