

**Effectiveness of Dextrose Prolotherapy for Rotator Cuff Tendinopathy: A Systematic Review**

**Running Title:** Prolotherapy for Rotator Cuff: A Systematic Review

Authors: Michael Catapano MD<sup>1</sup>, Kailia Zhang BHSc<sup>2</sup>, Nimish Mittal MBBS MD<sup>1</sup>, Harpreet Sangha MD, FRCPC<sup>1</sup>, Kentaro Onishi DO<sup>3</sup>, Darren de SA MD, FRCSC<sup>4</sup>

Author Affiliations:

1. Division of Physical Medicine & Rehabilitation, Department of Medicine, University of Toronto, Toronto, Ontario, Canada
2. Michael G. DeGroot School of Medicine, McMaster University, Hamilton, Ontario, Canada
3. UPMC Center for Sports Medicine, 3200 S. Water St, Pittsburgh, PA, 15203, USA.
4. Division of Orthopaedic Surgery, Department of Surgery, McMaster University, Hamilton, Ontario, Canada

Corresponding Author:

Michael Catapano MD

University of Toronto

190 Elizabeth Street

Toronto, Ontario, Canada M5G 2C4

This article has been accepted for publication and undergone full peer review but has not been through the copyediting, typesetting, pagination and proofreading process which may lead to differences between this version and the Version of Record. Please cite this article as doi: 10.1002/pmrj.12268

Michael.Catapano@mail.utoronto.ca

Disclaimers: None

## **Abstract**

*Objective:* To systematically review and evaluate the efficacy and complication profile of prolotherapy using hyperosmolar dextrose solution injection for rotator cuff tendinopathy.

*Literature Survey:* MEDLINE, EMBASE, CINAHL, and the Cochrane Central Register of Controlled Trials (from inception to July 1<sup>st</sup>, 2019).

*Methodology:* A comprehensive search was completed to identify randomized controlled trials addressing prolotherapy using hyperosmolar dextrose solution for rotator cuff tendinopathy. Two reviewers independently screened the titles, abstracts, and full texts, and then extracted data from eligible studies. All reported outcome measures and complications were analyzed descriptively.

*Synthesis:* Five studies satisfied inclusion criteria. Included studies analyzed a total of 272 participants with a final follow-up ranging 6-weeks to 12-months. Prolotherapy differed greatly among studies. Two studies used a multi-site entheses injection protocol while the other three used ultrasound-guided protocols. Two of the studies used an intra-substance supraspinatus injection and three a supraspinatus entheses injection. Control groups consisted of non-operative rehabilitation including physical therapy and medical management in three studies, supraspinatus saline entheses injection in one study, and corticosteroid injection in one study. There was

statistically significant improvement in pain intensity with multi-site injection protocols compared to physical therapy and medical management in both studies. Ultrasound-guided supraspinatus injection trials did not find any statistically significant difference in pain intensity, range of motion, strength, function or ultrasound characteristics compared to controls of enthesitis saline injection or corticosteroid. The complication rate was low with only 6/272 participants experiencing adverse events consisting of transient increase in pain for 1-2 days post-intervention.

*Conclusion:* Prolotherapy with hyperosmolar dextrose solution is a potentially effective adjuvant intervention to physical therapy for patients with rotator cuff tendinopathy ranging from tendinosis to partial thickness and small full-thickness tears. Further studies are necessary to determine effects in sub-populations as well as optimal technique including dextrose concentration, volume, and location.

*Key Words:* Prolotherapy, Rotator cuff tendinopathy, Non-operative

*Abbreviations:* visual analog score = VAS

## Introduction

Rotator cuff tendinopathy is one of the most common musculoskeletal conditions and the most common shoulder pathology affecting 15-50% of the population and increasing in prevalence with age<sup>1-4</sup>. It is a unique challenge for physicians as it presents with a wide range of pathologies which only loosely correlate to symptoms. Rotator cuff tendinopathy pathology can range from tendinosis, calcific tendinitis, partial and full thickness tears, and large and massive irreparable rotator cuff tears affecting any combination of the four rotator cuff tendons. Those with milder disease including tendinosis, calcific tendinitis, and partial thickness tears typically report a predominance of pain with some degree of weakness and/or loss of range of motion with associated functional limitations<sup>1-4</sup>. The optimal treatment for rotator cuff tendinopathy remains unknown. A multitude of non-operative, interventional and surgical procedures have been proposed to address this issue however there has yet to be a definitive treatment. Treatment that begins with physical therapy supplemented with pain control in the form of oral analgesics and/or steroid injection, followed by progression to surgical management is often recommended. However, recent evidence suggests that the effectiveness of non-operative treatments are limited by disease reoccurrence due to their inability to simulate intrinsic tendon healing and repeat steroid injections may have deleterious effects on tendon integrity or future surgical repair<sup>5,6</sup>. In addition, surgical interventions for milder disease are limited by variable outcomes, high failure rates, and unpredictable functional restoration and pain relief<sup>7-10</sup>.

Prolotherapy, through the injection of hyperosmolar dextrose solution, was first used in the 1950s to treat ligamentous laxity and related musculoskeletal and arthritic conditions due to its ability to stimulate healing and fibrosis<sup>11,12</sup>. Within the last 10 years, there has been an emergence of evidence for prolotherapy for rotator cuff tendinopathy using various injection protocols and techniques to strengthen rotator cuff tendinous structures, repair tendinous defects or eliminate pain stimuli<sup>12-14</sup>. Initial reports described a landmark-based technique targeting all tendon insertion sites surrounding the shoulder girdle and repeating weekly for several weeks. However, as the use of musculoskeletal ultrasound has increased, more accurate injection techniques to target these tendon insertion sites have emerged. Currently, there is lack of high-quality evidence and no consensus regarding dextrose concentration, volume of injection, number of injection sites or injection protocols for rotator cuff tendinopathy. Therefore, the objective of this systematic review is to examine the clinical outcomes and complications of dextrose prolotherapy as a treatment of rotator cuff tendinopathy.

## Methods

This systematic review was performed following the PRIMSA (Preferred Reporting Items for Systematic Reviews and Meta-analyses) guidelines<sup>15</sup>.

### Search Strategy

MEDLINE, EMBASE, CINAHL, and the Cochrane Central Register of Controlled Trials were searched from database inception to July 1<sup>st</sup>, 2019 for randomized controlled trials addressing dextrose prolotherapy injection for rotator cuff tendinopathy. The search terms “prolotherapy” or “dextrose” and “rotator cuff tear” or “impingement syndrome” were used.

### Assessment of Study Eligibility

Studies were included if they were randomized clinical trials that reported outcomes after dextrose prolotherapy for rotator cuff tendinopathy. Studies classified as reviews, editorials, technique papers, studies of animal models or cadaveric studies were excluded.

### Study Screening and Data Abstraction

Systematic article screening and data abstraction were performed independently and in duplicate by two authors. Throughout the title and abstract screening stages, any article with discordance between reviewers was included to ensure that no relevant articles were prematurely excluded. The reviewers discussed any disagreements at the full text stage and if consensus was not reached, a third reviewer provided input regarding each article’s eligibility. The reference lists of all included studies were screened for additional relevant articles. The data extracted included number of patients, sex, injection regimens, injection techniques, treatment interval, and

adverse effects. Raw data for continuous outcome measures were extracted at all reported follow-up times (if available), including means and SDs.

Unweighted kappa ( $\kappa$ ) and 95% confidence intervals (CI) were calculated for the title, abstract and full text screening stages. Kappa values  $>0.61$  indicate substantial agreement;  $0.21 < \kappa < 0.60$ , to indicate moderate agreement; and  $\kappa < 0.20$ , to indicate slight agreement<sup>16</sup>. Data abstraction was performed in duplicate.

### Quality Assessment

The quality of included studies was assessed using the Cochrane Collaboration's Risk of Bias tool in Review Manager Software. No scoring system was adopted; rather, quality assessments were used for descriptive purposes. The risk of bias assessment was performed in the following domains: random sequence generation; allocation concealment; blinding of participants and personnel and outcome assessors; blinding of outcome assessment; incomplete outcome data; and selective reporting. An additional domain, categorized as other, was used where any important concerns about bias not addressed in the above-mentioned domains could be documented. Risk of bias assessments were performed by authors not involved in study screening, data abstraction or analysis.

### Statistical Analysis

Descriptive statistics were extracted for all reported outcomes. All outcomes were abstracted and described individually. Due to heterogenous intervention techniques with variable reporting of outcome measures at various time periods, it was decided not to perform meta-

analysis on any outcomes as there were only 2 studies with outcome measures using a specific interventional technique at any given time-point<sup>17</sup>.



## Results

### Study Characteristics and Demographics

The original search yielded 570 results after duplicates were removed. Following the title screen, 74 studies were included in abstract screening, of which 24 progressed to full text review. A total of 20 studies were removed by the full text review, leaving four papers to be included for analysis (Figure 1)<sup>18-22</sup>. One additional article was retrieved through manual reference search of included studies. Authors were in high agreement throughout all stages of screening, with an unweighted kappa of 0.962 for title screening, 0.760 for abstract screening and 1.00 for full text screening. All included studies were randomized controlled trials by design. Two studies used a multi-site repeat injection protocol including one study of repeated landmark-based multiple site entheses injections surrounding the shoulder compared to physiotherapy +/- sham intervention and one study of ultrasound-guided multiple site entheses injections compared to physiotherapy. While three studies used a one-time single site injection including one study of a one-time single site supraspinatus entheses injection compared to supraspinatus entheses injection of saline, one study of a one-time single site supraspinatus intra-substance injection compared to physiotherapy, and one study of a one-time single site supraspinatus intra-substance injection compared to sub-acromial corticosteroid injection. The sample size of the included studies ranged from 12-120 patients with a pooled total of 272 patients with rotator cuff tendinopathy included. The mean age of the included patients ranged from 48 to 59 years old across studies. Final follow-up ranged from 1.5 to 12-months post-intervention (Table 1).

### Included studies

Bertrand et al conducted a double-blind randomized controlled trial of 73 patients with chronic, moderate to severe shoulder pain secondary to ultrasound-confirmed rotator cuff tendinopathy for an average disease duration of 7.6+/-9.6 years. Participants were randomized into three separate groups consisting of injection of 25% dextrose into 9 entheses surrounding the shoulder girdle using a landmark-based technique, injection of normal saline into the same entheses surrounding the shoulder girdle or superficial injection of normal saline into the soft-tissue overlying these entheses (table 2). Patients were evaluated at baseline, 3-months and 9-months after injection for changes in pain intensity using the visual analog scale (VAS) as well as an ultrasonographic tendon structure using an Ultrasound Shoulder Pathology Rating Scale which evaluated biceps tendinopathy, supraspinatus tendinopathy, greater tuberosity cortical surface, dynamic supraspinatus impingement and dynamic subscapularis/biceps/coracoid impingement. Patients received repeat interventions at 1 and 2 months after intervention. Only one patient was lost to follow-up in the entheses saline group due to the development of adhesive capsulitis during the treatment period. At the end of 9 months, there was a 2.9+/-0.6, 1.8+/-0.7 and 1.3+/-0.6 reduction in pain intensity in the entheses dextrose, entheses saline and superficial saline groups, respectively. A statistically significant difference was noted between the entheses dextrose and superficial saline group and not between the entheses dextrose and entheses saline groups. Minimal, 0.3+/-0.5 to 0.6+/-0.4, reduction was noted in all three groups in the Ultrasound Shoulder Pathology Rating Scale at final follow-up. Authors concluded that there

was a superior improvement in long-term pain with dextrose entheses injection with moderate improvement with entheses saline injection.

Seven et al conducted an open-label randomized controlled trial of 120 patients comparing ultrasound-guided entheses injections surrounding the shoulder compared to a supervised home physiotherapy and exercise program. Entheses injections included ultrasound-guided subacromial injection of 4mL of 25% dextrose plus up to 20mL of 15% dextrose in entheses surrounding the shoulder. Patients were offered repeat injections for up to a maximum of 6 injections which were stopped once there was greater than 75% pain reduction or when the patient decided to withdraw from repeat injections. Patients were asked to report pain intensity on a VAS scale, function using the Western Ontario Rotator Cuff Index (WORC) and the Shoulder Pain and Disability Index (SPADI), and be evaluated for active range of motion by an outcome assessor blinded to patient allocation at baseline, 3-weeks, 6-weeks, 12-weeks and 12-months after intervention. Nineteen patients, sixteen in the control group and three in the prolotherapy group, were lost to follow up due to adverse events, dissatisfaction or incomplete data. Patients receiving prolotherapy demonstrated statistically significant improvements compared to controls in pain intensity on a VAS scale, function as measured by the WORC and SPADI, and internal rotation, abduction and flexion range of motion ( $p < 0.05$ ) (table 2).

George et al conducted an open-label randomized controlled trial of a one-time ultrasound-guided single site injection of 0.5-10mL of 12.5% dextrose and 0.5% lidocaine into a focal area of tendinosis in the supraspinatus tendon plus physiotherapy compared to conventional

Accepted Article

physiotherapy in those with focal supraspinatus tendinosis including tendinosis, calcific tendinitis, and partial thickness tears. Those with dynamic impingement on ultrasound and full-thickness tears were excluded. All patients received the same amount of physiotherapy post-randomization. Twelve patients were randomized using a random-digit analyzer, with seven randomized to prolotherapy and five randomized to physiotherapy. Patients completed functional assessment using the Disabilities of the Arm, Shoulder and Hand (DASH) validated questionnaire and underwent ultrasound evaluations at baseline and 12-weeks post-intervention. There was a significant improvement in abduction active range of motion from baseline to 12-weeks in the prolotherapy group compared to those undergoing only physiotherapy with a 20 degree improvement compared to 12 degrees reduction in range of motion, respectively, ( $p=0.03$ ) while forward flexion, extension, internal rotation and external rotation did not show any significant difference between groups. In addition, while there were improvements seen in both groups when comparing baseline to 12-week follow-up, there was no significant difference between groups in the improvements in the mean DASH function score, pain score, or ultrasound characteristics at 12-week follow-up.

Lin et al conducted a double-blind randomized controlled trial comparing a one-time ultrasound-guided single site injection of 20% dextrose into the supraspinatus enthesis to injection of 5% normal saline into the supraspinatus enthesis. Concomitant exercise intervention was not controlled for or reported in either group. Thirty-one patients were randomized and all randomized patients received the appropriate intervention according to randomization. There was

no patients lost to follow-up and all patients had pain intensity measured by a VAS, function as assessed by the SPADI, and range-of-motion and ultrasound characteristics of the supraspinatus including thickness and echogenicity measured at baseline, 2-weeks and 6-weeks post-intervention. At 6-week follow-up, there was no significant difference in any measured outcome within groups or between cases and controls.

Cole et al conducted a double-blind randomized trial of thirty-six patients randomized to either ultrasound-guided injection of 25% dextrose prolotherapy into the hypochoic/anechoic area of the supraspinatus tendon or ultrasound-guided subacromial injection of 40mg methylprednisolone. All included patients received a post-injection protocol consisting of reduced physical activity and lifting for 2 weeks followed by a home physiotherapy protocol with review of techniques and adherence at 6-week and 3-month follow-up. At 6-week, 3-month and 6-month follow-up patients were assessed using a 5-point Likert scale (very severe, severe, moderate, mild or none) to assess pain intensity with overhead activities, pain intensity at night, frequency of night pain, and overall satisfaction with treatment. Patients' range of motion, impingement tests, and shoulder strength was measured in addition to ultrasound evaluation of the supraspinatus tendon. There was a statistically significant improvement in impingement signs, pain with overhead activities, frequency of night pain, overall shoulder satisfaction, ultrasound appearance, forward flexion range of motion and supraspinatus strength at 6 months post intervention compared to baseline in both groups (table 2). However, no significant between group differences were noted at final follow-up of any included outcome.

### Complications of Prolotherapy Injection

The complication rate in the included studies was low with 2.3% of participants reporting complications. Only transient adverse events were reported including increased pain for 1-2 days after injection, superficial burns due to improper use of heat post-procedure and local anesthetic effect of the injections.

### Risk of Bias Assessment

The risk of bias summary and graph is presented in figure 2 and figure 3. All studies, except Seven et al and George et al, were rated as a low risk of bias in terms of incomplete outcome data due to low loss to follow-up. Seven et al and George et al were rated as high-risk of incomplete outcome data bias due to high loss to follow-up rate among the control group (>20%) which was more than 10% larger lost to follow-up rate than the intervention group in both studies. All studies, except George et al, were rated as low risk of bias in terms of random sequence generation and outcome assessment bias with blinded outcome assessors and appropriate randomization techniques. George et al had high risk of bias due to non-blinded outcome assessors and odd-even random allocation. In addition, George et al had high risk of selective reporting bias due to incomplete reporting with missing baseline demographics, outcomes and standard deviations despite being registered while the majority of studies demonstrated unclear risk of selective report as only one study had a published study protocol. In addition, only one study clearly described the concealment process while two studies did not clearly state concealment methods and two studies demonstrated no allocation concealment.

Three studies had high risk of bias based on non-blinding of interventionalist +/- participants while two studies had low risk of bias. Two studies were open-label with a high risk for patient ascertainment bias due to non-blinding of interventionalists, patients, and personnel and one was high risk for co-intervention bias with additional tendon needling in only the intervention group.

## Discussion

This study suggests that dextrose prolotherapy for rotator cuff tendinopathies demonstrates, at least in the short-term, the potential to result in improvements in pain, range of motion and function in those with chronic rotator cuff tendinopathy. However, there was a high-risk of bias among the majority of included studies and significant variability in efficacy was demonstrated which may be due to high-risk of bias, differences in included pathologies and heterogenous patient populations, technique and injection protocols, control groups or follow-up periods. Repeat multi-site landmark injection protocols demonstrated more consistent improvements and increased promise for long-term effectiveness compared to one-time single-site image-guided injections. Additional research is needed to better elucidate the specific patient population with rotator cuff tendinopathy who benefit from prolotherapy as well as optimize the technique including number and time period of repeat injections, volume and concentration of dextrose solution and location of injection.

Study protocols varied significantly, however studies with repeat multi-site injection protocols compared to conservative therapy consisting of home or supervised physiotherapy demonstrated consistent improvement that surpasses the minimal clinically important difference (MCID) for the VAS score of 1.4<sup>23</sup> in patients with rotator cuff tendinopathy compared to controls. In addition, Seven et al reported significant improvements in range of motion and function, which was not assessed by Bertrand et al. In contrast, those with one-time single site injection compared to either physiotherapy, sub-acromial injection or enthesis injection of saline demonstrated no significant improvements in any measured outcomes of pain and function while only one found



improvements in range of motion. Multiple methodological differences may account for some of this variability. One large difference in methodology is that the majority of those enrolled in one-time single-site injections were compared to active interventions of entheses saline, which has demonstrated some efficacy in the Bertrand et al study, and subacromial corticosteroid injection, which has previously demonstrated efficacy in rotator cuff tendinopathy<sup>11,24-26</sup>. Another methodological difference is those included in one-time-single site injection studies tended to have milder baseline pain with lower pain intensity scores and improved baseline function with low SPADI scores and more active range of motion. Despite these methodological differences, repeat multi-site dextrose prolotherapy protocols demonstrated larger absolute improvements in VAS, SPADI and range of motion.

Bertrand et al and Seven et al, although both demonstrating improvement, had significantly different levels of improvement in pain intensity scores of 1.6 versus 3.0 compared to controls, respectively. The variability in outcome between these studies may be explained by the subtle differences in injection protocols including ultrasound-guidance and addition of subacromial injection in Seven et al. Previous studies of ultrasound-guidance has reported significant improvements compared to land-mark technique in multiple conditions including CRT, large joint injections and carpal tunnel syndrome<sup>27-31</sup>. Multiple studies have cited the development of subacromial bursitis as the pain generator in rotator cuff tendinopathies with targeted injection providing significant relief without demonstrating intrinsic tendon healing<sup>30,32,33</sup>, the addition of co-intervention in the form of subacromial bursal injection in Seven et al may account for a

Accepted Article

proportion of the improved efficacy demonstrated. Patients in the Seven et al study were not blinded to treatment as in the Bertrand et al study and this significant increase in potential bias may also account for a proportion of the apparent improved efficacy of intervention. Although multi-site injection protocols demonstrated significant improvements in pain intensity, and potentially range of motion and function, future studies are needed to validate results and optimize technique.

Several studies have demonstrated that physical therapy alone results in significant improvement in those with impingement syndrome/tendinosis as well as full-thickness tears. As such, dextrose prolotherapy demonstrates a statistically significant improvement in pain and function when added to standard of care physical therapy with a mean improvement of 1.6-3.0, 9.1-33.4, and 27.9-point for the pain VAS, SPADI and WORC, respectively. These all demonstrate both clinically and statistically significant improvements with minimal clinically important difference (MCID) defined as 1.4-points<sup>23,34-36</sup>, 8-points<sup>37</sup>, and 14.3<sup>38,39</sup> for the VAS, SPADI and WORC, respectively. The benefit demonstrated with the use of dextrose prolotherapy in addition to physical therapy makes prolotherapy a viable adjunct to maximize the benefit of physical therapy. Nevertheless, no studies evaluated dextrose prolotherapy without physical therapy and it is unknown whether prolotherapy has utility as a monotherapy or only as a combination therapy. In addition, both studies were unclear regarding previous physical therapy and it is unknown whether dextrose prolotherapy should be used at the initiation of physical therapy or only once a course of physical therapy has been tried.

Cole et al demonstrated that those receiving intra-substance dextrose prolotherapy to the supraspinatus tendon improved similarly to subacromial corticosteroid injection over a 6 month period. In both groups of patients there were no deleterious effects on tendon structure and, in fact, both groups demonstrated significant improvements in ultrasound characteristics of the supraspinatus tendon. Both groups demonstrated significant improvement in pain, range of motion, strength, and impingement signs compared to baseline measures at 6 months. Although both groups improved similarly, previous studies of corticosteroid demonstrate a short-term benefit however significant disease recurrence by 1-year follow-up<sup>11,25,27,40</sup>. Due to the significant variation between the one-time single-site injection and repeat multi-site injection protocols utilized, it is unknown whether patients receiving dextrose prolotherapy would continue to improve or maintain their improvements at 1 year as seen in Seven et al and Bertrand et al. However, there is potential, based on the proposed mechanism of dextrose and results of repeat multi-site injection protocols that patients may continue to improve or merely maintain their improvements at a 1 year follow-up while those with corticosteroid will have significant disease recurrence<sup>11,25,27,40</sup>.

Recently there has been concern regarding subacromial corticosteroid injection for rotator cuff tendinopathies and its effects on tendon integrity<sup>41-44</sup>, long-term disease recurrence and progression<sup>41-44</sup> and effect on future surgical intervention<sup>5,6,45</sup>. Corticosteroid is thought to cause cellular apoptosis and alteration in collagen synthesis which ultimately weakens and can rupture tendons<sup>41,45</sup>, reduce immunological response<sup>41,45</sup>, and reduce the success of future surgical repairs

Accepted Article

by delaying or inhibiting healing<sup>5,6,45,46</sup>. Due to the small number of patients receiving dextrose prolotherapy in the included studies, it is difficult to speculate on the occurrence and effect of prolotherapy on tendon integrity, long-term disease recurrence and effect on future surgical intervention. Based on the biologic action of dextrose, which is thought to aid in the regeneration of tendons and ligaments<sup>47</sup> and have an increased immunologic response<sup>12,47</sup>, it is likely that these adverse events are not reported with dextrose prolotherapy as there is a reduced likelihood for deleterious effects on tendon integrity or future surgical intervention<sup>48</sup>. These biological differences between dextrose prolotherapy and corticosteroid may allow for the replacement of adjuvant corticosteroid injections with prolotherapy in the future. However, larger, population studies are needed to determine the true incidence of these long-term major adverse events and the effectiveness of prolotherapy compared to corticosteroid.

There are no direct comparisons of platelet-rich plasma to dextrose prolotherapy as a single therapy or an adjunct to physical therapy, however both interventions have been theorized to assist in rotator cuff tendinopathy through tissue remodelling and healing<sup>49,50</sup>. A recent systematic review of controlled studies of platelet-rich plasma as an adjunct to physical therapy for rotator cuff tendinopathy demonstrated no significant improvements at any follow up point over a 12-month period<sup>51</sup>. In addition, one randomized controlled study of single platelet-rich plasma injection without physical therapy compared to just physical therapy demonstrated significant improved function and range of motion at 1 and 3 months in the therapy group however no difference at 6-month final follow-up<sup>51</sup>. This trend can also be seen in a randomized controlled trial of platelet-

rich plasma compared to dry needling of the rotator cuff tendons were no significant difference was seen in pain scores, disability measures or range of motion<sup>51</sup>. Although results for both interventions are limited and there continues to be significant variability between preparations, injection techniques and protocols in both interventions, dextrose prolotherapy appears to be more promising, due to ease of injection, cost, and improved outcomes as an adjuvant to physical therapy.

Comparison of dextrose prolotherapy to operative interventions is difficult as operative literature further divides patients into sub-groups of rotator cuff tendinopathy, including partial thickness and full-thickness tears, as surgical options differ based upon pathology and operative studies tend to recruit more severely affected populations. Recent studies of dextrose prolotherapy with stricter inclusion of predominantly moderately to severely affected patients with partial-thickness tears perform similar to outcomes after arthroscopic partial thickness repairs. Recent case series of arthroscopic partial thickness repairs demonstrate improvements in pain VAS from 6.4 to 1.6 and forward flexion improvements from approximately 120-137 to 168-176<sup>52,53</sup>. This patient population parallels that seen in Seven et al as patients had similar pathologies, baseline pain and range of motion restrictions. In comparison of these results, it appears as those with moderate to severe partial thickness rotator cuff tendinopathy who present with limitations including pain and range of motion may benefit from dextrose prolotherapy similarly to arthroscopic repair. However, complication rates were lower in those receiving prolotherapy as a small proportion of arthroscopically repaired patients developed post-operative adhesive

capsulitis<sup>52</sup>. Further studies of this population are needed with large, randomized studies of direct comparisons within a homogeneous patient population to fully understand their comparative effectiveness.

The rigorous methodology, following PRIMSA guidelines and the AMSTAR-2 criteria<sup>54,55</sup>, strengthens the results described in this review. Due to the rigorous methodology with comprehensive literature search and screening process, this review includes the most current knowledge surrounding dextrose solution prolotherapy for rotator cuff tendinopathy. Although these results are strengthened by the high level of evidence, with all included studies being randomized controlled trials, there was variability in quality as assessed by the Cochrane Collaboration's Risk of Bias tool.

This review is limited by the quality of methodology of the included studies, as the majority of studies demonstrated a high risk of bias. In addition, this review is limited by the low number of studies, heterogeneity of included patients, variable follow-up periods, diverse control interventions and different interventions with varying targets and locations of injection, image-guidance, volumes and concentration of dextrose, and repetition of intervention. Patient populations varied widely between studies with the inclusion of pathologies anywhere from tendinosis to calcific tendinitis and partial or full thickness tears. These individual pathologies have their own specific organic causes that may respond differently to intervention. Specifically, those with comparatively severe grades of degenerative rotator cuff tears and/or calcific tendinitis may have limited potential to heal with dextrose prolotherapy as the proposed mechanism of

action, induction of an inflammatory response to promote tissue regeneration, will not solve the underlying pathology of full-thickness rupture or already high inflammatory state, respectively. Furthermore, meta-analysis was unable to be performed as there were highly variable dextrose prolotherapy interventions, control groups, outcomes assessed and length of follow-up. In addition, we were unable to complete sub-group analysis comparing different protocols/approaches or specific pathologies of rotator cuff tendinopathy, all which may have considerable influence on efficacy. Lastly, few studies contain comprehensive complications reporting, and though outcomes may appear favorable, the possibility for underreporting exists. This review presents the best available evidence on this emerging technique, with consideration to minimize the effects of bias.

## Conclusion

There is currently conflicting evidence that prolotherapy significantly improves pain, function or range of motion in patients with rotator cuff tendinopathies. The variable results in published studies may be explained by the heterogeneity of treatment protocols which vary from repeat multi-site entheses injection to one-time single-site injection within the supraspinatus entheses or tendon. Within the literature there has been improvements in pain intensity with repeat multi-site injection protocols and a potential to improve function and range of motion compared to physical therapy while one-time single-site injection protocols have not demonstrated any significant improvement compared to corticosteroid injection or saline entheses injection. Further research is warranted to better understand the factors affecting response to dextrose prolotherapy including varying rotator cuff tendinopathy pathologies and treatment protocols including number and site of injections and its comparison to alternative interventions including effectiveness and complication profile.



## References:

1. Rashid, M. S. *et al.* Increasing age and tear size reduce rotator cuff repair healing rate at 1 year. *Acta Orthop.* **3674**, 1–6 (2017).
2. Schmidt, C. C., Jarrett, C. D. & Brown, B. T. Management of rotator cuff tears. *J. Hand Surg. Am.* **40**, 399–408 (2015).
3. Sambandam, S. N. Rotator cuff tears: An evidence based approach. *World J. Orthop.* **6**, 902 (2015).
4. Greenspoon, J. A., Petri, M., Warth, R. J. & Millett, P. J. Massive rotator cuff tears: Pathomechanics, current treatment options, and clinical outcomes. *J. Shoulder Elb. Surg.* **24**, 1493–1505 (2015).
5. Desai, V. S. *et al.* Increasing Numbers of Shoulder Corticosteroid Injections Within a Year Preoperatively May Be Associated With a Higher Rate of Subsequent Revision Rotator Cuff Surgery. *Arthrosc. - J. Arthrosc. Relat. Surg.* **35**, 45–50 (2018).
6. Ramírez, J. P. *et al.* Intra-articular treatment with corticosteroids increases apoptosis in human rotator cuff tears. *Connect. Tissue Res.* **00**, 1–8 (2018).
7. Soler, J., Gidwani, S. & Curtis, M. Early complications from the use of porcine dermal collagen implants (Permacol) as bridging constructs in the repair of massive rotator cuff tears. A report of 4 cases. *Acta Orthop Belg* **73**, 432–436 (2007).
8. Sclamberg, S., Tibone, J., Itamura, J. & Kasraeian, S. Six month magnetic resonance imaging follow-up of large and massive rotator cuff repairs reinforced with porcine small intestinal submucosa. *J Shoulder Elb. Surg* **13**, 538-541. (2004).
9. Moore, D., Cain, E., Schwartz, M. & Clancy, W. J. Allograft reconstruction for massive, irreparable rotator cuff tears. *Am J Sport. Med* **24**, 392-396. (2006).
10. Audenaert, E., Van Nuffel, J., Schepens, A., Verhelst, M. & Verdonk, R. Reconstruction of massive rotator cuff lesions with a synthetic interposition graft: A prospective study of 41 patients. *Knee Surg Sport. Traumatol Arthrosc* **14**, 360–364 (2006).
11. Lin, M. T. *et al.* Comparative Effectiveness of Injection Therapies in Rotator Cuff Tendinopathy: A Systematic Review, Pairwise and Network Meta-analysis of Randomized Controlled Trials. *Arch. Phys. Med. Rehabil.* (2018). doi:10.1016/j.apmr.2018.06.028
12. Reeves, K. D., Sit, R. W. S. & Rabago, D. P. Dextrose Prolotherapy: A Narrative Review of Basic Science, Clinical Research, and Best Treatment Recommendations. *Phys. Med. Rehabil. Clin. N. Am.* **27**, 783–823 (2016).
13. Topol, G. A., Reeves, K. D. & Hassanein, K. M. Efficacy of dextrose prolotherapy in elite male kicking-sport athletes with chronic groin pain. *Arch. Phys. Med. Rehabil.* **86**, 697–702 (2005).
14. Maniquis-Smigel, L. *et al.* Short Term Analgesic Effects of 5% Dextrose Epidural Injections for Chronic Low Back Pain: A Randomized Controlled Trial. *Anesthesiol. Pain Med.* **7**, 1–8 (2016).

- Accepted Article
15. Shamseer, L. *et al.* Preferred reporting items for systematic review and meta-analysis protocols (PRISMA-P) 2015: elaboration and explanation. *BMJ* **349**, g7647 (2015).
  16. McGinn, T. *et al.* Tips for learners of evidence-based medicine: 3. Measures of observer variability (kappa statistic). *CMAJ* **171**, 1369–73 (2004).
  17. Dhawan, A., Brand, J. C., Provencher, M. T., Rossi, M. J. & Lubowitz, J. H. Research Pearls: The Significance of Statistics and Perils of Pooling. *Arthrosc. - J. Arthrosc. Relat. Surg.* **33**, 1099–1101 (2017).
  18. Bertrand, H., Reeves, K. D., Bennett, C. J., Bicknell, S. & Cheng, A.-L. Dextrose Prolotherapy Versus Control Injections in Painful Rotator Cuff Tendinopathy. *Arch. Phys. Med. Rehabil.* **97**, 17–25 (2016).
  19. Seven, M. M. *et al.* Effectiveness of prolotherapy in the treatment of chronic rotator cuff lesions. *Orthop. Traumatol. Surg. Res.* **103**, 427–433 (2017).
  20. Lin, C.-L., Huang, C.-C. & Huang, S.-W. Effects of hypertonic dextrose injection on chronic supraspinatus tendinopathy of the shoulder: randomized placebo-controlled trial. *Eur. J. Phys. Rehabil. Med.* (2018). doi:10.23736/S1973-9087.18.05379-0
  21. Cole, B., Lam, P., Hackett, L. & Murrell, G. A. C. Ultrasound-guided injections for supraspinatus tendinopathy: corticosteroid versus glucose prolotherapy – a randomized controlled clinical trial. *Shoulder Elb.* **10**, 170–178 (2018).
  22. George, J., Ch, S., Jaafar, Z. & Hamid, M. S. A. Comparative Effectiveness of Ultrasound-Guided Intratendinous Prolotherapy Injection with Conventional Treatment to Treat Focal Supraspinatus Tendinosis. **2018**, (2018).
  23. Tashjian, R. Z., Deloach, J., Porucznik, C. a. & Powell, A. P. Minimal clinically important differences (MCID) and patient acceptable symptomatic state (PASS) for visual analog scales (VAS) measuring pain in patients treated for rotator cuff disease. *J. Shoulder Elb. Surg.* **18**, 927–932 (2009).
  24. Gialanella, B. & Bertolinelli, M. Corticosteroids injection in rotator cuff tears in elderly patient: Pain outcome prediction. *Geriatr. Gerontol. Int.* **13**, 993–1001 (2013).
  25. Cook, T., Lowe, C. M., Maybury, M. & Lewis, J. S. Are corticosteroid injections more beneficial than anaesthetic injections alone in the management of rotator cuff-related shoulder pain? A systematic review. *Br. J. Sports Med.* **52**, 497–504 (2018).
  26. Shams, A., El-Sayed, M., Gamal, O. & Ewes, W. Subacromial injection of autologous platelet-rich plasma versus corticosteroid for the treatment of symptomatic partial rotator cuff tears. *Eur. J. Orthop. Surg. Traumatol.* **26**, 837–842 (2016).
  27. H., B. *et al.* Ultrasound guided versus landmark guided corticosteroid injection in patients with rotator cuff syndrome: Randomised controlled trial. *J. Clin. Orthop. Trauma* 80–85 (2017). doi:10.1016/j.jcot.2017.01.005
  28. Aly, A.-R., Rajasekaran, S. & Ashworth, N. Ultrasound-guided shoulder girdle injections are more accurate and more effective than landmark-guided injections: a systematic review and meta-analysis. *Br. J. Sports Med.* **49**, 1042–1049 (2015).
  29. Babaei-Ghazani, A. *et al.* Ultrasound-Guided Versus Landmark-Guided Local

Corticosteroid Injection for Carpal Tunnel Syndrome: A Systematic Review and Meta-Analysis of Randomized Controlled Trials. *Arch. Phys. Med. Rehabil.* **99**, 766–775 (2018).

30. Wu, T., Song, H. X., Dong, Y. & Li, J. H. Ultrasound-guided versus blind subacromial—subdeltoid bursa injection in adults with shoulder pain: A systematic review and meta-analysis. *Semin. Arthritis Rheum.* **45**, 374–378 (2015).
31. Karaahmet, Ö. Z. *et al.* Comparing the effectiveness of ultrasound-guided versus blind steroid injection in the treatment of severe carpal tunnel syndrome. *Turkish J. Med. Sci.* **47**, 1785–1790 (2017).
32. Gebremariam, L. *et al.* Subacromial impingement syndrome—effectiveness of physiotherapy and manual therapy. *Br. J. Sports Med.* **48**, 1202–1208 (2014).
33. Lee, D.-H., Hong, J. Y., Lee, M. Y., Kwack, K.-S. & Yoon, S.-H. Relation Between Subacromial Bursitis on Ultrasonography and Efficacy of Subacromial Corticosteroid Injection in Rotator Cuff Disease: A Prospective Comparison Study. *Arch. Phys. Med. Rehabil.* **98**, 881–887 (2017).
34. Tashjian, R. Z. *et al.* Determining the minimal clinically important difference for the American Shoulder and Elbow Surgeons score, Simple Shoulder Test, and visual analog scale (VAS) measuring pain after shoulder arthroplasty. *J. Shoulder Elb. Surg.* **26**, 144–148 (2017).
35. Werner, B. *et al.* What Change in American Shoulder and Elbow Surgeons Score Represents a Clinically Important Change After Shoulder Arthroplasty? *Clin. Orthop. Relat. Res.* **474**, 2672–2681 (2016).
36. Kukkonen, J., Kauko, T., Vahlberg, T., Joukainen, A. & Äärimaa, V. Investigating minimal clinically important difference for Constant score in patients undergoing rotator cuff surgery. *J. Shoulder Elb. Surg.* **22**, 1650–1655 (2013).
37. Roy, J.-S., MacDermid, J. C. & Woodhouse, L. J. Measuring shoulder function: a systematic review of four questionnaires. *Arthritis Rheum.* **61**, 623–32 (2009).
38. Braun, C., Hanchard, N. C., Batterham, A. M., Handoll, H. H. & Betthäuser, A. Prognostic Models in Adults Undergoing Physical Therapy for Rotator Cuff Disorders: Systematic Review. *Phys. Ther.* **96**, 961–971 (2016).
39. Braun, C. & Handoll, H. H. Estimating the Minimal Important Difference for the Western Ontario Rotator Cuff Index (WORC) in adults with shoulder pain associated with partial-thickness rotator cuff tears. *Musculoskelet. Sci. Pract.* **35**, 30–33 (2018).
40. Yoon, S.-H. Relationship Between Subacromial Bursitis on Ultrasonography and Efficacy of Subacromial Corticosteroid Injection in Rotator Cuff Disease: A Prospective Comparison Study...2016 ACRM / American Congress of Rehabilitation Medicine Annual Conference 30 Octob. *Arch. Phys. Med. Rehabil.* **97**, e11–e12 (2016).
41. Kaile, E. & Bland, J. D. P. Safety of corticosteroid injection for carpal tunnel syndrome. *J. Hand Surg. Eur. Vol.* **43**, 296–302 (2018).
42. Cigna, E. *et al.* Late spontaneous rupture of the extensor pollicis longus tendon after

- corticosteroid injection for flexor tenosynovitis. *Eur. Rev. Med. Pharmacol. Sci.* **17**, 845–848 (2013).
43. Lu, H., Yang, H., Shen, H., Ye, G. & Lin, X.-J. The clinical effect of tendon repair for tendon spontaneous rupture after corticosteroid injection in hands. *Medicine (Baltimore)*. **95**, e5145 (2016).
44. Boussakri, H. & Bouali, A. Subcutaneous Rupture of the Extensor Pollicis Longus Tendon after Corticosteroid Injections for DeQuervain’s Stenosing Tenovaginitis. *Case Rep. Orthop.* **2014**, 1–4 (2014).
45. Saffarini, M. Editorial Commentary: “Doctor, Are You Sure the Steroid Injection Won’t Harm My Shoulder?” Perhaps We Should Stop Injecting Corticosteroids and Just Repair Those Rotator Cuffs. *Arthrosc. - J. Arthrosc. Relat. Surg.* **35**, 51–53 (2019).
46. McClincy, M. P. & Rodosky, M. W. Arthroscopic Subacromial Decompression. *Oper. Tech. Orthop.* **25**, 10–14 (2015).
47. Martins, C. A. Q. *et al.* Dextrose prolotherapy and corticosteroid injection into rat Achilles tendon. *Knee Surgery, Sport. Traumatol. Arthrosc.* **20**, 1895–1900 (2012).
48. Sánchez, M. *et al.* Platelet-rich plasma, a source of autologous growth factors and biomimetic scaffold for peripheral nerve regeneration. *Expert Opin. Biol. Ther.* **17**, 197–212 (2017).
49. Malavolta, E. A., Assunção, J. H., Gracitelli, M. E. C. & Ferreira Neto, A. A. Comments on: Evaluation of platelet-rich plasma and fibrin matrix to assist in healing and repair of rotator cuff injuries: a systematic review and meta-analysis...Fu CJ, Sun JB, Bi ZG, *et al.* Evaluation of platelet-rich plasma and fibrin matrix to assist. *Clinical Rehabilitation* **30**, 726–727 (2016).
50. Fiz, N. *et al.* Intraosseous Infiltration of Platelet-Rich Plasma for Severe Hip Osteoarthritis. *Arthrosc. Tech.* **6**, e821–e825 (2017).
51. Hurley, E. *et al.* Nonoperative Treatment of Rotator Cuff Disease With Randomized Controlled Trials. *Arthrosc. J. Arthrosc. Relat. Surg.* **35**, 1584–1591 (2019).
52. Rossi, L. A. *et al.* Return to Sports After in Situ Arthroscopic Repair of Partial Rotator Cuff Tears. *Arthrosc. - J. Arthrosc. Relat. Surg.* 1–5 (2018).  
doi:10.1016/j.arthro.2018.07.037
53. Cheon, S. J., Lee, H. Y. & Jeon, W. K. Arthroscopic treatment for intratendinous rotator cuff tear results in satisfactory clinical outcomes and structural integrity. *Knee Surgery, Sport. Traumatol. Arthrosc.* **26**, 1–7 (2018).
54. AlRamadhan, H., Sungjoon, L. & In-Ho, J. Early MRI Findings of Arthroscopic Superior Capsule Reconstruction (ASCR): How to Prevent Early Failure. *Arthrosc. J. Arthrosc. Relat. Surg.* **33**, e21 (2017).
55. Mihata, T. *et al.* Arthroscopic Superior Capsule Reconstruction Eliminates Pseudoparalysis in patients with Irreparable Rotator Cuff Tears. in AAOS (2017).

Study	Sample Size (n)	Age, years (SD)	Sex (% female)	Final Follow-up	Final Follow-up (% of cases/ % of controls)
Bertrand et al. (2016)	73	51 (13)	37%	9 months	93%/ 94%
Seven et al. (2017)	120	51 (12)	47%	12 months	95%/ 73%
George et al (2018)	12	59 (NR)	NR	12 weeks	100%/80%
Lin et al (2019)	31	49 (6)	39%	6 weeks	100%/100%
Cole et al. (2018)	36	51 (16)	25%	6 months	88%/ 84%

**Table 1: Demographics of included studies.** SD= Standard deviation, NR= Not reported

Study	Inclusion Criteria	Intervention	Re-injection	Control	Main Results
I d et al.	Supraspinatus pathology with >3 months of symptoms. Pathologies consisted of either non-calcific or calcific tendinosis, partial tear, or full thickness tear less than 1.2cm as noted on high-resolution ultrasound.	Land-mark based injection of 25% dextrose into the supraspinatus, infraspinatus, teres minor, subscapularis, coracoid process, biceps long head, inferior glenohumeral ligament, teres major and posterior inferior glenohumeral ligament. 1 mL of solution was injected at each primary injection site, other tender areas along the enthesis and adjacent to the primary site were injected at 1-cm intervals each with 0.5mL of solution.	Repeat injections at 0, 1 and 2 months	Either entheses saline injection without dextrose or superficial saline injection. All participants received a detailed rehabilitation protocol consisting of specific strengthening and range-of-motion exercises	<p><b>VAS:</b> Prolotherapy: 7.9+/-0.4 and 5.0+/-0.6* vs. control: 6.9+/-0.4 and 5.6+/-0.6 @ baseline and 9-months, respectively</p> <p><b>Ultrasound Shoulder Pathology Rating Scale:</b> Prolotherapy: 4.0+/-0.4 and 3.7+/-0.5 vs. control: 4.3+/-0.4 and 3.7+/-0.4 @ baseline and 9-months, respectively</p>
Seven et al. (2017)	Rotator cuff lesions with >6 months of symptoms. Pathologies consisted of tendinosis or partial tear of any rotator cuff tendons diagnosed by MRI.	Ultrasound-guided injection of 4ml 25% dextrose into the subacromial bursa and a maximum of 20mL 15% dextrose into the supraspinatus, infraspinatus, teres minors, pectoralis major, coracobrachialis, biceps brachii long head and	Repeat injections were given for a maximum of 6 injections, stopped if greater than 75% pain	Non-operative management consisting of a detailed physiotherapy program of 3 sessions per week for 12 weeks.	<p><b>VAS:</b> Prolotherapy: 7.85+/-1.29 and 0.89+/-1.64* vs. control: 7.36+/-1.38 and 3.77+/-2.15 @ baseline and 12-months, respectively</p> <p><b>WORC:</b> Prolotherapy: 32.21+/-17.49 and 90.37+/-10.12* vs. control: 37.77+/-16.03 and 69.08+/-16.70 @ baseline and 12-months, respectively</p> <p><b>SPADI:</b> Prolotherapy: 74.76+/-18.54 and 7.66+/-10.64* vs. control: 68.62+/-20.4 and 34.94+/-19.14 @ baseline and 12-months, respectively</p> <p><b>AROM:</b> aROM: Prolotherapy: 126.89+/-40.89 and 176.57+/-9.5* vs. control: 133.75+/-34.84 and 166.36+/-16.95 @ baseline and 12-months, respectively</p> <p>extROM: Prolotherapy: 77.19+/-17.9 and 88.94+/-4.09 vs. control: 79.31+/-17.30 and 86.59+/-9.69 @ baseline and 12-months, respectively</p> <p>IntROM: Prolotherapy: 59.73+/-26.03 and 68.77+/-4.25* vs. control 56.47+/-</p>



		short head, subscapularis, and inferior glenohumeral ligament.	reduction or patient deciding to withdraw.		15.64 and 66.02 +/- 7.11 @ baseline and 12-months, respectively
Ge... et al (2018)	Rotator cuff lesion with >6 months of symptoms, confirmed supraspinatus tendinosis on ultrasound, failure of improvement after 1-month of physiotherapy. Pathologies consisted of tendinosis, calcific tendinitis, and partial thickness tears. Dynamic impingement or full-thickness tears on ultrasound were excluded.	Ultrasound-guided injection of 0.5-1.0mL of 12.5% dextrose and 0.5% lidocaine into the hypoechoic areas on ultrasound. Tendon needling of the area of tendinosis was performed prior to injection.	Single Injection	Physiotherapy protocol for the control group or interventional group was not described.	<p><b>DASH Pain Score (1-5 Likert scale):</b> Prolotherapy: 3.29 +/- SD NR and 1.86 +/- SD NR vs. control: 3.20 +/- SD NR and 2.40 +/- SD NR @ baseline and 12-months, respectively</p> <p><b>DASH:</b> Prolotherapy: 60.14 +/- SD NR and 43.89 +/- SD NR vs. control: 56.86 +/- SD NR and 46.68 +/- SD NR @ baseline and 12-months, respectively</p> <p><b>DASH difficulty to sleep score (1-5 Likert scale):</b> Prolotherapy: 3.29 +/- SD NR and 2.15 +/- SD NR* vs. control: 2.20 +/- SD NR and 2.60 +/- SD NR @ baseline and 12-months, respectively</p> <p><b>AROM:</b> aROM: Prolotherapy: +20 degrees +/- SD NR* vs. control: -12 degrees @ baseline vs 12-months</p> <p>extROM: No significant difference</p> <p>IntROM: No significant difference</p> <p><b>Ultrasound Findings:</b> No statistically significant difference in ratio echogenicity or reduction in area of tendinosis</p>
Lin et al (2019)	Chronic rotator cuff lesions with >6 months of symptoms. Pathologies consisted of chronic supraspinatus tendinopathy including tear or tendinosis diagnosed using ultrasound. Full	Ultrasound-guided injection of 5mL 20% dextrose solution into the supraspinatus tendon insertion site	Single Injection	Ultrasound-guided normal saline injection into the supraspinatus insertion site. All participants received a detailed rehabilitation protocol consisting of specific strengthening	<p><b>VAS:</b> Prolotherapy: 5.56 +/- 0.81 and 5.31 +/- 0.72 vs. control: 5.33 +/- 0.82 and 4.87 +/- 0.64 @ baseline and 6-weeks, respectively</p> <p><b>SPADI:</b> Prolotherapy: 60.50 +/- 7.87 and 61.56 +/- 4.68 vs. control: 65.00 +/- 2.78 and 60.00 +/- 4.90 @ baseline and 6-weeks, respectively</p> <p><b>AROM:</b> aROM: Prolotherapy: 157.15 +/- 13.40 and 159.38 +/- 7.50 vs. control: 156.21 +/- 6.51 and 161.20 +/- 6.03 @ baseline and 6-weeks, respectively</p> <p>extROM: Prolotherapy: 57.50 +/- 10.65 and 61.25 +/- 8.27 vs. control: 60.00 +/- 8.45 and 62.33 +/- 4.17 @ baseline and 6-weeks, respectively</p> <p>IntROM: Prolotherapy: 45.00 +/- 8.17 and 45.00 +/- 8.17 vs. control 44.67 +/- 7.32 and 44.67 +/- 7.24 @ baseline and 6-weeks, respectively</p>

	thickness tears or calcific tendinopathy was not excluded			and range-of-motion exercises	<b>Ultrasound Findings:</b> ssThickness: Prolotherapy: 6.93+/-1.18 and 7.43+/-1.18 vs. control: 7.01+/-0.58 and 7.16+/-0.51 @ baseline and 6-weeks, respectively Echogenicity: Prolotherapy: 46.01+/-10.08 and 51.73+/-8.08 vs. control: 49.81+/-7.24 and 53.93+/-6.05 @ baseline and 6-weeks, respectively Echogenicity ratio: Prolotherapy: 1.94+/-0.36 and 2.01+/-0.33 vs. control 1.73+/-0.29 and 1.91+/-0.18 @ baseline and 6-weeks, respectively
Cole et al (2018)	Rotator cuff lesions with >3 months of symptoms. Pathologies consisted of supraspinatus tendinopathy with ultrasound evidence of abnormal hypoechoic areas or anechoic clefts or foci in the supraspinatus tendon suggesting tendinopathy. Calcific tendinitis and full thickness tears were excluded.	Ultrasound-guided injection of 25% glucose prolotherapy into the hypoechoic/anechoic areas of the supraspinatus tendon with a maximum of 0.5mL injected in each discreet area.	Single Injection	Ultrasound-guided subacromial corticosteroid injection of 40mg methylprednisolone acetate. All participants received a detailed rehabilitation protocol consisting of specific strengthening and range-of-motion exercises	<b>Patient-rated five-point Likert Scale</b> (very severe at 5 to none at 1): Prolotherapy: 3.2+/-0.3 and 2.5+/-0.2 vs. control: 3.0+/-0.2 and 2.3+/-0.2 @ baseline and 6-months, respectively <b>AROM:</b> aROM: Prolotherapy: 166+/-5 and 175+/-2 vs. control: 153+/-8 and 163+/-8 @ baseline and 6-months, respectively extROM: Prolotherapy: 67+/-4 and 61+/-3 vs. control: 60+/-4 and 63+/-5 @ baseline and 6-months, respectively <b>Impingement Symptoms:</b> Prolotherapy: 100% and 24% vs. control: 100% and 26% @ baseline and 6-months, respectively <b>Shoulder abduction strength(N):</b> Prolotherapy: 59+/-8 and 77+/-8 vs. control: 68+/-8 and 71+/-9 @ baseline and 6-months, respectively

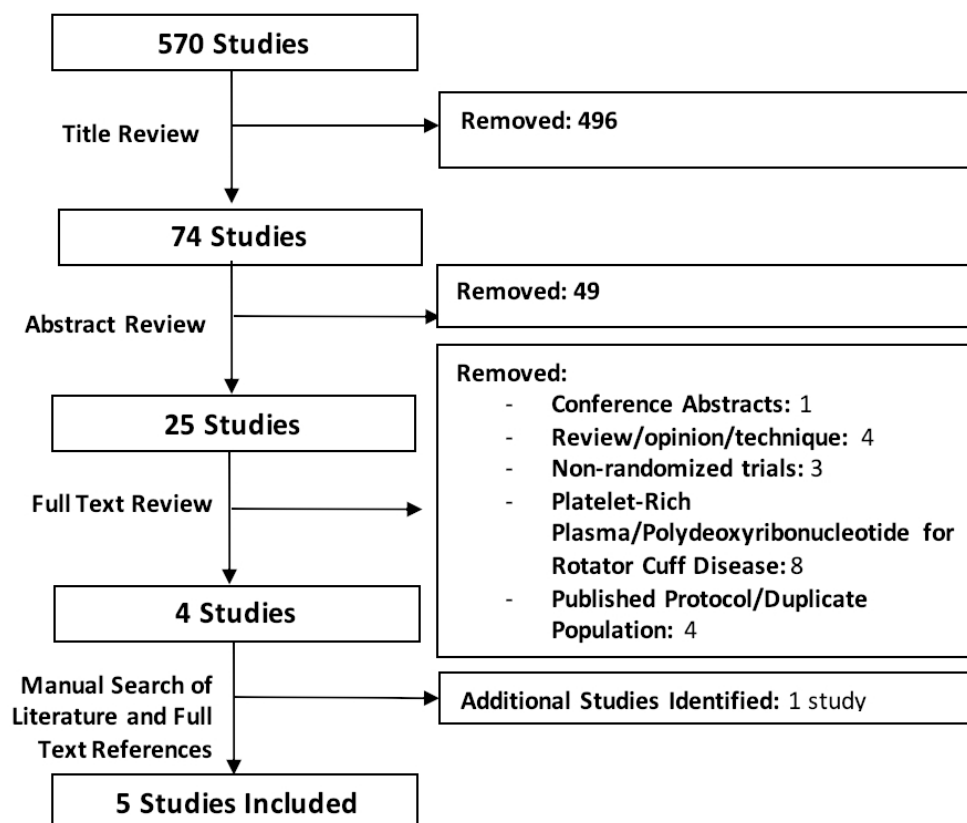
**Table 2: Descriptive information and Study Results for Included Studies.** VAS= Visual Analog Score. SPADI= Shoulder pain and disability index. aROM = Abduction range of motion. extROM= External range of motion. intROM=Internal range of motion. AROM= Active range of motion. N= Newtons. ssThickness= Supraspinatus thickness. US = Ultrasound, MRI = Magnetic Resonance Imaging \*p<0.05 compared to controls.

**Figure 1: Screening process**



**Figure 2: Risk of bias summary:** low risk of bias in green; high risk of bias in red; unclear risk of bias is left blank.

**Figure 3: Risk of bias graph:** low risk of bias in green; high risk of bias in red; unclear risk of bias is left blank.



	Random sequence generation (selection bias)	Allocation concealment (selection bias)	Blinding of participants and personnel (performance bias)	Blinding of outcome assessment (detection bias)	Incomplete outcome data (attrition bias)	Selective reporting (reporting bias)	Other bias
Bertrand et al (2016)							
Cole et al (2018)							
George et al (2018)							
Lin et al (2019)							
Seven et al (2017)							

