



Intra-Articular Injection of Autologous Adipose Tissue-Derived Mesenchymal Stem Cells for the Treatment of Knee Osteoarthritis: A Phase IIb, Randomized, Placebo-Controlled Clinical Trial

WOO-SUK LEE ^a, HWAN JIN KIM,^{b,c} KANG-IL KIM ^{b,c}, GI BEOM KIM ^{b,c}, WOOK JIN^d

Key Words. Knee • Osteoarthritis • Adipose-derived mesenchymal stem cell • Intra-articular injection

^aDepartment of Orthopaedic Surgery, College of Medicine, Gangnam Severance Hospital, Yonsei University, Seoul, South Korea; ^bDepartment of Orthopaedic Surgery, Center for Joint Diseases and Rheumatism, Kyung Hee University Hospital at Gangdong, Seoul, South Korea; ^cSchool of Medicine, Kyung Hee University, Seoul, South Korea; ^dDepartment of Radiology, Kyung Hee University Hospital at Gangdong, Seoul, South Korea

Correspondence: Kang-Il Kim, M.D., Ph.D., Department of Orthopaedic Surgery, Center for Joint Diseases and Rheumatism, Kyung Hee University Hospital at Gangdong, 892, Dongnam-ro, Gangdong-gu, Seoul 05278, Republic of Korea. Telephone: 82-2-440-6151; e-mail: khuknee@gmail.com

Received June 5, 2018; accepted for publication January 8, 2019; first published March 5, 2019.

<http://dx.doi.org/10.1002/sctm.18-0122>

This is an open access article under the terms of the Creative Commons Attribution-NonCommercial-NoDerivs License, which permits use and distribution in any medium, provided the original work is properly cited, the use is non-commercial and no modifications or adaptations are made.

ABSTRACT

Mesenchymal stem cells (MSCs) have been the focus of an emerging treatment for osteoarthritis. However, few studies reported about outcomes of an intra-articular injection of autologous adipose-derived mesenchymal stem cells (AD-MSCs). This study aimed to assess the efficacy and safety of a single intra-articular injection of AD-MSCs for patients with knee osteoarthritis. It was a prospective double-blinded, randomized controlled, phase IIb clinical trial. AD-MSCs were administered for 12 patients (MSC group), and the group was compared with 12 knees with injection of normal saline (control group) up to 6 months. All procedures were performed in the outpatient clinic. Primary outcome measure was the Western Ontario and McMaster Universities Osteoarthritis index (WOMAC) score. Secondary outcome measure included various clinical and radiologic examination, and safety after injection. Change of cartilage defect after injection was evaluated using magnetic resonance imaging (MRI). Single injection of AD-MSCs led to a significant improvement of the WOMAC score at 6 months. In the control group, there was no significant change in the WOMAC score at 6 months. No serious adverse events were observed in both groups during the follow-up period. In MRI, there was no significant change of cartilage defect at 6 months in MSC group whereas the defect in the control group was increased. An intra-articular injection of autologous AD-MSCs provided satisfactory functional improvement and pain relief for patients with knee osteoarthritis in the outpatient setting, without causing adverse events at 6 months' follow-up. Larger sample size and long-term follow-up are required. *STEM CELLS TRANSLATIONAL MEDICINE 2019;8:504–511*

SIGNIFICANCE STATEMENT

This study was designed as a prospective, randomized, double-blinded, placebo-controlled trial in patients with knee osteoarthritis. All procedures were performed in the outpatient clinic setting. Only intra-articular injection was applied, without surgical intervention and concomitant injection. An intra-articular injection of autologous adipose tissue-derived mesenchymal stem cells provided satisfactory functional improvement and pain relief for patients with knee osteoarthritis without causing apparent adverse events at 6 months' follow-up.

INTRODUCTION

In osteoarthritis, mesenchymal stem cells (MSCs) are gaining popularity as a disease-modifying treatment because of their ease of harvesting, safety [1, 2], and potential to differentiate into cartilage tissue [3–5]. Furthermore, MSCs have been known for paracrine [6–8], anti-inflammatory [9, 10], and immunomodulatory effects [11–15] through the release of several growth factors and cytokines [1, 2, 16]. Because the pathophysiology of osteoarthritis is based on both degeneration and inflammation, the paracrine

effect, reducing of immune response, and stimulation of local tissue repair with the properties of MSCs would be beneficial to improve the intra-articular environment as a disease-modifying treatment [11, 12, 17, 18]. Successful pain relief, functional improvement, and even cartilage regeneration have been reported in clinical studies of the intra-articular injection of MSCs for knee osteoarthritis [1, 2, 16, 19]. However, besides the study of Vega et al. [16], most studies were not randomized or blinded and did not have a comparative group [1, 2, 19]. Some previous studies used allogeneic MSCs [16, 20], and

their use has been concerning because of the theoretical potential for adverse effects such as tumorigenesis or host immune rejection when compared with autologous MSCs, although no severe adverse effects have been reported. Our previous phase I/IIa trial [2] reported the clinical efficacy and safety after using an intra-articular injection of autologous adipose tissue-derived MSCs (AD-MSCs) with high dose (1×10^8 cells). However, the study [2] performed the intra-articular injection of AD-MSCs after arthroscopic lavage procedure in the operating room. Therefore, there might be performance bias as clinical and structural improvements would be affected by surgical procedures. In addition, there was an open label test without control group [2].

Therefore, we conducted a current phase IIb clinical trial to assess the efficacy and safety of a single intra-articular injection of high-dose (1×10^8 cells), autologous AD-MSCs in patients with knee osteoarthritis through randomized, double-blinded, and placebo-controlled study in the outpatient setting, without limitation of daily activity. We report the clinical and radiological outcome after a single intra-articular injection of autologous AD-MSCs.

MATERIALS AND METHODS

Study Design

The present study was performed between June 2015 and December 2016 in two orthopedic centers. The protocol was approved by the institutional review board of both institutes, and Korea Food and Drug Administration. This was designed as a randomized, double-blinded, placebo-controlled study in patients with knee osteoarthritis. Eligible patients were between 18 and 75 years of age with osteoarthritis of the knee joint (Kellgren-Lawrence grade 2 to 4) [21] and had an mean pain intensity of 4 or more on a 10-point visual analog scale (VAS) for at least 12 weeks (supplemental online Appendix 1). Patients underwent physical examination; laboratory tests such as routine blood and urine tests, serologic test, tumor screening, electrocardiogram, and pregnancy test if indicated; and magnetic resonance imaging (MRI) of the knee at screening with informed consent. To objectively assess cartilage regeneration, we enrolled patients with at least one focal or localized grade 3 or 4 lesion on MRI scan. All pain medications were discontinued except the rescue analgesic. All participants who were identified as eligible for clinical trials returned to the hospital within 1 week for lipoaspiration. All lipoaspiration procedures were performed in the outpatient clinic. According to the randomization, participants were blindly assigned to AD-MSCs injection (MSC group) or normal saline injection (control group). Three weeks after lipoaspiration, one of autologous AD-MSC injection or normal saline injection was administered intra-articularly in the outpatient clinic. No specific physical limitation was recommended from the day after the injection. Patients were followed up at 1, 3, and 6 months after the injection. At each visit, the efficacy and safety evaluation were performed. Furthermore, simple radiograph and MRI of the knee were obtained at 3 and 6 months after the injection in all patients. The rescue analgesic was defined as an approved medication for patients' pain control. The rescue medication that was permitted was acetaminophen at a dose of 4,000 mg or less per day. Other analgesics were not permitted, and any medications that patients were taking were recorded. If the participant had an osteoarthritis medication, the drug was discontinued for 2 weeks as a wash-out period.

MSC Preparation

All the procedures were performed with an informed consent. AD-MSCs (Jointstem; R-Bio, Seoul, Korea) used in the current study were isolated and cultured based on a previously reported study [22]. Adipose tissues of patients were obtained by lipoaspiration from abdominal subcutaneous fat under Good Manufacturing Practices conditions. Lipoaspiration was performed using the tumescent technique, which was defined as 3–5 cc of infiltrate per 1 cc of aspirate at 3 weeks before injection [23, 24]. The process of lipoaspiration was as follows: (a) sterile skin preparation; (b) local anesthesia using 2% lidocaine; (c) stab incision (2 mm) using number 11 mass; (d) injection of tumescent solution into the subcutaneous fat layer of the harvesting site; (e) after 10–15 minutes, approximately 20 mL of adipose tissue was collected using an metal cannula connected to a 10 cc syringe; (f) the collected fat-tumescent solution was kept at 2°C – 8°C in a sterile bag and transported to the laboratory; and (g) wound suture (number 5 blue nylon) and dressing. Aspirated tissues were digested with collagenase I (1 mg/mL) under gentle agitation for 60 minutes at 37°C [22]. The digested tissues were filtered through a 100-mm nylon sieve to remove cellular debris and were centrifuged to obtain a pellet. The pellet was resuspended in Dulbecco's modified Eagle's medium (Invitrogen, USA)-based media containing 0.2 mM ascorbic acid and 10% fetal bovine serum (FBS). The cell suspension was recentrifuged. The supernatant was removed and the pellet was collected. The cell fraction was cultured for 4–5 days in Keratinocyte-SFM (Invitrogen, USA)-based media containing 0.2 mM ascorbic acid, 0.09 mM calcium, 5 ng/mL recombinant epidermal growth factor (rEGF), and 5% FBS until confluent (passage 0). When the cells reached 90% confluency, they were passaged. AD-MSCs from the control group were also cultured until passage 1. The cells were then frozen and stored at liquid nitrogen cell storage (-196°C), which might be the most common method of storing cells safely for a long period in most laboratories [25]. All of the AD-MSCs used in this study were collected at passage 3. Culture-expanded cells were then tested for cell number, viability, purity (CD31, CD34, CD45), identity (CD 73, CD 90), sterility (bacterial and fungal), and endotoxin and mycoplasma contamination as recommended by the Code of Federal Regulations, Title 21 (21CFR), before shipping. Cultured AD-MSCs maintained a survival rate of more than 80% for 72 hours at 2°C – 8°C [22]. This high level of purity was demonstrated by the consistent expression of positive or negative surface antigen for MSC up to 72 hours. Thus, the cells were made and shipped on the day of injection, with a survival rate of at least 87% (average 92.8%) for 72 hours. And the MSCs were injected into the knee joint in the outpatient clinic within an hour after being delivered to the hospital.

Intra-Articular Injection

All injections were administered once into the patient's knee joint under the ultrasound guidance. Intra-articular injection was performed by a specialized physician who was not involved in the entire evaluations of the participants. Also, neither the physician nor the patient was aware of who was receiving AD-MSCs, hence double blinding the study. In the MSC group, 1×10^8 cells of AD-MSCs in 3 mL of saline was administered intra-articularly, and in the control group, 3 mL of saline (NaCl 9 mg/mL) was administered intra-articularly under the ultrasound guidance. The dose of cell injection was determined by the result of the previous study [2].

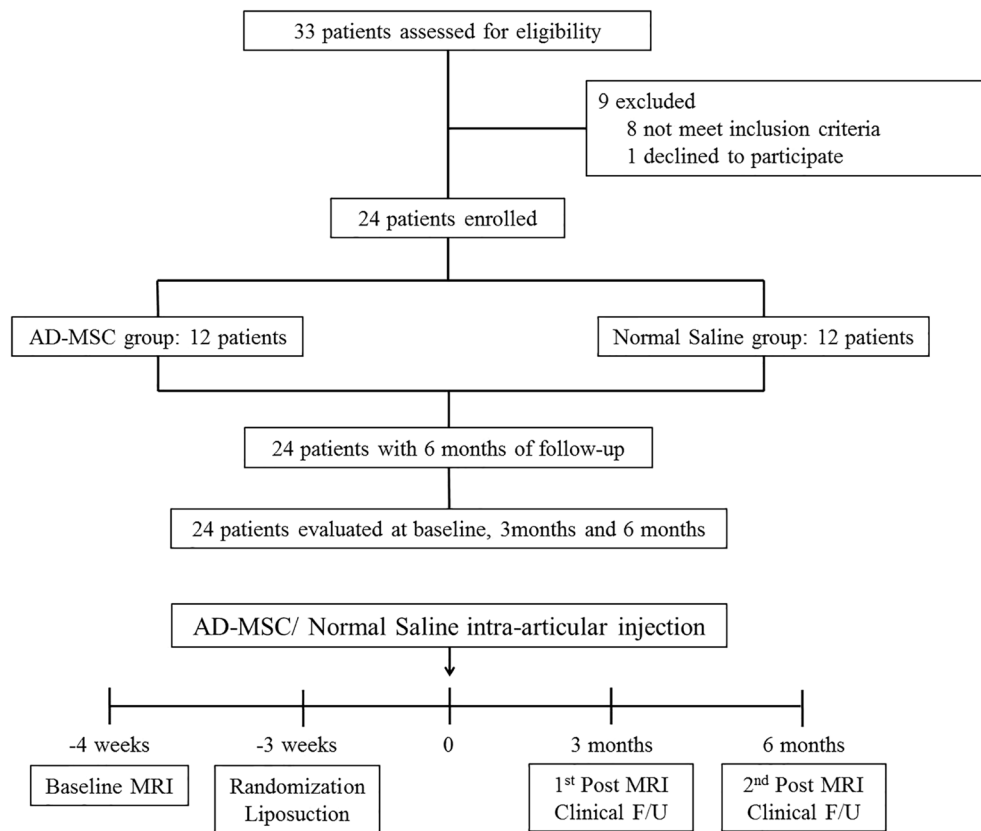


Figure 1. Study flow diagram.

Clinical Evaluation

The clinical evaluation was performed by a blinded physician. Primary outcome was the Western Ontario and McMaster Universities Osteoarthritis Index (WOMAC) [26] at 6 months after intra-articular injection.

Secondary outcomes were categorized into clinical scores, physical examination, radiologic examination, and safety. Clinical scores included a 10-point VAS for knee pain and Knee Injury and Osteoarthritis Outcome Score (KOOS) [27]. Physical examination included range of motion, quadriceps power, presence of joint effusion, presence of joint crepitus, presence of medial joint line tenderness, and presence of pes anserinus tenderness.

Radiologic Evaluation

Radiologic outcomes were measured with Kellgren-Lawrence (K-L) grade [21], joint space width of medial and lateral compartment [28, 29], and hip-knee-ankle (HKA) angle [30] using simple radiograph. MRI was evaluated before injection and 3 and 6 months after injection. MRI was performed using a 3.0-T scanner (Achieva 3.0-T; Philips Medical Systems, Eindhoven, Netherlands) with an 8-channel knee coil. The maximum gradient strength was 80 mT/m, and the maximum slew rate was 100 mT/m/ms. The images were transferred digitally to a picture archiving and communication system (PiView STAR, Seoul, Korea). Radiologic measurements were performed using the electronic calipers and goniometer provided in the software.

The size and depth of cartilage defects was also measured using MRI by two blinded musculoskeletal radiologists. Depth of the cartilage defect in MRI was classified according to the

modified Noyes grading system [31]. For calculating size of the cartilage defect in MRI, the maximum diameter of the cartilage defect with modified Noyes [31] grade 3 and 4 in each compartment was analyzed in the sagittal (anteroposterior) and coronal (mediolateral) images. Size of the cartilage defect was measured by multiplying the anteroposterior and the mediolateral diameter [2]. If multiple defects existed in one compartment, the highest grade was selected. Calculated size of the cartilage defects was compared within each group and between both groups after the injection.

The safety was analyzed with vital signs, physical examination, laboratory tests (supplemental online Appendix 2), and adverse events. The severity of adverse events was based on the National Cancer Institute-Common Terminology Criteria for Adverse Events (NCI-CTCAE) [32]. When adverse events occurred, the cause-and-relationship between injection and adverse events was recorded according to the World Health Organization-Uppsala Monitoring Centre causality assessment system [33].

Statistical Analysis

Because the primary outcome was the difference in WOMAC score between baseline and 6 months, sample size was set based on the results of the previous study (α risk 0.05, power 0.8, changes in WOMAC score 21.3, and SD 19.12) [2]. The required number of patients was determined to be five. Considering the representative clinical trial and dropout rate, we decided to recruit 12 patients in each group. Outcome measures were analyzed based on the intention-to-treat population. Data are reported as means \pm SD. Unpaired *t* test was

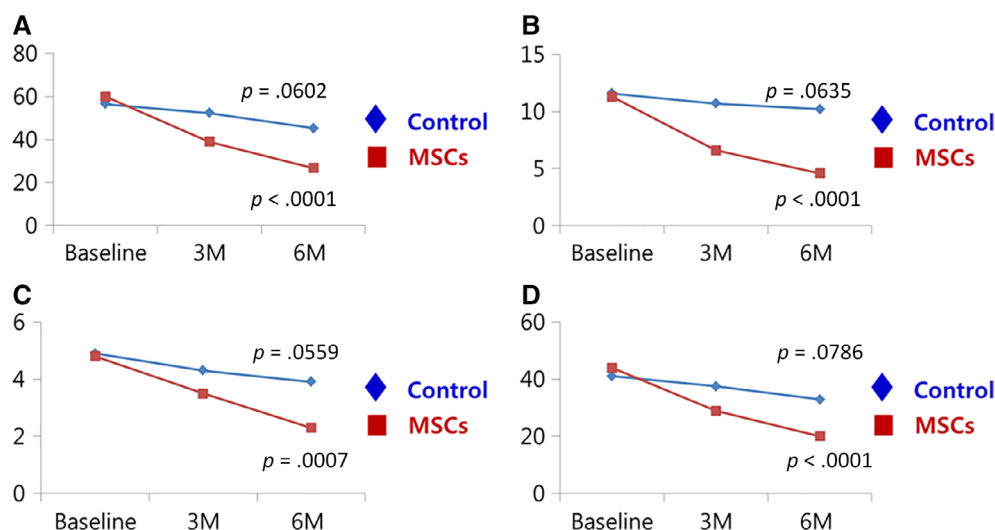


Figure 2. Changes in the WOMAC score during the 6-month period after intra-articular injection in the MSC group and control group. Patients with injection of AD-MSC showed significant improvement in the WOMAC score. Patients in the control group did not significantly change in the WOMAC score. **(A):** The WOMAC total score. **(B):** The pain subscore of the WOMAC. **(C):** The stiffness subscore of the WOMAC. **(D):** The physical function subscore of the WOMAC. Abbreviations: MSC, mesenchymal stem cell; WOMAC, Western Ontario and McMaster Universities Osteoarthritis index.

Table 1. Demographic characteristics in the MSC and the control group

Characteristics	MSC group	Control group
Age, years	62.2 ± 6.5	63.2 ± 4.2
Gender, n (%)		
Male	3 (25)	3 (25)
Female	9 (75)	9 (75)
Height, cm	159.4 ± 7.2	159.8 ± 7.0
Weight, kg	66.5 ± 11.1	65.7 ± 12.4
Body-mass index	25.3 ± 4.9	25.4 ± 3.0
Kellgren-Lawrence grade, n (%)		
Grade 2	6 (50)	5 (41.7)
Grade 3	6 (50)	6 (50)
Grade 4	—	1 (8.3)
Mechanical axis, °	Varus 1.4° ± 5.7°	Varus 0.4° ± 3.6°
Baseline WOMAC score	60.0 ± 17.0	56.4 ± 16.3
Cartilage defect, mm ^{2a}	312.4 ± 271.0	389.9 ± 273.0

^aCartilage defect means the defect in the femoral condyle of each participant.

Abbreviations: —, no data; MSC, mesenchymal stem cell; WOMAC, Western Ontario and McMaster Universities Osteoarthritis index.

used to assess efficacy before and after injection, and McNemar's test or Bowker's test was used for categorical variables. The analysis was performed using SAS version 9.2 (SAS institute, Inc., Cary, NC).

RESULTS

Demographics

Thirty-three patients were assessed for eligibility, and 24 patients were enrolled: 12 patients in the MSC group and 12 patients in

the control group through the randomization (Fig. 1). All patients were followed up. Patients in each group had similar demographic characteristics (Table 1).

Clinical Outcomes

The intra-articular injection of AD-MSCs was associated with improvement of the WOMAC score at 6 months after injection as compared with baseline (Fig. 2). Patients in the control group were not significantly improved over 6 months. The mean reduction of the WOMAC score in the MSC group from the baseline was 55% at 6 months after injection, from 60.0 ± 17.0 to 26.7 ± 13.3 ($p < .001$). All subscores of the WOMAC at 6 months significantly improved from the baseline in the MSC group only ($p < .05$ for all; Fig. 2).

The VAS for the knee pain significantly decreased from 6.8 ± 0.6 to 3.4 ± 1.5 in the MSC group only ($p < .001$; Fig. 3). The pain, symptoms, activities of daily living, sports, and quality of life subscores of the KOOS in the MSC group significantly increased over 6 months compared with baseline ($p < .05$ for all; Fig. 3). However, patients in the control group were not significantly improved during the study period.

In the MSC group, range of motion was significantly improved, from 127.9° ± 10.3° to 134.6° ± 12.5° at 6 months after the injection ($p = .0299$). Patients in the control group showed no significant change in range of motion. Other physical examinations, including quadriceps power, presence of joint effusion, presence of joint crepitus, presence of medial joint line tenderness, and presence of pes anserinus tenderness, showed no significant change in both groups at 6 months after injection compared with baseline.

Radiological Outcomes

K-L grade, joint space width of medial and lateral compartment, and HKA angle did not change significantly over 6 months in both groups. The size of the cartilage defect in MRI at 6 months was not significantly changed in the MSC group ($p = .5803$), whereas the size of the cartilage defect in the control group

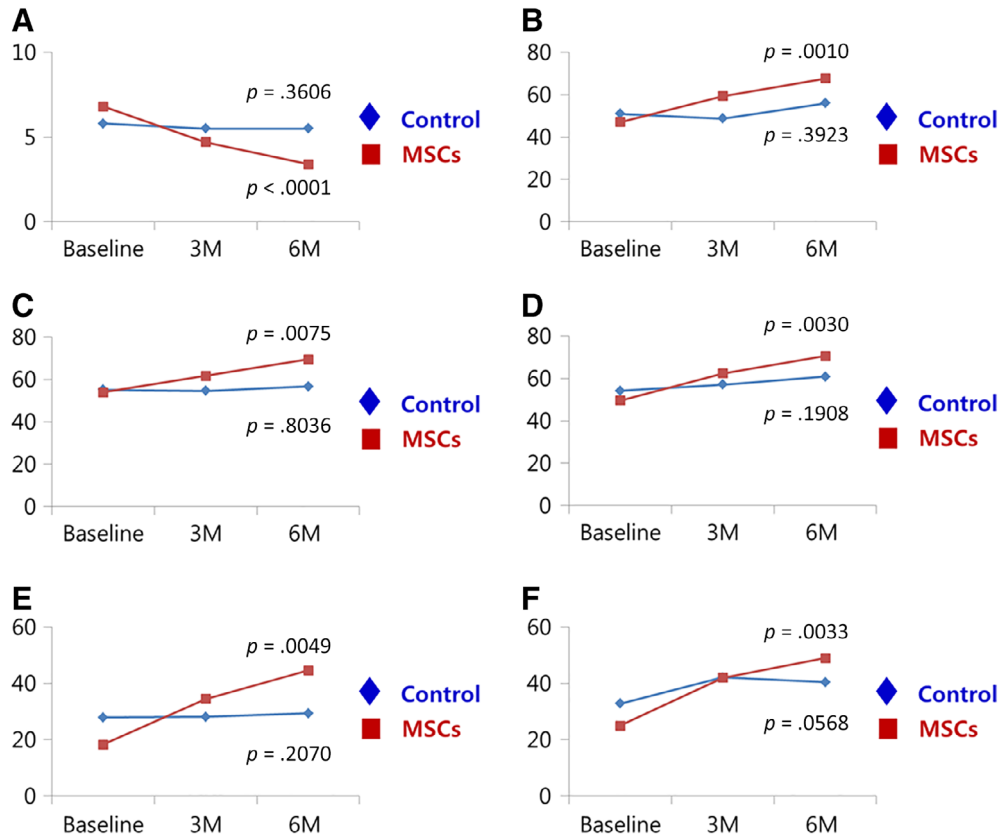


Figure 3. Changes in VAS for knee pain and KOOS score during the 6-month period after intra-articular injection in the MSC group and control group. The VAS and all subscores of the KOOS significantly increased over 6 months compared with baseline in only the MSC group. There were no significant improvements in the VAS and all subscores of the KOOS in the control group. **(A):** VAS for knee pain. **(B):** The pain subscore of the KOOS. **(C):** The symptoms subscore of the KOOS. **(D):** The activities of daily living subscore of the KOOS. **(E):** The sports subscore of the KOOS. **(F):** The quality of life subscore of the KOOS. Abbreviations: KOOS, Knee Injury and Osteoarthritis Outcome Score; MSC, mesenchymal stem cell; VAS, visual analog scale.

Table 2. Changes in the size of cartilage defect in MRI after injection

Size of cartilage defect in MRI, mm ^{2a}	MSC group		Control group		p value
	n	Mean ± SD	n	Mean ± SD	
Baseline	12	312.47 ± 270.97	12	320.02 ± 273.02	.4922 ^b
6 months	12	314.86 ± 267.33	12	355.61 ± 258.54	
Change amount of defect after the injection		2.39 ± 14.54		35.61 ± 58.80	.0051 ^b
p value		.5803 ^c		.0049 ^c	

^aCartilage defect means the grade 3 or 4 lesions by modified Noyes grading system [28] on MRI in the medial femoral condyle of each participant.

^bUnpaired *t* test was used to compare the difference of cartilage defect between the groups.

^cA paired *t* test and Wilcoxon signed-rank test were used to compare the cartilage defect at baseline and 6 months in each group. The statistical significance was set at *p* < .05.

Abbreviations: MRI, magnetic resonance imaging; MSC, mesenchymal stem cell.

was significantly increased (*p* = .0049). Moreover, there was a significant difference between the two groups in the amount of change in cartilage defect after the injection (*p* = .0051; Table 2; Fig. 4).

Safety Outcomes

Adverse events occurred in 10 (83%) patients in the MSC group and 7 (58%) patients in the control group (Table 3). There were no grade 4 or 5 adverse events by the NCI-CTCAE scale or serious adverse events. All adverse events of grade 3 by the NCI-CTCAE

scale were arthralgia, but those completely disappeared within 3 days. Treatment-related adverse events were reported in eight patients in the MSC group, including arthralgia in six patients and joint effusion in two patients, and in one patient in the control group with joint effusion. All treatment-related adverse events were recovered by the use of intermittent acetaminophen. No patients were discontinued from the study because of adverse events. There were no clinically important reports in the outcomes of physical examination, vital signs, and laboratory tests during the study.

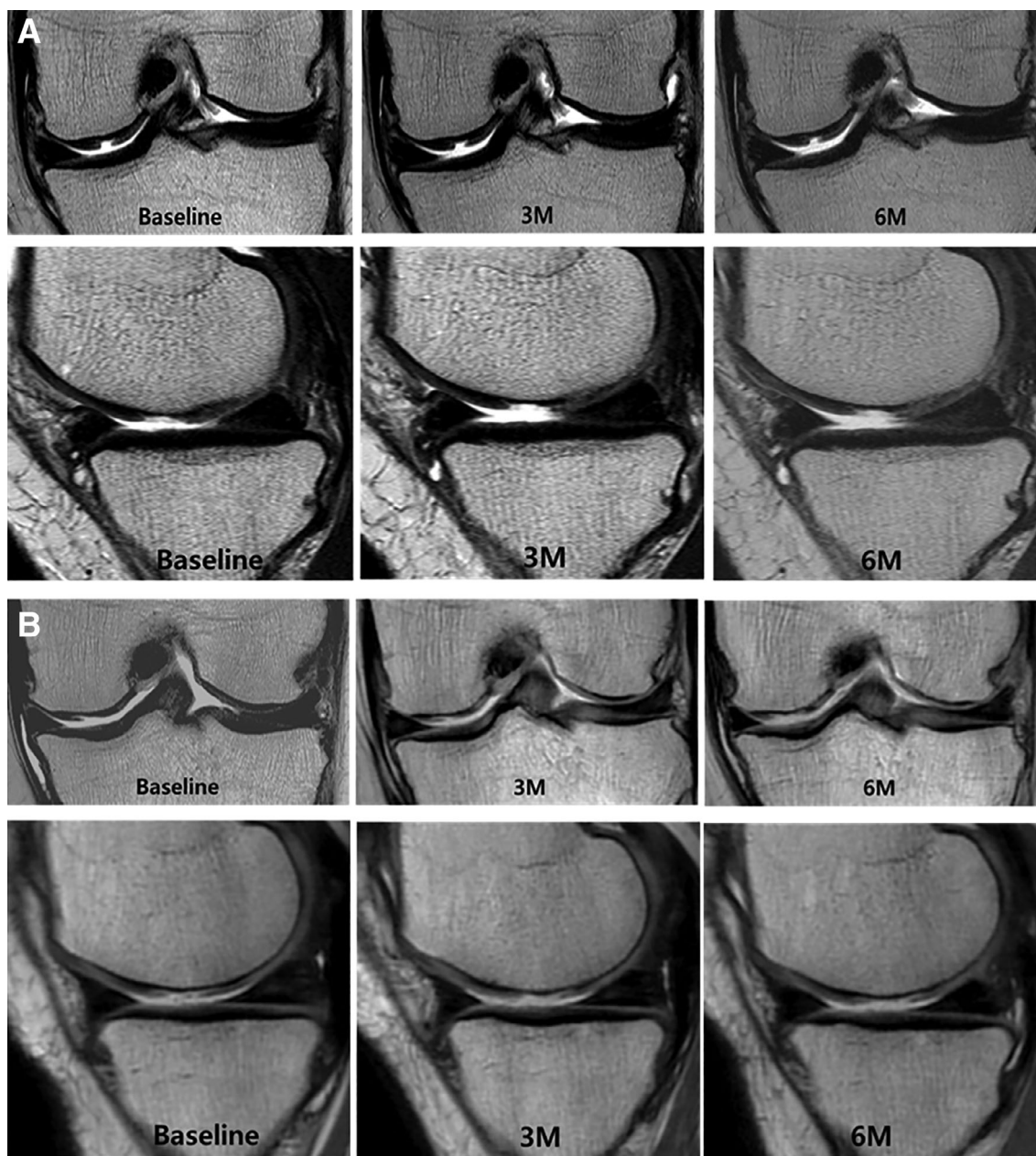


Figure 4. MRI evaluation of the size of cartilage defect in the MSC group and control group at baseline and at 3 and 6 months after injection. **(A):** Coronal and sagittal images of the medial femoral and tibial condyles before, 3 months after, and 6 months after injection of AD-MSCs. The size of cartilage defect of the medial femoral condyle in serial MRI scans did not change over 6 months of follow-up. **(B):** Coronal and sagittal images of the femoral and tibial condyles before, 3 months after, and 6 months after injection of normal saline. The size of cartilage defect of the medial femoral condyle in serial MRI scans significantly increased over 6 months of follow-up. Abbreviations: AD-MSCs, adipose-derived mesenchymal stem cells; MRI, magnetic resonance imaging; MSC, mesenchymal stem cell.

DISCUSSION

The most important finding of this study was that a single intra-articular injection of autologous AD-MSCs in patients with osteoarthritic knees led to satisfactory clinical and functional improvement without adverse events over 6 months of follow-up. All procedures were accompanied with the outpatient clinic setting. Patients in the MSC group demonstrated significantly improved WOMAC scores, which was the primary outcome of this study. This single injection of AD-MSCs significantly led to a 55% reduction in the WOMAC total score, 59%

in the WOMAC pain score, 54% in the WOMAC stiffness score, and 54% in the WOMAC physical function score at 6 months after injection. Previous studies [1, 2, 16, 19] showed that the clinical outcomes improved at 6 months after MSC injection. This is consistent with the results of this study. Moreover, similar to some previous studies [16, 19], clinical outcomes were well maintained even at 6 months after injection. This finding suggests that symptom improvement can be well maintained over 6 months with a single intra-articular MSC injection. Therefore, intra-articular injection of MSCs would be a viable option for the treatment of degenerative osteoarthritis of the

Table 3. Summary of adverse events

Summary of AEs	MSC group	Control group
Patients with AEs, <i>n</i> (%) ^a	10 (83)	7 (58)
Treatment-related	8 (67)	1 (8)
Patients with SAEs ^b	0	0
Treatment-related	0	0
AEs by grade, <i>n</i> ^c		
Grade 1	22	11
Grade 2	9	1
Grade 3	3	0
Grade 4	0	0
Grade 5	0	0

^aAn AE is defined as any undesired medical incident that does not necessarily have a cause-and-effect relationship with the treatment.

^bAn SAE is defined as any undesired medical incident that causes death, life threatening, hospitalization, disability, congenital abnormality, or birth death.

^cNCI-CTCAE scale.

Abbreviations: AEs, adverse events; MSC, mesenchymal stem cell; NCI-CTCAE, National Cancer Institute-Common Terminology Criteria for Adverse Events; SAEs, serious adverse events.

knee as a simple method without concomitant surgical procedures, and it is able to be carried out in the outpatient clinic.

Several types of MSCs have been used for an intra-articular injection in the treatment of knee osteoarthritis [1, 2, 16, 19]. Orozco et al. [1, 19] used autologous bone marrow (BM)-derived MSCs for the intra-articular injection. They reported significant improvement in clinical scores over 12 months after the injection. Vega et al. [16] performed a randomized controlled study of allogenic BM-MSCs in patients with K-L grade 2 to 4 osteoarthritis. They reported significantly improved pain and cartilage quality, but the efficacy for pain was smaller than that reported with autologous BM-MSCs [1]. However, direct comparisons are difficult because the former study [1] was uncontrolled. Both previous and present studies using high-dose AD-MSCs [2] showed similar improvements in pain VAS and WOMAC scores. In the previous study [2], a high dose of AD-MSCs was injected after concomitant arthroscopy. In contrast, in the present study, a single intra-articular injection of AD-MSCs was performed in the outpatient setting. Moreover, whereas the previous study [2] was an open-label test without a control group, the present study was a randomized, double-blinded, and placebo-controlled design. However, it is difficult to determine the actual differences in intra-articular injections of BM-MSCs and AD-MSCs because the researches differ in study design, cell type, presence of adjunctive therapy, and rehabilitation protocols [1, 2, 5, 16, 19]. Meanwhile, there are various options as to whether to use “autologous” or “allogeneic” MSCs for intra-articular injection [5, 16, 34]. Theoretically, autologous MSCs have been known to be safe because they do not result in antibody formation [5]. The risk of tumorigenesis, disease transmission, and possibility of host immune rejection after use of allogeneic MSCs is still a concern [20]. In contrast, donor site morbidity to harvest autologous MSCs would be a negative point compared with allogeneic MSCs [16]. Moreover, autologous MSCs should not be recommended for genetic disorders [35]. Rather, in patients with genetic disorders, allogeneic MSCs would be a reasonable option for the treatment [16, 35]. In a previous study [16] using allogeneic MSCs for intra-articular injections, few major adverse events were reported, and

improvements in clinical outcomes were similar to studies using autologous MSCs [1, 2, 19]. However, further clinical research including safety and efficacy evaluation would be necessary for clinical practice of an intra-articular injection of allogeneic MSCs.

Previous studies [1, 2, 16, 19] have reported chondral changes after the intra-articular injection of MSCs in patients with knee osteoarthritis. Some studies [1, 16, 19] measuring structural changes after MSCs injection reported on cartilage regeneration at 6 months after injection using T2 relaxation time and poor cartilage index on MRI. In the previous study [2], cartilage regeneration could be seen in the second-look arthroscopy at 6 months after the AD-MSCs injection. In the present study, we could not find significant cartilage regeneration in MRI at 6 months after the injection. However, the cartilage defect was increased in the control group but maintained in the MSC group ($p = .0051$). Moreover, unlike the previous study that recommended partial weight-bearing with crutches for 8 weeks after injection [2], we allowed normal daily activities without any restriction or support. Because Orozco et al. [19] reported a continuous improvement in cartilage quality over a 2-year follow-up from the baseline, we expect cartilage improvement in our series with a longer follow-up. Chondral changes over time will require further research.

Concerns about safety of MSCs remain among clinicians and patients. According to previous trials [16, 35–37], there were no major adverse events, but some patients commonly reported joint pain, swelling, and difficulty with movement in a temporary period. One previous systemic analysis [5] was performed with clinical trials on autologous BM-MSCs. The literature found no serious adverse events with a mean follow-up of 21 months. The evidences are consistent with the present study in that an intra-articular injection of MSCs appeared to be safe during the short-term period. Nonetheless, further research is necessary for mid- to long-term adverse events.

Our study had some limitations. First, a small number of patients participated in this randomized, double-blinded, and placebo-controlled study. It was performed as a pilot, phase IIb clinical trial, prior to multicenter and large cohort study in the phase III clinical trials. Second, because the WOMAC score was a primary outcome, this sample size is insufficient to adequately analyze the radiologic outcomes. Further larger sample size would be necessary to confirm these findings. Third, the follow-up period was 6 months. There might be unexpected outcomes regarding clinical efficacy, adverse events, and structural outcomes in the long-term follow-up. In the future, long-term studies with large sample sizes will be needed.

CONCLUSION

An intra-articular injection of autologous AD-MSCs provided satisfactory functional improvement and pain relief for patients with knee osteoarthritis in the outpatient setting, without causing adverse events at 6 months' follow-up. Larger sample size and long-term follow-up is required.

ACKNOWLEDGMENTS

We express our sincere appreciation to the patients who participated in this study. We also thank Dr. Jeong-Chan Ra, CEO of R-Bio, for his dedicated support; Ran Song, M.D., for performing

ultrasound-guided intra-articular injection as a blinded coworker; and Jung-Sook Lee, research nurse, for her valuable assistance. This study was supported by the R-Bio Co., Ltd. (NCT 02658344).

interpretation; and manuscript writing; W.J.: data analysis, and interpretation of the cartilage volume measure.

AUTHOR CONTRIBUTIONS

W.S.L., H.J.K.: collection and assembly of data, and manuscript writing; K.I.K.: conception, design, collection of data, interpretation, and manuscript writing; G.B.K.: assembly of data,

DISCLOSURE OF POTENTIAL CONFLICTS OF INTEREST

W.S.L., W.J., and K.I.K. reported receiving research grants from R-Bio Co., Ltd. The other authors indicated no potential conflicts of interest.

REFERENCES

- Orozco L, Munar A, Soler R et al. Treatment of knee osteoarthritis with autologous mesenchymal stem cells: A pilot study. *Transplantation* 2013;95:1535–1541.
- Jo CH, Lee YG, Shin WH et al. Intra-articular injection of mesenchymal stem cells for the treatment of osteoarthritis of the knee: A proof-of-concept clinical trial. *STEM CELLS* 2014;32:1254–1266.
- Carstairs A, Genever P. Stem cell treatment for musculoskeletal disease. *Curr Opin Pharmacol* 2014;16:1–6.
- Freitag J, Bates D, Boyd R et al. Mesenchymal stem cell therapy in the treatment of osteoarthritis: Reparative pathways, safety and efficacy—A review. *BMC Musculoskelet Disord* 2016;17:230.
- Peeters CM, Leijns MJ, Reijman M et al. Safety of intra-articular cell-therapy with culture-expanded stem cells in humans: A systematic literature review. *Osteoarthritis Cartilage* 2013;21:1465–1473.
- Barry F, Murphy M. Mesenchymal stem cells in joint disease and repair. *Nat Rev Rheumatol* 2013;9:584–594.
- Horie M, Choi H, Lee RH et al. Intra-articular injection of human mesenchymal stem cells (MSCs) promote rat meniscal regeneration by being activated to express Indian hedgehog that enhances expression of type II collagen. *Osteoarthritis Cartilage* 2012;20:1197–1207.
- Caplan AL. Why are MSCs therapeutic? New data: New insight. *J Pathol* 2009;217:318–324.
- Yang SH, Wu CC, Shih TT et al. In vitro study on interaction between human nucleus pulposus cells and mesenchymal stem cells through paracrine stimulation. *Spine (Phila Pa 1976)* 2008;33:1951–1957.
- Vezina Audette R, Lavoie-Lamoureux A, Lavoie JP et al. Inflammatory stimuli differentially modulate the transcription of paracrine signaling molecules of equine bone marrow multipotent mesenchymal stromal cells. *Osteoarthritis Cartilage* 2013;21:1116–1124.
- Acharya C, Adesida A, Zajac P et al. Enhanced chondrocyte proliferation and mesenchymal stromal cells chondrogenesis in coculture pellets mediate improved cartilage formation. *J Cell Physiol* 2012;227:88–97.
- Wu L, Prins HJ, Helder MN et al. Trophic effects of mesenchymal stem cells in chondrocyte co-cultures are independent of culture conditions and cell sources. *Tissue Eng Part A* 2012;18:1542–1551.
- Jeong SY, Kim DH, Ha J et al. Thrombospondin-2 secreted by human umbilical cord blood-derived mesenchymal stem cells promotes chondrogenic differentiation. *STEM CELLS* 2013;31:2136–2148.
- Le Blanc K, Ringden O. Immunomodulation by mesenchymal stem cells and clinical experience. *J Intern Med* 2007;262:509–525.
- Djouad F, Bouffi C, Ghannam S et al. Mesenchymal stem cells: Innovative therapeutic tools for rheumatic diseases. *Nat Rev Rheumatol* 2009;5:392–399.
- Vega A, Martin-Ferrero MA, Del Canto F et al. Treatment of knee osteoarthritis with allogeneic bone marrow mesenchymal stem cells: A randomized controlled trial. *Transplantation* 2015;99:1681–1690.
- Wei CC, Lin AB, Hung SC. Mesenchymal stem cells in regenerative medicine for musculoskeletal diseases: Bench, bedside, and industry. *Cell Transplant* 2014;23:505–512.
- Pers YM, Ruiz M, Noel D et al. Mesenchymal stem cells for the management of inflammation in osteoarthritis: State of the art and perspectives. *Osteoarthritis Cartilage* 2015;23:2027–2035.
- Orozco L, Munar A, Soler R et al. Treatment of knee osteoarthritis with autologous mesenchymal stem cells: Two-year follow-up results. *Transplantation* 2014;97:e66–e68.
- Gucciardo L, Lories R, Ochsenbein-Kolbe N et al. Fetal mesenchymal stem cells: Isolation, properties and potential use in perinatology and regenerative medicine. *BJOG* 2009;116:166–172.
- Kellgren JH, Lawrence JS. Radiological assessment of osteoarthrosis. *Ann Rheum Dis* 1957;16:494–502.
- Ra JC, Shin IS, Kim SH et al. Safety of intravenous infusion of human adipose tissue-derived mesenchymal stem cells in animals and humans. *Stem Cells Dev* 2011;20:1297–1308.
- Klein JA. The tumescent technique for lipo-suction surgery. *Am J Cosmetic Surg* 1987;4:263–267.
- Klein JA. Tumescent technique for local anesthesia improves safety in large-volume lipoaugmentation. *Plast Reconstr Surg* 1993;92:1085–1098.
- Rall WF, Fahy GM, Gregory M et al. Ice-free cryopreservation of mouse embryo at –196 C by vitrification. *Nature* 1985;313:573–575.
- Bellamy N, Buchanan WW, Goldsmith CH et al. Validation study of WOMAC: A health status instrument for measuring clinically important patient relevant outcomes to antirheumatic drug therapy in patients with osteoarthritis of the hip or knee. *J Rheumatol* 1988;15:1833–1840.
- Roos EM, Roos HP, Lohmander LS et al. Knee Injury and Osteoarthritis Outcome Score (KOOS)—development of a self-administered outcome measure. *J Orthop Sports Phys Ther* 1998;28:88–96.
- van der Woude JAD, Wiegant K, van Heerwaarden RJ et al. Knee joint distraction compared with high tibial osteotomy: A randomized controlled trial. *Knee Surg Sports Traumatol Arthrosc* 2017;25:876–886.
- Huizinga MR, Gorter J, Demmer A et al. Progression of medial compartmental osteoarthritis 2–8 years after lateral closing-wedge high tibial osteotomy. *Knee Surg Sports Traumatol Arthrosc* 2017;25:3679–3686.
- Cooke TD, Sled EA, Scudamore RA. Frontal plane knee alignment: A call for standardized measurement. *J Rheumatol* 2007;34:1796–1801.
- Kijowski R, Blankenbaker DG, Davis KW et al. Comparison of 1.5- and 3.0-T MR imaging for evaluating the articular cartilage of the knee joint. *Radiology* 2009;250:839–848.
- Basch E, Iasonos A, McDonough T et al. Patient versus clinician symptom reporting using the National Cancer Institute Common Terminology Criteria for Adverse Events: Results of a questionnaire-based study. *Lancet Oncol* 2006;7:903–909.
- Mouton JP, Mehta U, Rossiter DP et al. Interrater agreement of two adverse drug reaction causality assessment methods: A randomised comparison of the Liverpool Adverse Drug Reaction Causality Assessment Tool and the World Health Organization-Uppsala Monitoring Centre system. *PLoS One* 2017;12:e0172830.
- Wang D, Zhang H, Liang J et al. Allogeneic mesenchymal stem cell transplantation in severe and refractory systemic lupus erythematosus: 4 years of experience. *Cell Transplant* 2013;22:2267–2277.
- Saw KY, Anz A, Siew-Yoke Jee C et al. Articular cartilage regeneration with autologous peripheral blood stem cells versus hyaluronic acid: A randomized controlled trial. *Arthroscopy* 2013;29:684–694.
- Koh YG, Choi YJ. Infrapatellar fat pad-derived mesenchymal stem cell therapy for knee osteoarthritis. *Knee* 2012;19:902–907.
- Wong KL, Lee KB, Tai BC et al. Injectable cultured bone marrow-derived mesenchymal stem cells in varus knees with cartilage defects undergoing high tibial osteotomy: A prospective, randomized controlled clinical trial with 2 years' follow-up. *Arthroscopy* 2013;29:2020–2028.



See www.StemCellsTM.com for supporting information available online.