



ORIGINAL ARTICLE / *Musculoskeletal imaging*

# Treatment of degenerative meniscal tear with intrameniscal injection of platelets rich plasma



D. Guenoun<sup>a,b,\*</sup>, J. Magalon<sup>c,d</sup>, I. de Torquemada<sup>c</sup>,  
C. Vandeville<sup>c</sup>, F. Sabatier<sup>c,d</sup>, P. Champsaur<sup>a,b</sup>,  
C. Jacquet<sup>e</sup>, M. Ollivier<sup>e</sup>

<sup>a</sup> Department of Radiology, Sainte-Marguerite Hospital, Institute of Movement and Locomotion, AP–HM, 13009 Marseille, France

<sup>b</sup> CNRS, ISM, Inst Movement Sci, Aix Marseille Université, 13009 Marseille, France

<sup>c</sup> Inserm CIC BT 1409, Cell Therapy Department, Conception Hospital, AP–HM, 13000 Marseille, France

<sup>d</sup> INSERM, INRA, C2VN, Aix Marseille Université, 13000 Marseille, France

<sup>e</sup> CNRS, ISM UMR 7287, Department of Orthopedics and Traumatology, Institute of Movement and Locomotion, Aix Marseille Université, 13288 Marseille, France

## KEYWORDS

Platelet-rich plasma (PRP);  
Magnetic resonance imaging (MRI);  
Meniscal tear;  
Knee joint;  
Visual analog scale

## Abstract

**Purpose:** The purpose of this retrospective study was to describe our preliminary results of intrameniscal administration of platelet rich plasma (PRP) in patients with degenerative meniscal tears of the knee.

**Material and method:** Ten patients with degenerative meniscal tears according to the Stoller classification and without knee osteoarthritis were included. There were 7 men and 3 women with a mean age of  $40.4 \pm 13.6$  [SD] years (range: 18–59 years). Patients were prospectively assessed at baseline and 3- and 6-months after intra meniscal PRP administration. Evaluation included the knee injury and osteoarthritis outcome score (KOOS), pain visual analog scale, and return to competition and training. MRI follow-up was performed 6 months after PRP administration. Adverse events were recorded.

**Results:** Volume of injected PRP was standardized to 4.0 mL. Adverse events during PRP administration was moderate pain in 8 patients (8/10; 80%). Mean KOOS total score significantly improved from  $56.6 \pm 15.7$  (SD) to  $72.7 \pm 18.5$  (SD) ( $P=0.0007$ ). All six patients practicing sports regularly were able to recover competition or training. In seven patients who underwent MRI follow-up at 6 months, MRI showed stability of the meniscal tears and similar Stoller grades.

\* Corresponding author. Department of Radiology, Sainte-Marguerite Hospital, Institute for Locomotion, AP–HM, 13009 Marseille, France.  
E-mail address: [daphne.guenoun@ap-hm.fr](mailto:daphne.guenoun@ap-hm.fr) (D. Guenoun).

**Conclusion:** Intra-meniscal administration of PRP under ultrasound guidance directly into meniscal degenerative lesions is feasible and safe. Further randomized controlled studies are needed to definitely confirm the effectiveness of this procedure.

© 2019 Société française de radiologie. Published by Elsevier Masson SAS. All rights reserved.

The menisci, attached between the lateral and medial articular surface of the femur and tibia, are two wedge-shaped, semicircular, fibrocartilaginous structures that provide shock absorption and load transmission during dynamic movements through an innate resistance to compression, tension and shear forces [1]. Sport-related injuries are the most common causes of meniscal lesions, accounting for more than one third of all meniscal lesions [2,3]. Meniscus lesions are thought to be clinical manifestations of early-onset osteoarthritis since they have been shown to lead to fibrocartilage loss and potential joint space narrowing [4].

Meniscal injuries can be treated using surgical approaches. Of these, arthroscopic partial meniscectomy, which consists in removing torn meniscal fragments to relieve pain-attributed symptoms, is one of the most common orthopedic procedures performed in the United State. However, this procedure failed to show efficacy compared to placebo surgery (*i.e.*, sham surgery) [5].

Thus, non-surgical, conservative management is preferred with a wide variety of possibilities including oral non-steroidal anti-inflammatory drugs (NSAIDs), intra-articular administration of corticosteroid or hyaluronic acid. Indeed, interventional radiology techniques have a major role in pain management [6,7]. In this context, biological options have emerged to relieve pain and improve functions in these patients. Among them, platelet-rich plasma (PRP) is defined as an autologous plasma suspension of platelets, characterized by a greater platelet concentration than in physiological blood [8]. Activated platelets release growth factors (GFs) that are implied in reparative and regenerative processes. High levels of platelet-derived growth factors (PDGFs), transforming growth factor b1 (TGF-b1), vascular endothelial growth factor (VEGF), epidermal growth factor (EGF), insulin-like growth factor 1, or fibroblast growth factor found in PRP are especially known to play a critical role in cell proliferation, chemotaxis, cell differentiation, and angiogenesis [9]. Described as an easy, fast, effective, cheap, and safe (because of its autologous origin) product, PRP has been the subject of increased clinical interest in the orthopedic field. Evidence indicates that, compared with hyaluronic acid (HA) and saline, intra-articular PRP injection may have more benefits in pain relief and functional improvement in patients with symptomatic knee osteoarthritis at 1 year post injection [10]. However, one matter of importance is the lack of prior published studies assessing the effect of PRP on meniscal healing.

The purpose of this retrospective study was to describe our preliminary results of intra-meniscal administration of PRP in patients with degenerative meniscal tears of the knee.

## Materials and methods

### Patients

This study was performed after the approval from the Committee for the Safety of Health Products of our university hospital to routinely use PRP for musculoskeletal disease.

Individuals with systemic disease, those who were receiving anticoagulant treatment, pregnant women, patients with severe cardiovascular disorder and patients with a bleeding disorder were not considered for inclusion.

The study cohort consisted of 10 patients with a total of 10 degenerative meniscal tears without knee osteoarthritis. There were 7 men and 3 women, with a mean age of  $40.4 \pm 13.6$  (SD) years (range: 18–59 years) who underwent intrameniscal PRP injection under ultrasound guidance. Meniscal tears were grade 1 ( $n=2$ ), grade 2 ( $n=4$ ), grade 3 ( $n=4$ ) according to the magnetic resonance imaging (MRI) Stoller classification, with internal ( $n=6$ ) or external ( $n=4$ ) location [11]. Patient history, characteristic of meniscal lesion and, initial pain visual analog scale (VAS) and knee injury and osteoarthritis score (KOOS) are detailed in Table 1.

### PRP preparation method

After a four-step skin decontamination (antiseptic foaming solution, rinsing with sterile water, drying, and alcoholic dermal antiseptic), a nurse collected 18 mL of blood by venipuncture using a 21-Gauge needle filling one 20-mL syringe containing 2 mL of ACD-A (Fidia, Abano). The blood was transferred into the Hy Tissue 20 device (Fidia, Abano) before centrifugation using the Omnigrafter III (Fidia, Abano) at 3200 rpm during 10 minutes. The PRP was recovered using the Push Out system and 4 mL of PRP was sampled in a 5-mL syringe. A volume of 300  $\mu$ L from whole blood and each PRP preparation were sampled to determine platelets, leukocytes and red blood cells concentrations using automated hematology blood cell analyzers Sysmex XN-10 (Sysmex) and following recent guidelines [12]. Sterility was checked using 250  $\mu$ L of PRP sampled in Bactec culture bottles (Peds Plus Aerobic/F and Plus Anaerobic/F culture vials, containing each 40 mL of growth medium).

**Table 1** Baseline characteristics of 10 patients who underwent intra meniscal injection of Platelet Rich Plasma.

Patient #	Sex	Age	Meniscal location	Tear description	Stoller grade	Initial KOOS	Initial pain VAS
1	M	57	Right knee Internal	Horizontal Body and posterior horn	2	53	6
2	F	59	Left knee Internal	Horizontal Body and posterior horn	2	69	6
3	M	28	Right knee External	Horizontal Anterior horn	2	39	6
4	F	32	Left knee external	Complex Body	3	53	7
5	F	44	Right knee External	Horizontal Posterior horn	1	64	5
6	M	34	Left knee External	Horizontal Posterior horn	2	75	5
7	M	32	Right knee Internal	Oblique Body and posterior horn	3	59	5
8	M	18	Right knee Internal	Horizontal Posterior horn	1	65	4
9	M	47	Right knee Internal	Complex Body	3	25	5
10	M	53	Right knee Internal	Complex Body and posterior horn	3	61	8

KOOS: knee injury and osteoarthritis score; VAS: visual analog scale; M: male; F: female.

Bactec culture bottles were incubated at 37 °C for a total of 10 days, and automated readings were taken every 10 min. Detection of organisms resulted in an audible alarm and automatic recording of time to detection.

### Intrameniscal tear PRP administration

Ultrasound-guided subcutaneous local anesthesia was performed before the procedure. Ultrasound-guided injection of PRP was performed by the same radiologist (D.G.) specialized in musculoskeletal imaging. When meniscal tear was seen on ultrasound, an intra-meniscal injection of 0.5 mL of PRP in the tear was first performed. Then 1.5 mL was injected in the meniscal wall and 2 mL in the peri-meniscal space.

When meniscal tear was not seen on the ultrasound, 2 mL of PRP were injected in the meniscal wall [13] and 2 mL in the peri-meniscal space. The injection was made with a 21- or 25-Gauge needle based on thickness of the soft tissue. Pain VAS was monitored during the intra meniscal injection.

### Data collection and follow-up

Safety of the procedure was graded according the CIRSE classification system [14]. Patients were prospectively assessed at baseline and at 3- and 6-months after PRP administration. After the procedure, the patients were evaluated using KOOS, pain VAS (with a 0-100 mm scale), and ability to return to competition and training. Adverse events were recorded. Follow-up MRI examinations were performed at 6 months

after PRP injection using a 1.5 T MRI unit (Ingenia®, Philips Healthcare). The MRI protocol included T1-weighted images in the sagittal plane (field of view, 180 mm; slice thickness, 3.5 mm; slice number, 28), three-dimensional fat suppressed spectral attenuated inversion recovery (SPAIR) images (field of view, 180 mm; slice number, 400) with 2-mm thickness multiplanar reformatted images and fat-suppressed SPAIR images in the coronal plane (field of view, 175 mm; slice thickness, 3 mm; slice number, 24) [15]. Meniscal tears were reassessed according Stoller classification and compared to initial MRI findings. Platelets increase factors compared to whole blood corresponded to platelets or leukocytes concentration in PRP divided by platelets or leukocytes concentration in whole blood. Relative composition of PRP corresponds to the percentage of platelets, red blood cells and leukocytes within each PRP sample. A pure PRP was defined by a percentage of platelets in PRP > 90%. Responders were defined as patients presenting an improvement of at least 10 points of KOOS total score [16].

### Statistical analysis

Statistical analyses were performed with SPSS statistical software, version 16.0 (SPSS, Chicago, IL). Significance was set at  $P < 0.05$ . Quantitative data were expressed as mean  $\pm$  standard deviation (SD). All median, interquartiles ranges (Q1, Q3) and ranges were provided in corresponding table. The differences in KOOS score were analyzed by non-parametric one-way analysis of variance (ANOVA) taking into repeated measures over the time. Difference in

**Table 2** Biological characteristics of platelet rich plasma in ten patients.

Variable	Mean $\pm$ SD [range]	Median (Q1, Q3)
<b>Blood</b>		
Volume of whole blood collected (mL)	18.0 $\pm$ 0.0 [18–18]	–
Red blood cell concentration (T/L)	4.37 $\pm$ 0.49 [3.59–4.91]	4.63 (3.76–4.72)
Platelet concentration (G/L)	265 $\pm$ 106 [172–467]	221 (183–329)
Leukocyte concentration (G/L)	4.72 $\pm$ 1.72 [2.26–8.60]	4.91 (3.49–5.40)
<b>PRP</b>		
Volume of PRP injected (ml)	4.0 $\pm$ 0.0 [4–4]	–
Red blood cells concentration (T/L)	0.02 $\pm$ 0.01 [0.01–0.03]	0.015 (0.01–0.0225)
Platelets concentration (G/L)	497 $\pm$ 154 [313–756]	524.5 (339.8–623.3)
Leukocytes concentration (G/L)	0.58 $\pm$ 0.51 [0.1–1.84]	0.45 (0.28–0.785)
Quantity of injected red blood cell (millions)	70 $\pm$ 30 [34–120]	60 (39–104)
Quantity of injected red blood cells (%)	3.4 $\pm$ 1.4 [1.31–5.42]	3.08 (2.37–5.08)
Quantity of injected platelets (millions)	1999 $\pm$ 616 [1250–3023]	1999 (1357–2478)
Quantity of injected platelets (%)	96.5 $\pm$ 1.5 [94.34–98.68]	96.75 (94.83–97.54)
Quantity of injected leukocytes (millions)	2 $\pm$ 2 [0.4–7.4]	1.8 (1.1–3.1)
Quantity of injected leukocytes (%)	0.1 $\pm$ 0.1 [0.01–0.31]	0.1 (0.05–0.23)
Increase factor in platelets	2.0 $\pm$ 0.5 [1.2–3.13]	1.87 (1.79–2.07)
Increase factor in leukocytes	0.1 $\pm$ 0.1 [0.01–0.51]	0.09 (0.06–0.195)

PRP: platelet rich plasma; SD: standard deviation.

VAS between baseline and 6 months was analyzed using a Wilcoxon matched pair test.

## Results

### Biological characteristics of PRP

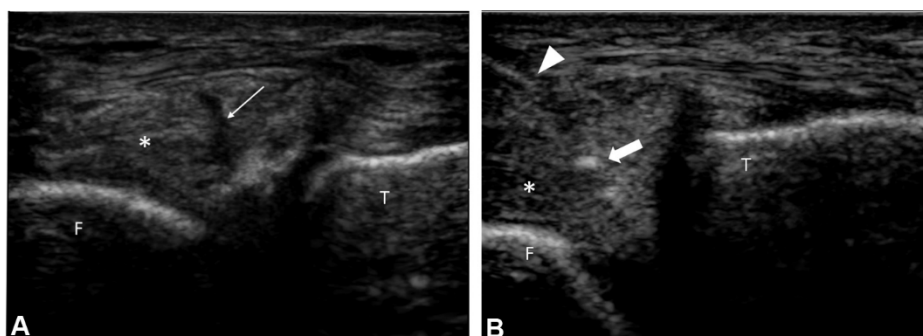
Table 2 summarizes biological characteristics of injected PRP. The final injected volume of PRP was 4.0 mL in all patients. The mean increase in platelets and leukocytes factors compared with blood were  $1.4 \pm 0.4$  (SD) and  $0.1 \pm 0.1$  (SD), respectively. The percentage of platelets was  $96.5 \pm 1.5$  (SD) % with very few contaminations of red blood cells (RBCs) ( $3.4 \pm 1.4\%$ ) and leukocytes ( $0.1 \pm 0.1\%$ ). Mean number of injected platelets was  $2.0 \pm 0.6$  (SD) billion. Injected PRP was sterile in all patients (10/10; 100%).

### Adverse events

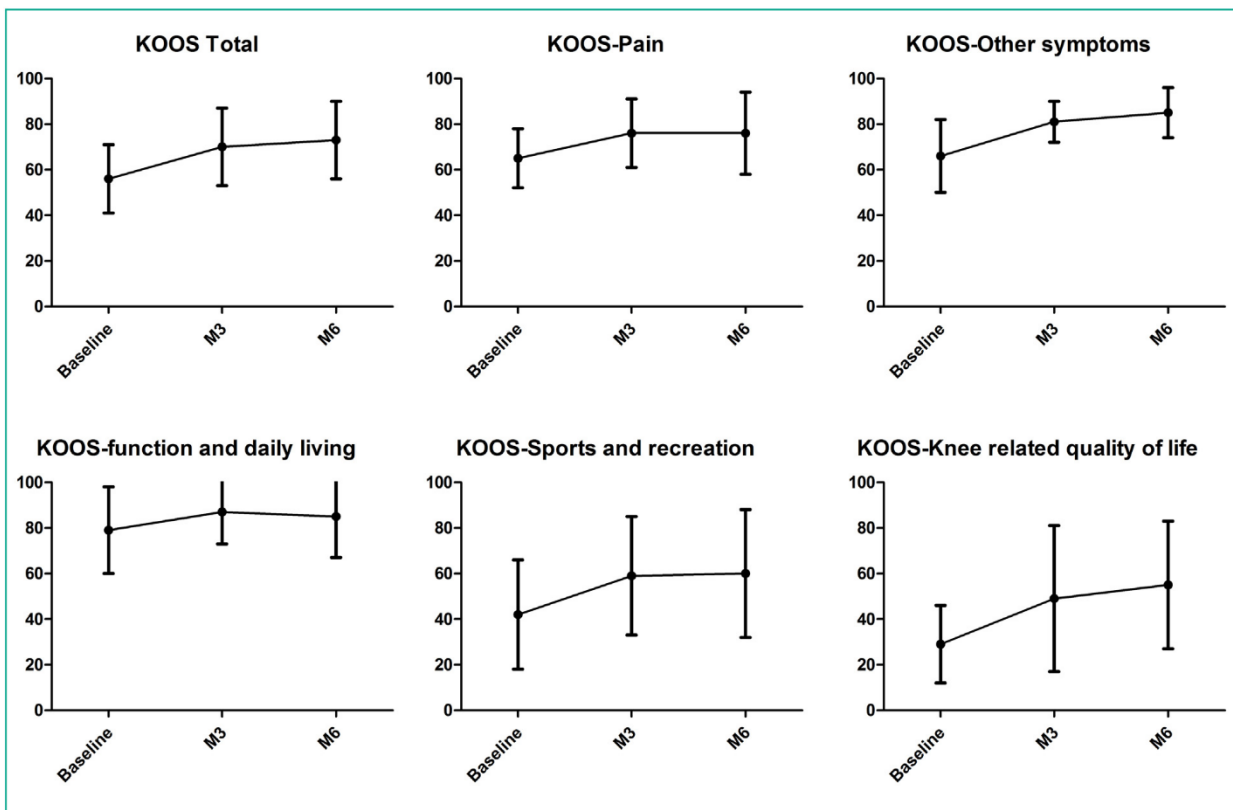
PRP injection was performed in meniscal tear in five patients (Fig. 1) whereas for five of them, meniscal tear was not seen on ultrasound. No major complications were reported during and after the injection of PRP. Eight patients described pain at injection with a mean VAS of  $50 \pm 31$  (SD) mm (range: 0–10 mm). Pain resolved within 10 minutes after the injection.

### Effect of single PRP injection in meniscal tears

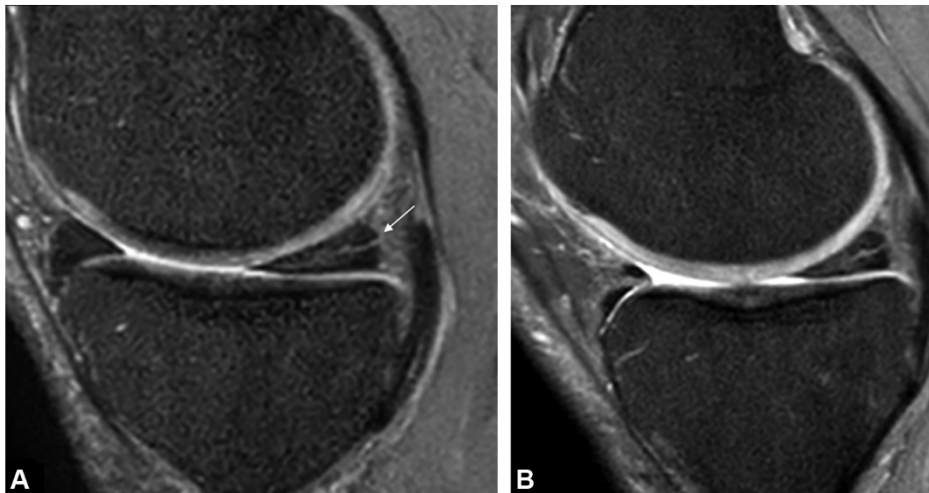
Single intra-meniscal injection of PRP was safe for all patients with only grade I adverse events with the absence of adverse events until 6 months after the procedure. Intra meniscal injection of PRP was effective in improving knee functional status with a significant increase in KOOS total



**Figure 1.** Ultrasound-guided injection of platelet-rich plasma in the medial meniscus in a 45-year-old man. A. Ultrasound image of medial femoro-tibial joint shows medial meniscus (\*) (F: femur; T: tibia) with meniscal tear (white arrow). B. Ultrasound image shows needle (arrowhead) positioned in the meniscal tear. Platelet-rich plasma can be seen to fill the meniscal tear (arrow).



**Figure 2.** Graphs show changes in osteoarthritis outcome score (KOOS) scores after intra-meniscal injection of platelet-rich plasma.



**Figure 3.** MRI findings before platelet-rich plasma injection and at 6 months follow-up in a 35-year-old man with meniscal tear. A. Initial fat-suppressed T2-weighted MR image in the sagittal plane shows a horizontal tear of the posterior horn and meniscal body (arrow) corresponding to a grade 2 meniscal lesion according to Stoller classification. B. Fat-suppressed T2-weighted MR image 6 months after platelet-rich plasma injection shows no changes in MRI features of meniscal tear.

score from  $56.6 \pm 15.7$  (SD) to  $72.7 \pm 18.5$  (SD) ( $P=0.0007$ ) 6 months after the procedure. This significant difference was also observed in the stiffness and other symptoms ( $P=0.0013$ ), function in daily living ( $P=0.0190$ ) and quality of life ( $P=0.0060$ ) KOOS subscales 6 months after the procedure (Fig. 2, Table 3). This corresponded to a responder rate of 55.6% (5/9) at 3 months and 60% (6/10) at 6 months according minimal clinically important change in

KOOS total score. Assessment of pain through VAS resulted in a decrease from baseline ( $57.0 \pm 11.6$  [SD] mm) compared to 6 months after the procedure ( $33.0 \pm 29.0$  [SD] mm) ( $P=0.18$ ) (Table 3) without reaching significance. No significant differences were observed in KOOS total score and pain VAS between the patients injected or not in the meniscal tear. Six months after PRP administration, all patients practicing sports regularly ( $n=6$ ) were able to return to

**Table 3** ANOVA results from KOOS score (total and subscale) and pain VAS after intra meniscal injection of platelet-rich plasma.

	Baseline	At 3 months	At 6 months	<i>P</i>
<b>KOOS total</b>				
Mean ± SD	56.6 ± 15.7	70.2 ± 16.8	72.7 ± 18.5	<b>0.0007</b>
Median (Q1–Q3) [range]	61.0 (46.0–67.0) [25.0–75.0]	73.0 (60.5–77.0) [38.0–99.0]	74.0 (66.5–84.0) [33.0–100.0]	
<b>KOOS other symptoms</b>				
Mean ± SD	68.7 ± 15.3	81.4 ± 9.2	84.9 ± 10.5	<b>0.0013</b>
Median (Q1–Q3) [range]	71.4 (60.7–75.0) [39.3–96.4]	78.6 (76.8–91.1) [64.3–92.9]	89.0 (75.0–92.9) [67.9–100.0]	
<b>KOOS pain</b>				
Mean ± SD	64.5 ± 14.1	75.6 ± 15.1	76.2 ± 17.6	0.0570
Median (Q1–Q3) [range]	66.7 (59.7–76.4) [33.3–80.6]	77.8 (66.7–84.7) [47.2–100.0]	75.0 (63.9–91.7) [43.8–100.0]	
<b>KOOS function in daily living</b>				
Mean ± SD	79.2 ± 20.1	86.8 ± 14.3	85.1 ± 17.5	<b>0.0190</b>
Median (Q1–Q3) [range]	87.5 (70.6–91.2) [32.4–97.1]	89.7 (83.8–94.9) [51.5–100]	90.0 (74.2–99.2) [46.7–100]	
<b>KOOS sport and recreation</b>				
Mean ± SD	40.1 ± 24.9	58.5 ± 25.8	60.9 ± 28.5	0.1066
Median (Q1–Q3) [range]	50.0 (17.5–55.6) [0–70.0]	66.7 (35.0–75.0) [20.0–100.0]	58.3 (50.0–80.0) [0.0–100]	
<b>KOOS quality of life</b>				
Mean ± SD	30.6 ± 18.1	48.6 ± 32.4	56.2 ± 28.1	<b>0.0060</b>
Median (Q1–Q3) [range]	31.3 (15.6–43.8) [0–56.3]	50.0 (21.9–75.0) [21.9–100.0]	56.3 (40.6–75.0) [0.0–100.0]	
<b>Pain VAS</b>				
Mean ± SD	57.0 ± 11.6	N.P.	36.3 ± 31.1	0.18
Median (Q1–Q3) [range]	55.0 (50.0–62.5) [40.0–80.0]		35.0 (2.5–70.0) [0–70.0]	

KOOS: knee injury and osteoarthritis score; VAS: visual analog scale; N.P.: not performed due to > 50% missing data. Bold indicates significant difference.

competition or training activities. Seven patients underwent follow-up MRI examination at 6 month that showed stability of the meniscal tears and similar Stoller grades (Fig. 3). One patient had a parameniscal cyst which disappeared on MRI at 6 months.

## Discussion

This purpose of this pilot study was to evaluate the feasibility, safety and efficiency of PRP intrameniscal injection for patient suffering from degenerative meniscal lesions. Although no radiological healing process could be observed at 6 months' follow-up, significant improvement in function scores and pain decrease in treated patients was obtained.

The management of degenerative meniscal lesions has been the subject of recent recommendations reinforcing

the place of conservative treatment as a first-line therapeutic option [17]. Surgical treatment is restricted to failed medical treatment in patients with "mechanical" symptoms but the definition of an ideal conservative treatment is still debated. Some studies recommend the use of physiotherapy, which results in similar functional outcomes that surgical treatment [18–20]. Intra-articular injection of hyaluronic acid or corticosteroid is another widely used alternate option. These practices are based on evidence of the effectiveness of intra-articular injections to improve mid-term functional outcomes in patients with moderate knee arthritis but no evidence exists regarding their efficacy to relieve pain in patient suffering from degenerative meniscal lesions [21].

Recent studies have focused on the use of PRP in osteoarthritis. The effects of PRP in these studies included chondrocyte and mesenchymal stem cell proliferation

increase, proteoglycan and type II collagen deposition. PRP was also found to increase chondrocytes viability and migration chondrogenic mesenchymal stem cells differentiation or to decrease cytokines catabolic effect [22]. Cerza et al. demonstrated in a randomized controlled trial, that PRP results in a better clinical outcome than hyaluronic acid (WOMAC score, 65.1 and 36.5 in the HA and ACP groups, respectively;  $P < .001$  at 24 weeks) in moderate knee arthritis (Grade < 3) [23].

Concerning the feasibility of intrameniscal injection, a previous cadaveric study has evaluated the accuracy of ultrasound-guided latex injection into the body and posterior horns of medial and lateral menisci [24]. After dissection, 17 of 20 injections were accurately performed. Two of 3 inaccurate injections infiltrated the posterior horn of the medial meniscus instead of the targeted meniscal body. One inaccurate lateral meniscus injection did not contain latex despite sonographically accurate needle placement [24]. As in our study, no neurovascular complications were observed.

In our pilot study, ultrasound-guided injections of PRP was feasible, allowing accurate and safe delivery of PRP into bodies and posterior horns of the medial and lateral menisci. However, in three patients, the degenerative lesions were not visible on ultrasound, and PRP injections were performed inside of the menisci walls. During this procedure, we only observed during the first ten minutes after injection a slight increase in patients' pain as assessed by the VAS, which confirms the acceptability of this treatment. No differences were found in terms of pain observed during the procedure or clinical outcomes during follow-up for the five patients that received an intra-meniscus tear injection.

Concerning PRP efficacy, the few published *in-vitro* studies reported contradictory results. Ishida et al. investigated whether PRP enhances meniscal tissue regeneration in vitro and in vivo [25]. They observed that PRP not only enhances proliferation of meniscal cells but also promotes glycosaminoglycan's synthesis in vitro [25]. To test the in vivo effect, PRP with gelatin hydrogel (GH) was injected into the 1.5 mm diameter full thickness meniscus defect of the rabbits. These researchers found that histologic scoring of the defect sites was significantly better in a PRP with GH treated group 12 weeks after PRP injection, suggesting that PRP enhances the healing of meniscus lesion. Another study confirmed the positive effect of FGF-2, which is one of the growth factors released from platelets [26]. This study showed that GH incorporating FGF-2 enhanced the healing of meniscus horizontal tear (4 mm in width and 2 mm in length) in rabbits [26]. At 4, 8, and 12 weeks after surgery, histologic healing scores were significantly higher in the GH with FGF-2 treated group than a GH without FGF-2 group. In another study, Shin et al. investigated the effect of leukocyte-rich PRP (L-PRP) on potential healing of the horizontal medial meniscus tears in a rabbit model [27]. A horizontal medial meniscus tear was created in both knees of nine rabbits. Left or right knees were randomly assigned to an L-PRP group, or a control group. 0.5 mL of L-PRP from 10 mL of each rabbit's whole blood was prepared and injected into the horizontal tears in L-PRP group. Nothing was applied in control group specimen's knees. The histological assessment of meniscus healing performed at two, four, and six weeks after surgery showed no significant differences of quantitative histologic

scoring between two groups. But the sample size was too small and the evaluation time too short to detect differences of histologic scoring system between the two groups. Regarding in vivo results, to our knowledge no other studies have attempted to evaluate the efficacy of PRP in local injection for human meniscal degenerative lesions.

Although we observed a significant improvement in several functional scores, we did not observe any MRI healing of these lesions. Several hypotheses can be suggested. First, PRP does not have a healing effect on these lesions and the good functional results observed are due to an anti-inflammatory effect of PRP [28]. Second, the scar tissue obtained has a different MRI signal than healthy meniscus appearance. Third, our follow-up is too short to observe changes in MRI presentation.

Our results should be interpreted with the following limitations. First we conducted a pilot study to evaluate the feasibility of the PRP intra-meniscal injection and only 10 patients were included with no control group, which limits the interpretation of the clinical efficacy of PRP. Also, we have missing data for some scores and for 6 months MRI due to the routine care design of the study.

In conclusion, we reported here the first human clinical study to assert the feasibility of infiltration of PRP under US control directly into meniscal degenerative lesions. Although the functional results are encouraging, they will have to be confirmed by a randomized controlled study with a higher number of patients in order to affirm the effectiveness of this treatment.

## Informed consent and patient details

The authors declare that this report does not contain any personal information that could lead to the identification of the patient(s).

The authors declare that they obtained a written informed consent from the patients and/or volunteers included in the article. The authors also confirm that the personal details of the patients and/or volunteers have been removed.

## Funding

This work did not receive any grant from funding agencies in the public, commercial, or not-for-profit sectors.

## CRedit authorship contribution statement

All authors attest that they meet the current International Committee of Medical Journal Editors (ICMJE) criteria for Authorship.

Daphne Guenoun: write the manuscript, Conceptualization, Methodology, Supervision, editing, imaging, injection of PRP, medical consultation.

Jeremy Magalon: PRP preparation, Conceptualization, Methodology, writing, reviewing, statistic.

Ignacio De Torquemada: PRP preparation.

Christophe Vandeville: data computing, statistic.

Florence Sabatier: methodology, supervision.

Pierre Champsaur: Conceptualization, Methodology, Supervision.

Christophe Jacquet: medical consultation.

Mathieu Ollivier: medical consultation, writing, review.

## Disclosure of interest

The authors declare that they have no competing interest in relation with this article.

## References

- [1] Englund M. Meniscal tear—a feature of osteoarthritis. *Acta Orthop Scand* 2004;75:1–45.
- [2] Baker BE, Peckham AC, Puppato F, Sanborn JC. Review of meniscal injury and associated sports. *Am J Sports Med* 1985;13:1–4.
- [3] Steinbrück K. Epidemiology of sports injuries—25-year-analysis of sports orthopedic-traumatologic ambulatory care. *Sportverletz. Sportschaden Organ Ges Orthopadisch-Traumatol Sportmed* 1999;13:38–52.
- [4] Blanke F, Vavken P, Haenle M, Von Wehren L, Pagenstert G, Majewski M. Percutaneous injections of platelet rich plasma for treatment of intrasubstance meniscal lesions. *Muscles Ligaments Tendons J* 2015;5:162–6.
- [5] Sihvonen R, Paavola M, Malmivaara A, Järvinen TLN. Finnish Degenerative Meniscal Lesion Study (FIDELITY): a protocol for a randomized, placebo surgery controlled trial on the efficacy of arthroscopic partial meniscectomy for patients with degenerative meniscus injury with a novel “RCT within-a-cohort” study design. *BMJ Open* 2013;3:e002510.
- [6] Filippiadis D, Charalampopoulos G, Mazioti A, Alexopoulou E, Vrachliotis T, Brountzos E, et al. Interventional radiology techniques for pain reduction and mobility improvement in patients with knee osteoarthritis. *Diagn Interv Imaging* 2019;100:391–400.
- [7] Filippiadis D, Tutton S, Kelekis A. Pain management: the rising role of interventional oncology. *Diagn Interv Imaging* 2017;98:627–34.
- [8] Marx RE. Platelet-rich plasma (PRP): what is PRP and what is not PRP? *Implant Dent* 2001;10:225–8.
- [9] Sánchez-González DJ, Méndez-Bolaina E, Trejo-Bahena NI. Platelet-rich plasma peptides: key for regeneration. *Int J Pept* 2012;2012:532519.
- [10] Dai WL, Zhou AG, Zhang H, Zhang J. Efficacy of platelet-rich plasma in the treatment of knee osteoarthritis: a meta-analysis of randomized controlled trials. *Arthroscopy* 2017;33:659–70.
- [11] Stoller DW, Martin C, Crues JV, Kaplan L, Mink JH. Meniscal tears: pathologic correlation with MR imaging. *Radiology* 1987;163:731–5.
- [12] Graiet H, Lokchine A, Francois P, Velier M, Grimaud F, Loyens M, et al. Use of platelet-rich plasma in regenerative medicine: technical tools for correct quality control. *BMJ Open Sport Exerc Med* 2018;4:e000442.
- [13] Clément M, Marc B, Alain L, Patrice G, Francois L, Igor B. Meniscal pain: US-guided meniscal wall infiltration versus partial meniscectomy: a comparative study. *Int J Sports Exerc Med* 2018;4:086.
- [14] Filippiadis DK, Binkert C, Pellerin O, Hoffmann RT, Krajina A, Pereira PL. Cirse quality assurance document and standards for classification of complications: the Cirse Classification System. *Cardiovasc Intervent Radiol* 2017;40:1141–6.
- [15] Lecouvet F, Van Haver T, Acid S, Perlepe V, Kirchgessner T, Vande Berg B, et al. Magnetic resonance imaging (MRI) of the knee: identification of difficult-to-diagnose meniscal lesions. *Diagn Interv Imaging* 2018;99:55–64.
- [16] Collins NJ, Misra D, Felson DT, Crossley KM, Roos EM. Measures of knee function: International Knee Documentation Committee (IKDC) Subjective Knee Evaluation Form, Knee Injury and Osteoarthritis Outcome Score (KOOS), Knee Injury and Osteoarthritis Outcome Score Physical Function Short Form (KOOS-PS), Knee Outcome Survey Activities of Daily Living Scale (KOS-ADL), Lysholm Knee Scoring Scale, Oxford Knee Score (OKS), Western Ontario and McMaster Universities Osteoarthritis Index (WOMAC), Activity Rating Scale (ARS), and Tegner Activity Score (TAS). *Arthritis Care Res* 2011;63:S208–28.
- [17] Beaufils P, Becker R, Kopf S, Englund M, Verdonk R, Ollivier M, et al. Surgical management of degenerative meniscus lesions: the 2016 ESSKA Meniscus Consensus. *Joints* 2017;5:59–69.
- [18] Herrlin S, Hällander M, Wange P, Weidenhielm L, Werner S. Arthroscopic or conservative treatment of degenerative medial meniscal tears: a prospective randomised trial. *Knee Surg Sports Traumatol Arthrosc* 2007;15:393–401.
- [19] Herrlin SV, Wange PO, Lapidus G, Hällander M, Werner S, Weidenhielm L. Is arthroscopic surgery beneficial in treating non-traumatic, degenerative medial meniscal tears? A five-year follow-up. *Knee Surg Sports Traumatol Arthrosc* 2013;21:358–64.
- [20] Katz JN, Brophy RH, Chaisson CE, De Chaves L, Cole BJ, Dahm DL, et al. Surgery versus physical therapy for a meniscal tear and osteoarthritis. *N Engl J Med* 2013;368:1675–84.
- [21] Tammachote N, Kanitnate S, Yakumpor T, Panichkul P. Intra-articular, single-shot Hylan G-F 20 hyaluronic acid injection compared with corticosteroid in knee osteoarthritis: a double-blind, randomized controlled trial. *J Bone Joint Surg Am* 2016;98:885–92.
- [22] Smyth NA, Murawski CD, Fortier LA, Cole BJ, Kennedy JG. Platelet-rich plasma in the pathologic processes of cartilage: review of basic science evidence. *Arthroscopy* 2013;29:1399–409.
- [23] Cerza F, Carni S, Carcangiu A, Di Vavo I, Schiavilla V, Pecora A, et al. Comparison between hyaluronic acid and platelet-rich plasma, intra-articular infiltration in the treatment of gonarthrosis. *Am J Sports Med* 2012;40:2822–7.
- [24] Baria MR, Sellon JL, Lueders D, Smith J. Sonographically guided knee meniscus injections: feasibility, techniques, and validation. *PM R* 2017;9:998–1005.
- [25] Ishida K, Kuroda R, Miwa M, Tabata Y, Hokugo A, Kawamoto T, et al. The regenerative effects of platelet-rich plasma on meniscal cells in vitro and its in vivo application with biodegradable gelatin hydrogel. *Tissue Eng* 2007;13:1103–12.
- [26] Narita A, Takahara M, Sato D, Ogino T, Fukushima S, Kimura Y, et al. Biodegradable gelatin hydrogels incorporating fibroblast growth factor 2 promote healing of horizontal tears in rabbit meniscus. *Arthroscopy* 2012;28:255–63.
- [27] Shin KH, Lee H, Kang S, Ko YJ, Lee SY, Park JH, et al. Effect of leukocyte-rich and platelet-rich plasma on healing of a horizontal medial meniscus tear in a rabbit model. *BioMed Res Int* 2015;2015:179756.
- [28] Mazzocca AD, McCarthy MBR, Intravia J, Beitzel K, Apostolakis J, Cote MP, et al. An in vitro evaluation of the anti-inflammatory effects of platelet-rich plasma, ketorolac, and methylprednisolone. *Arthroscopy* 2013;29:675–83.