

Available online at www.sciencedirect.com

ScienceDirect

British Journal of Oral and Maxillofacial Surgery xxx (2017) xxx–xxx

BRITISH
Journal of
Oral and
Maxillofacial
Surgerywww.bjoms.com

Long-term therapeutic effects of dextrose prolotherapy in patients with hypermobility of the temporomandibular joint: a single-arm study with 1-4 years' follow up

H. Refai

Department of Oral and Maxillofacial Surgery, Faculty of Oral and Dental Medicine, Cairo University, Cairo, Egypt

Received 29 July 2016; accepted 1 December 2016

Abstract

The aim was to analyse the short-term and long-term therapeutic efficacy of dextrose prolotherapy for dislocation or subluxation (hypermobility) of the temporomandibular joint (TMJ). Sixty-one patients with symptomatic hypermobility of the TMJ were included in this single-arm prospective study, in which they were each given four sessions of intra-articular and pericapsular injections six weeks apart. Each injection comprised 10% dextrose/mepivacaine solution 3 ml. Clinical outcomes including severity of pain on movement according to the numerical rating scale (NRS), maximal interincisal opening, clicking, and frequency of locking were measured before treatment (T1), during treatment (T2) (just before the third session of injections), at the short-term follow-up (T3) (three months after treatment), and at the long-term follow-up (T4) (1-4 years after treatment). Condylar translation and osseous changes of each joint were evaluated at T1 and T4 using tomography. There was significant reduction in all variables by T2 ($p < 0.001$, $p < 0.001$, $p = 0.006$, and $p < 0.001$). The pain scores ($p < 0.001$) and clicking ($p < 0.001$) had decreased significantly by T3. Linear tomograms of each joint at T1 and T4 showed no alteration in the morphology of the bony components of the joint, and at T4, tomographic open views of all joints showed condylar hypertranslation. Dextrose prolotherapy provided significant and sustained reduction of pain and recovery of constitutional symptoms associated with symptomatic hypermobility of the TMJ without changing either the position of the condyle or the morphology of the bony components of the joint.

© 2017 The British Association of Oral and Maxillofacial Surgeons. Published by Elsevier Ltd. All rights reserved.

Keywords: dextrose prolotherapy; intra-articular injection; TMJ hypermobility; dislocation

Introduction

Hypermobility of the temporomandibular joint (TMJ) results from condylar dislocation in front of the eminence when the mouth is opened wide.¹ It is noted only when it is associated with symptoms (pain and sounds in the TMJ, otalgia, headache, and open lock) and interferes with smooth mandibular movements.^{2–6}

Symptomatic hypermobility of the TMJ has been managed in several ways based on intervening in one of three pillars of joint stability: bony anatomy, associated musculature, or ligaments.⁷ These interventions include tightening of the capsule through capsular plication, capsulorrhaphy, reinforcement of the capsule with temporal fascia, injection of autologous blood, prolotherapy,^{1,5,8–10} creation of a mechanical obstacle to block excessive anterior excursion of the condyle by the insertion of bone graft or implants into the eminence,^{8,11} removal of the mechanical obstacles to allow free movement of the condyle through eminectomy, eminoplasty and menisectomy^{2,3,12} or creation of a

E-mail addresses: hamida.refai@dentistry.cu.edu.eg,
prof.hamidarefae@gmail.com

<http://dx.doi.org/10.1016/j.bjoms.2016.12.002>

0266-4356/© 2017 The British Association of Oral and Maxillofacial Surgeons. Published by Elsevier Ltd. All rights reserved.

Please cite this article in press as: Refai H. Long-term therapeutic effects of dextrose prolotherapy in patients with hypermobility of the temporomandibular joint: a single-arm study with 1-4 years' follow up. *Br J Oral Maxillofac Surg* (2017), <http://dx.doi.org/10.1016/j.bjoms.2016.12.002>

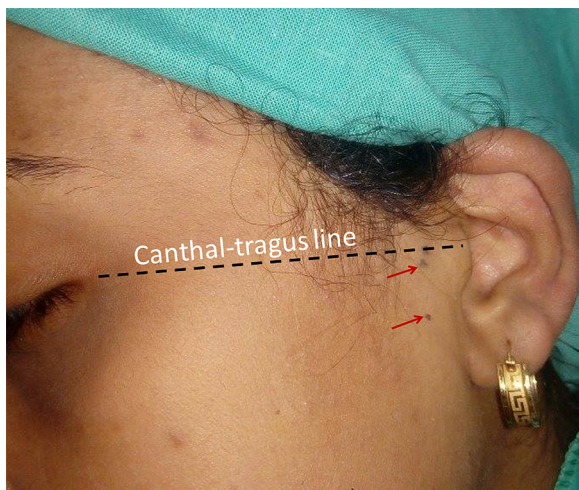


Fig. 1. Marking two points for the insertion of needles (arrows).

new muscular balance through scarification of the temporal tendon, myotomy of the lateral pterygoid muscle, and injection of botulinum toxin type A into the lateral pterygoid muscles.^{8,13–15}

During the past few years, dextrose prolotherapy has been used for the treatment of hypermobility of the TMJ with impressive outcomes. Prolotherapy, also called regenerative injection treatment, is an alternative treatment in which an irritant solution is injected into a joint space, weakened ligament, or tendon insertion, to relieve pain. Historically, this was called “sclerotherapy” because early solutions were thought to form scars. “Prolotherapy” is currently the most commonly-used term, which is short for proliferation therapy and is based on the presumed “proliferative” effects on chronically injured tissue.¹⁶ Some contemporary authors name it according to the solution injected.^{5,17} The common substance used is dextrose, but the choice of solution varies depending on the practitioner’s preference and may contain Sarapin[®], morruate sodium, zinc, or other natural ingredients, combined with a local anesthetic.¹⁷ It may be given as a single injection or a series of injections.

The mechanism of prolotherapy is not clearly understood. However, it has been hypothesised that it works by causing temporary, low grade inflammation at the injection site, which activates fibroblasts in the area, and these in turn synthesise precursors to mature collagen and reinforce connective tissue. The inflammatory stimulus of prolotherapy raises the concentration of growth factors to resume or initiate a new sequence of connective tissue repair, which had prematurely aborted or never started.¹⁸

Hypertonic dextrose is the most common proliferant used in prolotherapy with concentrations ranging from 10% - 50%,^{4,5,19} and evaluation of it in cases of symptomatic hypermobility of the TMJ has shown impressive outcomes.^{4–6,19} Irrespective of the volume and concentration of the solution injected, the sites injected, and the number of sessions, the evidence from published studies has indicated that it

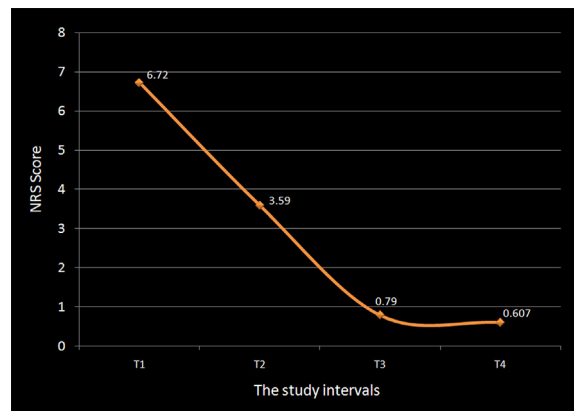


Fig. 2. Effect of time on pain scores.

significantly reduced pain in the TMJ and can be used as an efficient, simple, and conservative way to treat dislocation of the TMJ.^{5,6,19}

We know of four published studies about dextrose prolotherapy for the treatment of hypermobility of the TMJ,^{4–6,19} but these limited reports came to no conclusions about whether it reduced condylar translation and provided long-term resolution of symptomatic hypermobility of the TMJ. The purpose of the present study was to evaluate its clinical and radiographic outcomes in 61 patients with bilateral symptomatic hypermobility of the TMJ during a follow-up period of up to 4 years, with special attention paid to the pattern of improvement and the likelihood of recurrence.

Patients and Methods

This single-arm prospective study was approved by the Research Ethics Committee at the Faculty of Oral and Dental Medicine, Cairo University, Cairo, Egypt. Inclusion criteria were: the clinical diagnosis of symptomatic hypermobility of the TMJ confirmed radiographically by tomography in the closed and maximal mouth opening positions; age ≥ 18 years; and willingness to receive relatively painful injections and to follow instructions. Patients were excluded if they had dystonia, drug induced hypermobility, had had a previous operation on the TMJ, or had any medical condition that could interfere with treatment. Sixty-one patients with bilateral symptomatic hypermobility of the TMJ were included and gave their signed, informed consent.

The diagnosis of hypermobility was based on history and on clinical recognition of excessive abnormal excursion of the condyle that slides over the articular eminence and briefly catches the eminence anteriorly, before it returns to the fossa by self reduction or with medical assistance. Radiographic evidence of the condyle sliding in front of the articular eminence in the open-mouth position confirmed the clinical diagnosis.

Each patient was given four sessions of intra-articular and pericapsular injections six weeks apart. Two injection

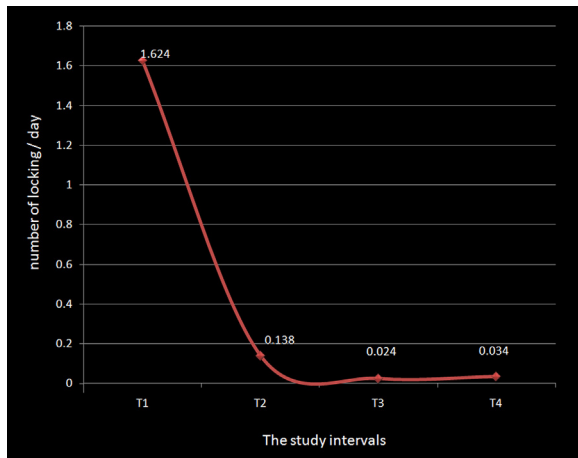


Fig. 3. Effect of time on locking frequency.

syringes with 30-gauge needles were used at each session, and each syringe was loaded with dextrose solution 3 ml (10% dextrose 2 ml and 2% mepivacaine with 1:20,000 levonordefrin 1 ml).

Two points for insertion of the needle were marked over the articular fossa and condylar neck of each joint (Fig. 1). The first point was placed 2 mm below the canthal-tragus line 1 cm in front of the mid-tragus. The second point was placed 1 cm below the first one. The needle was inserted at the superior point in an anterosuperior direction toward the lateral margin of the glenoid fossa where the capsule was attached superiorly, and 0.7 ml of the solution was injected. The needle was then directed downwards and medially to enter the superior joint space, and 1 ml was injected. The needle was then removed and reinserted at the inferior point where the capsule was attached inferiorly to the condylar neck, and 0.7 ml of the solution was injected. The needle was then directed superiorly superficial to the capsule of the TMJ, and the remaining 0.6 ml of the solution was injected with withdrawal of the needle.

After the injection the patients were prescribed paracetamol (acetaminophen) 500 mg, one tablet every four hours as needed, and were advised to avoid the use of other analgesic and anti-inflammatory drugs during treatment. They were also instructed to have a soft diet for two weeks and to avoid opening the mouth wide.

Clinical outcomes, including severity of pain on function (each patient rated his or her pain on the NRS of 0-10 with zero being no pain and 10 the worst pain possible), maximal interincisal opening was measured as the distance between the incisal edges of the upper and lower incisors, “Yes” or “No” responses to queries about the presence of clicking sound, and frequency of locking (number of episodes of locking/day) were measured at T1 before treatment, at T2 (just before the third session of injections), at T3 (3 months after treatment), and at T4 1-4 years after treatment. Condylar translation and osseous changes of each joint were evaluated at T1 and T4 using tomography.

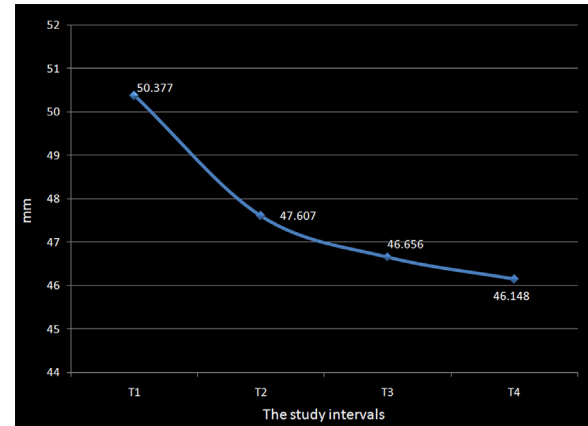


Fig. 4. Effect of time on maximal interincisal opening.

Statistical analysis

The Shapiro-Wilk test for normality indicated normally distributed data ($W = 0.980$, $p = 0.398$), and statistical analysis was done with the aid of the Microstat 7 for Windows statistical package (Informer Technologies Inc). We used the repeated measures ANOVA to evaluate the selected variables during follow up, after which we calculated the least significant difference for paired comparisons, and used the z test to compare the significance of differences in proportions of patients who had clicking joints. Probabilities of less than 0.05 were accepted as significant.

Results

There were 55 women and 6 men, mean (SD) age at the time of presentation 29 (7) years, range 18 – 43. The chief presenting complaints were joint pain and locking when the mouth was wide open, with or without clicking. Associated symptoms included headache, otalgia, tinnitus, and facial pain. Fifty-eight patients had subluxation (self reducing) and three had chronic recurrent dislocations (assisted reduction). Duration of follow-up ranged from 12 to 48 months (mean (SD) 28 (13) months).

The only potential complication was transient lagophthalmos as a result of paralysis of the temporal and zygomatic branches of the facial nerve by the anaesthetic included in the injected solution. It generally recovered within 60-90 minutes after the dextrose had been given.

Interestingly, there was a specific post-injection course that consisted of pain after the injection that lasted for 1-10 days followed by resolution of all symptoms, and this recurred with less intensity 3-5 days before the next injection.

Joint pain was the chief presenting complaint for 57 patients, and, by T4, 44 of them reported no pain. Table 1 and Fig. 2 show the details.

Although the chief presenting complaint was pain in the TMJ, 48 patients reported locking when the mouth was wide open. By the end of the study, 43 of them no longer com-

Table 1

Comparison between mean (SD) pain scores, frequency of locking, and maximum interincisal opening (mm) at different times using repeated measures ANOVA (n = 61).

Variable	Pain score	Frequency of locking	Maximum interincisal opening
Time:			
Before treatment	6.72 (2.78)	1.62 (1.82)	50.38 (7.63)
Mid-treatment	3.59 (2.50)	0.14 (0.37)	47.61 (6.68)
Three months later	0.79 (1.39)	0.02 (0.08)	46.66 (7.24)
1-4 years later	0.61 (1.57)	0.03 (0.15)	46.15 (7.02)
Statistics:			
F ratio	109.65	41.40	4.25
p value	<0.001	<0.001	0.006
Least significant difference	0.76	0.34	2.54

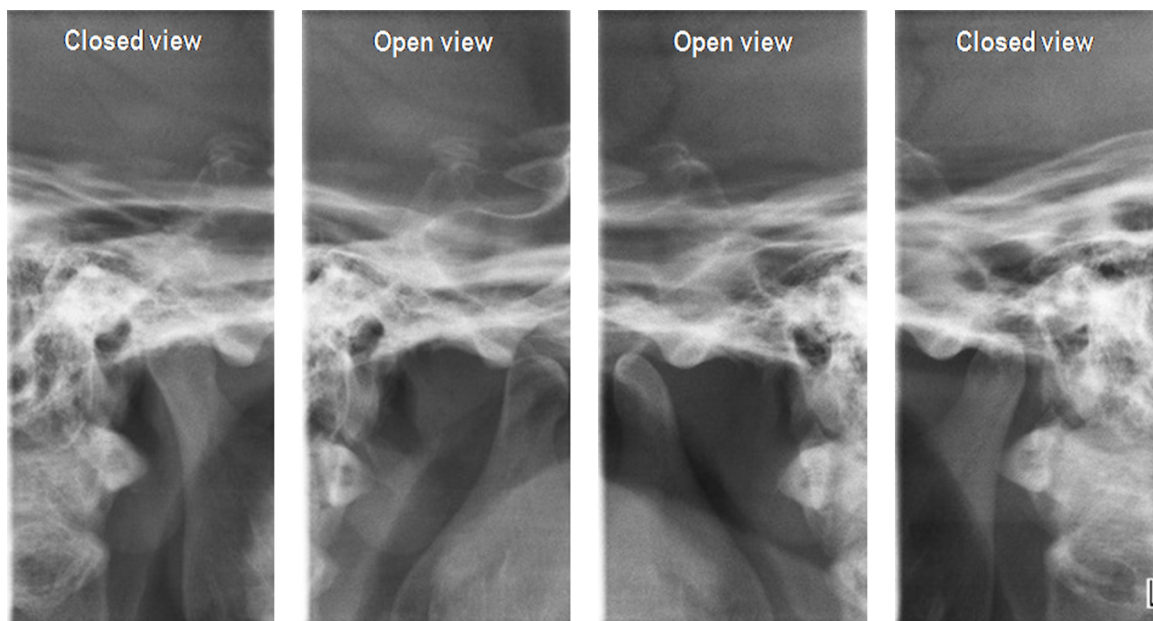


Fig. 5. Open and closed tomographic views of the temporomandibular joint in a patient with complete resolution of her presenting symptoms 4 years after treatment, showing bilateral condylar hypertranslation in the open views.

plained of locking. Three patients who had chronic recurrent dislocations reported that after the first treatment they could overcome the open locking without assistance. (Table 1 and Fig. 3). The associated symptoms (headache, otalgia, and tinnitus) were dramatically improved after the first session of injections. However, the myofascial pain did not improve, and was therefore treated by injection at the trigger points. The details of changes in maximum incisal opening are shown in Table 1 and Fig. 4.

All patients had clicking at wide mouth opening preoperatively. At T4, joint noise ceased in 41 patients. There was statistically significant reduction in number of patients having clicking at T2 (Z score = 4.595 and $p = 0.0000$) and T3 (Z score = 3.634 and $p = 0.0003$).

By the end of the study, 31 patients reported complete remission of their symptoms and four presented with symptoms not related to their previous complaints, clinical examination of which indicated myofascial pain that was successfully treated by dry needling or by injection with 3% mepivacaine of the trigger points.

Three patients had recurrent symptoms; two reported that their symptoms had resolved for a year, while one reported resolution for eight months after the last injections. Two patients could not recall any event that might have caused recurrence of symptoms and one attributed recurrence to domestic violence. Tomograms of each joint at T1 and T4 showed no alteration in the morphology of the bony components of the joint. At T4, the tomographic open view of all joints showed condylar hypertranslation (Fig. 5).

Discussion

We wanted to answer several questions including: Will the method prove as efficient when studied in larger group of patients? Will the symptoms recur with time? What is the pattern of postoperative healing? Will the presumed strengthening of the TMJ capsule by prolotherapy restore normal translation to the mandibular condyle?

Dextrose prolotherapy of the TMJ was effective in the treatment of symptomatic hypermobility of the TMJ, both with regard to the paucity of recurrent symptoms and the significant improvement in pain and function of the jaw during extended follow-up. These findings complement studies on dextrose prolotherapy for the treatment of hypermobility of the TMJ that showed substantial improvement.^{4–6,19}

We were interested to note that the patients experienced a characteristic post-injection course that consisted of three successive periods. The first period of post-injection pain lasted 1–10 days. The second, a long period of complete resolution of symptoms, lasted for 4–5 weeks, and the third, a period of recurrence of symptoms of less intensity, lasted 3–5 days before the next injection. This period diminished gradually until it ceased after the third or fourth session of injections. Telling the patients about the expected pattern of postoperative healing is of utmost importance for biobehavioural management of temporomandibular disorders.

Headache, otalgia, and tinnitus were dramatically improved after the first session of injections. The efficacy of dextrose prolotherapy in resolving aural symptoms could be attributed to direct deposition of dextrose through intra-articular injection in the vicinity of the discomalleolar ligament, which connects the malleolus in the tympanic cavity and the articular disc and capsule of the TMJ. It was thought to be responsible for the aural symptoms associated with dysfunction of the TMJ.²⁰

Analysis of tomography of the TMJ showed that dextrose prolotherapy changes neither condylar position nor the morphology of the bony components of the joint. The lack of changes in the position of the condyle could be explained by the observation of Jensen et al,²¹ who found that laxity of ligaments in the knee in a model of injury in rats was not altered by dextrose injections. This, together with the fact that hypermobility of the TMJ may be asymptomatic,^{22,23} make us doubt that the tightening of the capsule by 10% dextrose injection is an explanation for resolving symptomatic hypermobility.²⁴ Dextrose prolotherapy may improve the structural adaptability of the TMJ but we need to understand much more about the mechanism of action of dextrose prolotherapy, and further research in this area is necessary.

Conclusion

Dextrose prolotherapy provided significant and sustained reduction of pain and recovery of symptoms associated with symptomatic hypermobility of the TMJ. It changes neither the condylar position nor the morphology of the bony components of the joint.

Conflict of Interest

We have no conflict of interest.

Ethics statement/confirmation of patients' permission

The study was approved by the Research Ethics Committee at the Faculty of Oral and Dental Medicine, Cairo University. Patients' permission was not required as no images are identifiable.

Acknowledgement

Expressions of gratitude and appreciation are extended to Dr. Ahmad S. Hashem for helping with statistical analysis.

References

1. Torres DE, McCain JP. Arthroscopic electrothermal capsulorrhaphy for the treatment of recurrent temporomandibular joint dislocation. *Int J Oral Maxillofac Surg* 2012;**41**:681–9.
2. Gay-Escoda C. Eminectomy associated with redirection of the temporalis muscle for treatment of recurrent TMJ dislocation. *J Craniomaxillofac Surg* 1987;**15**:355–8.
3. Güven O. Inappropriate treatments in temporomandibular joint chronic recurrent dislocation: presenting three particular cases. *J Craniofac Surg* 2005;**16**:449–52.
4. Comert Kiliç S, Güngörmüş M. Is dextrose prolotherapy superior to placebo for the treatment of temporomandibular joint hypermobility? A randomized clinical trial. *Int J Oral Maxillofac Surg* 2016;**45**:813–9.
5. Refai H, Altahhan O, Elsharkawy R. The efficacy of dextrose prolotherapy for temporomandibular joint hypermobility: a preliminary prospective, randomized, double-blind, placebo-controlled clinical trial. *J Oral Maxillofac Surg* 2011;**69**:2962–70.
6. Ungor C, Atasoy KT, Taskesen F, et al. Short-term results of prolotherapy in the management of temporomandibular joint dislocation. *J Craniofac Surg* 2013;**24**:411–5.
7. Leopard PJ. Surgery of the non-ankylosed temporomandibular joint. *Br J Oral Maxillofac Surg* 1987;**25**:138–48.
8. Kummoona R. Surgical managements of subluxation and dislocation of the temporomandibular joint: clinical and experimental studies. *J Craniofac Surg* 2010;**21**:1692–7.
9. Boudreaux RE, Spire ED. Plication of the capsular ligament of the temporomandibular joint: a surgical approach to recurrent dislocation or chronic subluxation. *J Oral Surg* 1968;**26**:330–3.
10. Machon V, Abramowicz S, Paska J, et al. Autologous blood injection for the treatment of chronic recurrent temporomandibular joint dislocation. *J Oral Maxillofac Surg* 2009;**67**:114–9.
11. Medra AM, Mahrous AM. Glenotemporal osteotomy and bone grafting in the management of chronic recurrent dislocation and hypermobility of the temporomandibular joint. *Br J Oral Maxillofac Surg* 2008;**46**:119–22.
12. Undt G, Kermer C, Rasse M. Treatment of recurrent mandibular dislocation. Part II: eminectomy. *Int J Oral Maxillofac Surg* 1997;**26**:98–102.
13. Fu KY, Chen HM, Sun ZP, et al. Long-term efficacy of botulinum toxin type A for the treatment of habitual dislocation of the temporomandibular joint. *Br J Oral Maxillofac Surg* 2010;**48**:281–4.
14. Gould JF. Shortening of the temporalis tendon for hypermobility of the temporomandibular joint. *J Oral Surg* 1978;**36**:781–3.
15. Sindet-Pedersen S. Intraoral myotomy of the lateral pterygoid muscle for treatment of recurrent dislocation of the mandibular condyle. *J Oral Maxillofac Surg* 1988;**46**:445–9.
16. Rabago D, Slattengren A, Zgierska A. Prolotherapy in primary care practice. *Prim Care* 2010;**37**:65–80.
17. Alderman DD, Alexander RW. Advances in regenerative medicine: high-density platelet-rich plasma and stem cell prolotherapy for musculoskeletal pain. *Pract Pain Manag* 2011;**11**:49–90.

18. Foster TE, Puskas BL, Mandelbaum BR, et al. Platelet-rich plasma from basic science to clinical applications. *Am J Sports Med* 2009;**37**:2259–72.
19. Zhou H, Hu K, Ding Y. Modified dextrose prolotherapy for recurrent temporomandibular joint dislocation. *Br J Oral Maxillofac Surg* 2014;**52**:63–6.
20. Ramirez LM, Ballesteros AL, Sandoval OG. A direct anatomical study of the morphology and functionality of disco-malleolar and anterior malleolar ligaments. *Int J Morphol* 2009;**27**:367–79.
21. Jensen KT, Rabago DP, Best TM, et al. Response of knee ligaments to prolotherapy in a rat injury model. *Am J Sports Med* 2008;**36**:1347–57.
22. Juca KF, Suazo Galdames IC, Guimarães AS. Mandibular condyle position in maximum mouth opening. A magnetic resonance imaging evaluation. *Int J Morphol* 2009;**27**:867–71.
23. Sheppard IM, Sheppard SM. Subluxation of the temporomandibular joint. *Oral Surg Oral Med Oral Pathol* 1977;**44**:821–9.
24. Reeves KD, Hassanein KM. Long-term effects of dextrose prolotherapy for anterior cruciate ligament laxity. *Altern Ther Health Med* 2003;**9**:58–62.