

PLATELET RICH PLASMA FOR HAMSTRING TEARS

A retrospective, clinical case report of a single percutaneous application of platelet rich plasma to a severe traumatic partial-thickness proximal hamstring tear demonstrates sustained subjective and functional improvements with near-complete repair on MRI.

By David C. Karli, MD and Brent R. Robinson, BS

Platelet Rich Plasma (PRP) Injection Therapy is gaining popularity in musculoskeletal medicine, not only for its ease of use, but also for its consistently good results. In this excellent analysis and case study, Karli and Robinson of the Stedman Clinic in Colorado demonstrate sustained objective and subjective improvement with just one PRP treatment in a near-complete hamstring tendon tear. The authors demonstrate that—while certainly useful—ultrasound guidance is not mandatory when the anatomical location is easily palpable. They also use a very creative method of extracting autologous thrombin from the platelet-poor portion of the centrifuged blood, presenting a promising new possibility for emerging PRP protocols.

— Donna Alderman, DO
Prolotherapy Department Head

Proximal hamstring injuries are common in athletes and frequently result in prolonged rehabilitation, time missed from play, and a significant risk of reinjury.^{1,2} Reports of acute hamstring strains without avulsion in dancers have suggested recovery times for return-to-play ranging from 30 to 76 weeks.¹ The healing process associated with hamstring injuries and with injured skeletal muscle is inefficient as compared to that associated with injuries of other tissue such as bone. This inefficiency is driven by structural adaptations that maximize load-carrying capacity under prolonged ischemic conditions.³ Vascular supply from associated muscle and surrounding tissues typically does not extend beyond the proximal third of the tendon.^{3,4} Because oxygen consumption is low and energy generation is anaerobic, the resulting metabolic rate is slow and healing capacity is limited.³

Tendons are damaged when subjected to loads that exceed their tensile or physiologic threshold. This can occur in response to massive trauma or to repetitive overload if insufficient time is allowed for tissue recovery. The risk for tendon rupture is highest when tension is applied rapidly and obliquely.³ The highest forces have been recorded during eccentric contraction.^{3,5} Tendons respond to this non-physiologic overload with tendon sheath inflammation, intratendinous degeneration, or a combination of both.^{1,6}

Muscle and tendon recover from injury through tissue remodeling that can lead to inefficient regeneration and infiltration by scar tissue.^{7,8} The first phase involves an increase in vascular permeability, initiation of angiogenesis, chemotactic migration of inflammatory cells (notably neutrophils initially then followed by macrophages) to the region of injury, and induction of local tenocytes to synthesize collagen and extracellular matrix (ECM).^{7,8} After several days, type III collagen synthesis peaks as tenocyte proliferation continues. At roughly six weeks, the healing tissue begins to remodel. Regional cellularity decreases as up-regulation of synthesis of collagen and other proteins takes place. Tissue gradually transitions from cellular to fibrous in nature as tenocytes align in the direction of stress forces. Production of collagen type I increases as production of type III drops off. At approximately 10 weeks, fibrous tissue begins to remodel and mature. These processes continue through the course of a full year, resulting in tendon tissue with scar-like properties. As tissue matures, tenocyte metabolism decreases—either through intrinsic mechanisms contained within an intact peritenon or through extrinsic mechanisms involving invasion by cells from the surrounding tissue. Extrinsic pathways related to peritenon disruption and more severe injuries lead to greater scarring and adhesion and resultant disruption of the normal gliding of the tendon within the sheath.^{9,10}

Traditional hypotheses have attributed pain in tendinopathy to an inflammatory process. Studies of chronically painful achilles and patellar tendons have shown no evidence of inflammation. Histologically, healing appears to be disordered and haphazard, with an absence of inflammatory cells but presence of hypercellularity, scattered vascular in-growth, and collagen degeneration. The etiology of

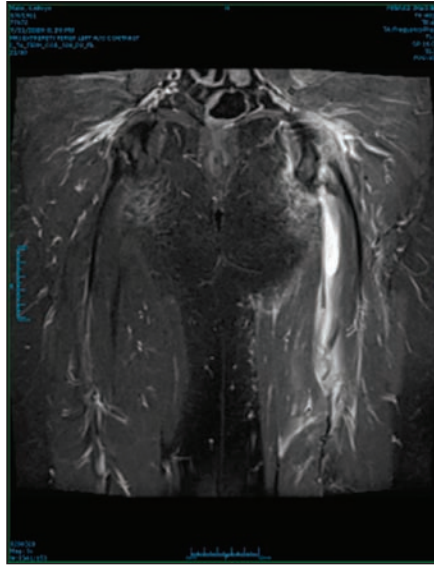


FIGURE 1A. Pre-procedure MRI — demonstration of subject proximal hamstring tissue avulsion and hemorrhagic and inflammatory changes in the sub-acute period.

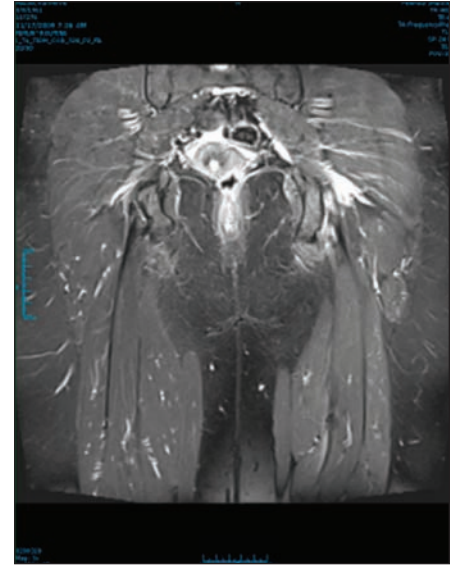


FIGURE 1B. Post-procedure MRI — demonstration of interval healing following percutaneous implantation of PRP, PPP and AT.

pain within tendons has not been conclusively elucidated, but evidence suggests that mechanical collagen breakdown, abnormal lactate levels, neurotransmitter imbalance, the presence of pro-inflammatory prostaglandins, and neural centralization may be involved.³

Tendon recovery is frequently incomplete in severe or full-thickness tears, due to the proliferation and up-regulation of fibroblasts, which induce formation of excessive scar tissue that leads to suboptimal tissue integrity and functionality.⁸ Research suggests that throughout tendon repair, trophic substances, such as growth factors released from damaged tissue, may regulate the healing response. It has been hypothesized that autologous growth factors found in platelets may augment the healing of musculoskeletal soft-tissue abnormalities.^{8,11-13}

An understanding of the role of platelets in tissue healing has led to the use of autologous platelet concentrates for therapeutic purposes. Degranulation and subsequent release of growth factors from platelets can be induced and the isolated growth factors can be delivered directly into injured tissue to stimulate a physiologic response. Platelet-rich plasma (PRP) is easy to produce through centrifugation of peripheral blood and separation of the resulting component. As an autologous substrate, PRP has limited potential to harm.^{11,14} The therapeutic re-

sponse of the percutaneous implantation of PRP into tendon, muscle, ligament, cartilage, intervertebral disc, and fascia has generally been positive.¹⁵

Numerous growth-factor peptides have been identified in both the dense granules and the alpha granules of platelets, which bind to membrane-bound receptors, thereby activating intracellular second-messenger pathways.^{11,16,17} Bioactive functions associated with platelet-derived growth factors (PDGFs) include angiogenesis, chemotaxis, cell recruitment, cellular proliferation, cellular differentiation, and ECM synthesis.¹² Some researchers have suggested that, due to the complexity of healing pathways and tissue regeneration, the synergistic interaction of multiple growth factors at physiologic concentrations may be superior to the action of a single exogenous growth factor.^{12,18}

Case Report

A 48-year-old female sustained a severe left proximal hamstring tear while water skiing. Her left leg became hyperextended when she attempted to drop her right ski and the ski caught the water, aggressively forcing her left hip into eccentric hyperflexion. Subsequently, she felt a tearing sensation localized to the left ischial tuberosity region at the origin of the left common hamstring tendon. She immediately experienced pain and transient numbness in the left lower extremity. Ini-



FIGURE 2A. *Autologous thrombin. Removal of the clot following the addition of 10% Calcium Chloride.*

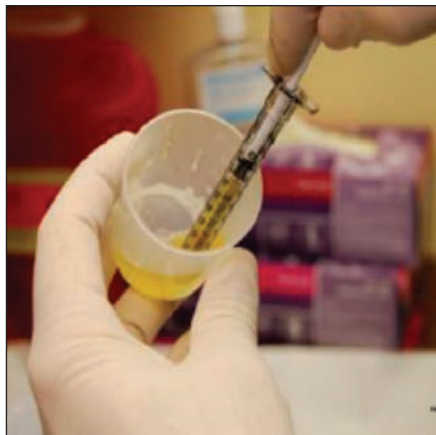


FIGURE 2B. *Autologous thrombin. Harvesting of autologous thrombin prior to injection.*

tially, she did not seek care, instead relying on rest and oral nonsteroidal anti-inflammatory drugs (NSAIDs) for two and one-half weeks. During this time, although symptom intensity decreased, pain and dysfunction persisted with ambulation, prolonged sitting, and exertional activity. Nocturnal pain interrupted the patient's sleep patterns. In addition, the patient experienced subjective weakness and instability of the affected leg as well as localized swelling at the site of injury.

Sixteen days after the injury, the patient consulted an orthopaedic surgeon because of the persistence of pain and functional limitation. The consulting physician identified pain on palpation, which was localized to the left buttock and aggravated by resisted knee flexion. Left hamstring strength was rated 4/5 and left lower extremity sensory and vascular exams were normal.

Radiographs of the pelvis revealed no bony defects at the hamstring insertion into the ischial tuberosity or evidence of any other hip-joint abnormality. MRI confirmed a full-thickness tear of the proximal semimembranosus tendon near the myotendinous junction. Tendon-fiber retraction was measured to be 3 cm. A partial-thickness tear of the conjoined biceps femoris and semitendinosus tendon at the ischial tuberosity insertion was also reported. No bone marrow edema was noted. A diffuse hematoma within the region was also appreciated (see Figure 1a).

After discussion of the surgical and non-surgical options, the patient opted for PRP injection in an attempt to facilitate healing and recovery in the setting of conservative therapy. At this point, she was re-

ferred to the author for the procedure, which was performed on post-injury day 16, after all of the risks and details of the procedure were explained to the patient and consent had been obtained.

PROCEDURE

Production of Platelet Rich Plasma

With sterile technique, 60mL of whole blood was collected by peripheral phlebotomy into a syringe containing 6 cc of the anticoagulant citrate dextrose solution A (ACD-A, Cytosol Laboratories, Braintree, MA). The specimen was processed with a Harvest® SmartPREP® centrifugation system and 60mL disposable kit (Harvest Technologies, Plymouth, MA). The blood sample was loaded, centrifuged, and harvested following the manufacturer's protocol. The initial 60mL of whole blood yielded 7mL of PRP, which was drawn into a sterile syringe. The red blood cell fraction was discarded, and the platelet-poor plasma (PPP) was saved for the production of autologous thrombin (AT).

Activation of Platelet-Poor Plasma and Production of Autologous Thrombin Supernatant

Once the whole blood was separated, 7mL of the PPP was added to each of two 10-mL glass BD Vacutainer tubes (BD, Franklin Lakes, NJ), both of which had been pre-dosed with 0.15mL of 10% calcium chloride (American Regent, Inc., Shirley, NY) to reverse the effects of the anticoagulant. The tubes were vigorously shaken for 60 seconds to adequately mix the contents and then left to stand for 15 minutes. After the rest period, a thick, soft

clot formation was noted within each tube. Under sterile conditions, the clot was manually broken apart to produce a clear supernatant, which was harvested (see Figure 2a) and drawn into a sterile syringe (Figure 2b). Consistent with reports described by Everts and other authors, the resulting supernatant following PPP activation has been demonstrated to contain autologous thrombin protein.^{19,20}

PRP Implantation

The patient was placed in a prone position. The left gluteal and proximal hamstring region was prepared and draped under sterile conditions. With the tendon at rest and with concentric contraction, the areas of maximal tenderness and the site of proximal insertion of the hamstring into the ischial tuberosity were identified by palpation.

Contact with and isolation of the target region was maintained through application of isometric contraction with manual soft tissue depression by the second and third digits of the examiner's nondominant hand. Local anesthesia was achieved by placing 1% preservative-free Xylocaine (2-3mL) into the soft tissue of the proximal hamstring.

While constant pressure was maintained with the nondominant hand, a 22-gauge, 1.5-inch needle was inserted toward the ischial tuberosity. Once periosteal contact was made, the PRP was placed at the insertion site in a fanlike distribution with a radius of several centimeters and also along the proximal 3-5 cm of the common tendon tissues utilizing 4-5 needle fenestrations of the tendon and myotendinous junction. After negative aspirations, all 7mL of PRP was infiltrated. The PRP syringe was disconnected, the activated PPP/AT-filled syringe was attached, and then 7mL of PPP/AT was infiltrated into the tissue in a similar fashion. A sterile dressing was applied to the region, and the patient was discharged home.

Post-Procedure Protocol

A two-week period of relative rest and activity restriction was recommended. Weight-bearing and ambulation as tolerated were allowed but any aggressive stretching or concentric or eccentric loading of the tendon was not. The patient was advised to avoid NSAIDs or any other anti-inflammatory medication for at least two weeks. At week three, the patient was permitted to increase her activ-

ities slowly and progressively as pain allowed her to tolerate.

Post-Procedure Clinical Course

The patient reported no significant increase in pain after the intervention. Subjective improvement in pain was noticeable at one week, and functionality began to improve gradually about the same time. By week four, the patient was able to ambulate without pain or antalgia and to sit pain-free for reasonable periods. In addition, the quality of her sleep had also improved due to resolution of nocturnal pain and she no longer required NSAIDs or other analgesics. She was able to resume light exercise, including treadmill-walking, at week six and was able to tolerate stationary bicycling at moderate exertion by week eight. When followed up by phone at 20 weeks, the patient reported no return of discomfort during the interim. As of six months post-procedure, she was continuing to progressively increase activities and was preparing to begin more aggressive concentric and eccentric strengthening activities. Her goal was ultimately to resume alpine and water skiing.

The patient underwent follow-up MRI just under four months following the injury. The radiologist who had interpreted the pre-procedure study reported the following at follow-up:

1. "Significant interval healing response within both the semimembranosus tendon and the conjoined tendon of biceps femoris and semitendinosus. Mild granulation tissue and contour irregularity persists within the proximal tendons. There is persistent partial, but not complete, avulsion of the conjoined tendon from the ischial tuberosity. The semimembranosus tendon origin is intact.
2. Interval complete resolution of the hamstring muscle strains and posterior thigh hematoma" (see Figure 1b).

Discussion

Traditional nonsurgical therapies for acute and chronic tendon injuries have limited potential to alter the long-term course of the disease process. If acute or repetitive tendon trauma results in fibrosis of the intratendinous tissue, chronicity usually develops and results in pain, functional limitation, and risk of reinjury.

In a study of transected Achilles tendon in sheep, histologic and biomechanical properties of spontaneously-healed tendons did not match those of intact noninjured tendons. At 12 months, rupture force in the transected group rated only 56.7% of that in the normal group.²¹ Peritendinous scar formation has also been observed to produce sciatic nerve irritation and lower extremity sensorimotor symptoms.^{3,22} Disappointing clinical results have led to a growing interest in the potential of anabolic and regenerative therapies which, in theory, may be able to augment the capability of tissues for repair.

PRP represents a simple, low-cost, low-risk, autologous regenerative biotherapeutic agent whose utility in treating soft-tissue pathology remains under investigation. Thus far, its safety profile has been

tification of autologous thrombin ranges within activated PPP using the methods described above would be helpful in determining advantage and necessity.

Questions remain regarding optimal therapeutic PRP concentration versus whole blood and the effect of white blood cell inclusion within the PRP injectate. Everts et al²³ have suggested a 4- to 5-fold increase in platelet concentration versus whole blood based on the anabolic effects of PRP on soft tissues and bone healing. Whether higher PRP concentrations lead to incremental increases in anabolic tissue stimulation is currently unclear. Some authors have suggested that higher concentrations could contribute to deleterious effects, although this has not been substantiated.

Accuracy of percutaneous delivery of PRP appears to be critical in providing the

"PRP represents a simple, low-cost, low-risk, autologous regenerative biotherapeutic agent whose utility in treating soft-tissue pathology remains under investigation. Thus far, its safety profile has been strong. No serious adverse event related to PRP application has been reported in the literature."

strong. No serious adverse event related to PRP application has been reported in the literature. The author's experience, which includes more than 1,500 percutaneous cases, has been similar, with the emergence of a solid safety record, as well as a trend toward therapeutic success.

To date, research has suggested the same trends of utility and favorable outcomes for the application of PRP in basic orthopedic conditions, such as lateral epicondylitis, achilles tendinopathy, patellar tendinopathy, rotator cuff injury, muscle injury, osteoarthritis, ligament injury, and intervertebral disc pathology.¹⁵ Research continues not only to validate the therapeutic effect of PRP under the strictest of scientific criteria but also to elucidate the intracellular effects of PDGFs on exposed tissue. Controversy exists regarding the need for the addition of autologous thrombin to improve efficiency of platelet degranulation versus reliance on native collagen or exposed tissue to achieve maximal platelet degranulation. Quan-

maximal possible therapeutic effect. Ultrasound and fluoroscopic guidance have gained favor among practitioners who provide PRP interventions and, in the author's experience, these imaging techniques have merit. The site of the injury reported above was easily identified with manual palpation, but ultrasound needle localization could have been used to verify implantation of the PRP within viable tendon tissue and in peritendinous regions at the site of avulsion.

If PRP as a useful therapeutic option stands the test of scientific validation, practitioners would have a clinical tool to promote faster and more complete healing of acutely injured tissue and to prevent chronic tissue pathology by stimulating regeneration of healthy tissue that would not otherwise form spontaneously. The implications for traditional approaches to sports injury are obvious. Chronic injury and its attendant performance impairment could be avoided, and injury progression through continued

play would no longer be a risk.

If its safety profile continues to be favorable, PRP may represent a safer alternative to more traditional treatments, such as steroidal and nonsteroidal medications—whether injected or delivered orally. In a study evaluating the histopathologic changes in proximal hamstring tendinopathy, Lempainen et al²² concluded that with corticosteroid application, chronic tendinopathy was likely to develop and usually only short-term relief was provided.

PRP infiltration could also complement rehabilitation programs that are so often used to treat soft-tissue disorders. Post-procedure activity-modification and rehabilitation protocols have yet to be clearly defined. Most clinical research has suggested the need for a period of tissue rest—due to the sustained bioactivity and release of growth factors—followed by graded return to activity and training at different intervals.²⁴

The case presented here demonstrates the potential therapeutic effects of PRP. A single infiltration of PRP promoted the healing of a severe, near-complete-thickness, traumatic hamstring tendon disruption that otherwise would likely have faced surgical debridement and reimplantation. As of six months post-procedure (after a single application), the outcome continues to be good in terms of both symptoms and function. MRI follow-up has suggested that limited residual scar tissue has formed. In contrast, to judge from histologic research data, the likelihood of scarred, dysfunctional tissue following spontaneous tissue repair of an injury of this magnitude would have been high.

The exact mechanism of anabolic stimulation with PRP or PDGFs has yet to be elucidated. It may, in fact, reflect a complex interaction of cellular and noncellular events. The stage of the healing process during which PRP is effective also remains unclear. Without question, further research is required not only to validate the biotherapeutic effects and clinical results of PRP therapy but also to unveil the physiologic mechanisms of action.

Summary

Percutaneous, autologous platelet rich plasma injection was selected as a conservative treatment option for a proximal hamstring injury within the setting of a private orthopedic surgical practice. Sub-

jective improvement post-procedure was monitored through six months. Pre-injury MRI was performed at approximately two weeks after the initial injury. At four months post-treatment, a follow up MRI with the same parameters was repeated and reviewed by the same radiologist to evaluate healing and tissue integrity. The patient subjectively reported a decrease in pain at one week post-procedure. Reduction in pain and improvements in functionality continued through weeks 4, 6, 8, 20 and at final follow-up at six months. The improvements noted by the patient coincided with significant tissue healing as reported by the evaluating radiologist on follow-up MRI.

Platelet rich plasma represents a simple, low-cost, low-risk, autologous regenerative biotherapy whose utility in treating soft-tissue pathology remains under investigation. This case report demonstrates sustained subjective and functional improvements with near-complete repair on MRI with a single application of platelet-rich plasma in a severe tendon injury. ■

Disclosure

The authors certify that no party having a direct interest in the results of the research supporting this article has or will confer a benefit on the authors or on any organization with which the authors are associated.

David Karli, MD, is currently a physician partner at the Steadman Clinic in Vail, Colorado, where he has practiced since 2003. He received his residency training at Harvard Medical School and medical degree through the University of Maryland. His research interests are focused on clinical applications and basic science mechanisms of autologous regenerative biotechnologies, including platelet rich plasma.

Brent Robinson, BS, is a research associate in Regenerative Orthopaedics at the Steadman Clinic. His background in regenerative medicine and stem cell research began at the Colorado State University Veterinary Teaching Hospital.

References

1. Askling C, Saartok T, Thorstensson A. Type of acute hamstring strain affects flexibility, strength, and time to return to pre-injury level. *Br J of Sports Med.* 2006. 40: 40-44.
2. Connell D, Schneider-Kolsky M, Hoving J, et al. Longitudinal study comparing sonographic and MRI assessments of acute and healing hamstring injuries. *Am Roentgen Ray Society.* 2004. 183: 975-984.

3. Sharma P and Maffulli N. Biology of tendon injury: healing, modeling, and remodeling. *J Musculoskeletal Neuronal Interact.* 2006. 6: 181-190.
4. Naito M and Ogata K. The blood supply of the tendon with a paratenon: an experimental study using hydrogen washout technique. *Hand.* 1983;15:9-14.
5. Fyfe I, Stanish WD. The use of eccentric training and stretching in the treatment and prevention of tendon injuries. *Clin Sports Med.* 1992. 11: 601-624.
6. Benazzo F and Maffulli N. An operative approach to Achilles tendinopathy. *Sports Med Arthroscopy Rev.* 2000. 8: 96-101.
7. Jarvinen T, Jarvinen T, Kaariainen M, et al. Muscle injuries: optimizing recovery. *Best Practice & Research Clinical Rheumatology.* 2006. 21: 317-331.
8. Menetrey J, Kasemkijwattana C, Day C, et al. Growth factors improve muscle healing in vivo. *J of Bone and Joint Surg [Br].* 2000. 82: 131-137.
9. Koob TJ and Summers AP. Tendon-bridging the gap. *Comp Biochem Physiol: A Mol Inter Physiol.* 2002. 133: 905-909.
10. Strickland JW. Flexor tendons: acute injuries. In Green D, Hotchkiss R, Pedersen W. eds. *Green's operative hand surgery.* Churchill Livingstone. New York. 1999. pp 1851-1897.
11. Crane D and Everts P. Platelet Rich Plasma (PRP) Matrix Graphs. *Pract Pain Manag.* 2008. 8(1): 12-26.
12. Foster T, Puskas B, Mandelbaum B, et al. *Platelet rich plasma from basic science to clinical applications.* 2009. 37: 2259-2272.
13. Hall M, Band P, Meislin R, et al. Platelet-rich plasma: current concepts and application in sports medicine. *J Am Acad Orthop Surgeons.* 2009. 17:602-608.
14. Bielecki TM, Gazdzik TS, and Arendt J. Antibacterial effect of autologous platelet gel enriched with growth factors and other active substances: an in vitro study. *J of Bone and Joint Surg.* 2007. 89:417-420.
15. Sampson S, Gerhardt M, Mandelbaum B. Platelet rich plasma injection grafts for musculoskeletal injuries: a review. *Curr Rev Musculoskeletal Med.* 2008. 1: 165-174.
16. Chambers RL and McDermott JC. Molecular basis of skeletal muscle regeneration. *Can J Appl Physiol.* 1996. 21: 155-184.
17. Grounds MD. Towards understanding skeletal muscle regeneration. *Path Res Pract.* 1991. 187: 1-22.
18. Molloy T, Wang Y, and Murrell G. The roles of growth factors in tendon and ligament healing. *Sports Med.* 2003. 33: 381-394.
19. DeRossi R, Coelho A, de Mello G, et al. Effects of platelet-rich plasma gel on skin healing on surgical wound in horses. *Acta Cir Bras.* 2009. 24: 276-281.
20. Giacco F, Perruolo G, D'Agostino E, et al. Thrombin-activated platelets induce proliferation of human skin fibroblasts by stimulating autocrine production of insulin-like growth factor-1. *FSEB J.* 2006. 20: 2402-2404.
21. Bruns J, Kampen J, Kahrs J, et al. Achilles tendon rupture: experimental results on spontaneous repair in a sheep-model. *Knee Surg Sports Traumatol Arthrosc.* 2000. 8: 364-369.
22. Lempainen L, Sarimo J, Mattila K, et al. Proximal hamstring tendinopathy: results of surgical management and histopathologic findings. *Am J Sports Med.* 2009. 37: 727-734.
23. Everts P, Knappe J, Weibrich, et al. Platelet rich plasma and platelet gel: a review. *J Extra Corpor Techn.* 2006. 38: 174-187.
24. Van Den Dolder J, Mooren R, Vloon A, et al. Platelet-Rich Plasma: Quantification of Growth Factor Levels and the Effect on Growth and Differentiation of Rat Bone Marrow Cells. *Tissue Eng Part A.* 2010. 16: 1021-1029.