

The New Age of Prolotherapy

In addition to traditional prolotherapy, platelet-rich plasma and stem cells are also available to enhance healing of musculoskeletal injuries and mitigation of pain.

By Donna Alderman, DO



We live in a technological age. With technology comes growth and enhancement of techniques and prolotherapy is no exception. In the March 2010 issue of the Mayo Clinic Health Letter, the authors talk about a new technique involving the injection of platelet rich plasma (PRP) into tendons.¹ Quietly working its way through orthopaedic and sports medicine circles and disguised as a “new” treatment, PRP itself has been around since at least the early 1990s² in surgical and dental applications, but only recently in the musculoskeletal arena. When used to treat injured tendons, ligaments or joints, PRP is simply a modern version of prolotherapy.³ Almost exactly five years ago, in the April 2005 issue of the Mayo Clinic Health Letter, the authors endorse prolotherapy and write: “In the case of chronic ligament or tendon pain that hasn’t responded to more conservative treatments such as prescribed exercise and physical therapy, prolotherapy may be helpful.”⁴

Now the Mayo Clinic is endorsing PRP, the “new” prolotherapy, for musculoskeletal injuries. In addition to PRP, stem cell joint injections are being used in recalcitrant cases of joint dysfunction—utilizing both bone marrow and fat tissue as stem cell repositories.⁵ Musculoskeletal ultrasound is also now available and gaining popularity for use in office diagnosis and guidance (notwithstanding the learning curve required for physician proficiency). This article explores these new developments and what this means for the field of prolotherapy and regenerative medicine.

Review of Prolotherapy

Introduced in the 1930s, prolotherapy is a method of injection treatment designed to stimulate healing.⁶ A recent definition is “the injection of growth factors or growth factor production stimulants to grow normal cells or tissue.”⁷ Prolotherapy owes its origins to the innovation of Dr. Earl Gedney, an osteopathic physician and surgeon. In the early 1930s, Dr. Gedney caught his thumb in closing surgical suite doors thereby stretching the joint and causing severe pain and instability. After being told by his colleagues that nothing could be done for his condition and that his surgical career was over, Gedney did his own research and decided to “be his own doctor.” He knew of a group of doctors called “herniologists” that used irritating solutions to stimulate the repair of the distended connective tissue ring in hernias. He extrapolated this knowledge to inject his injured thumb and was able to fully rehabilitate it.⁸

In 1937, Gedney published “The Hypermobile Joint,”⁹ the first known article about prolotherapy (then called “sclerotherapy”) in the medical literature. The 1937 article gave a preliminary protocol and two case reports—one of a patient with knee pain and another with low back pain—with both successfully treated with this method. Gedney followed up this paper with a presentation at the February 1938 meeting of the Osteopathic Clinical Society of Philadelphia which outlined the technique.¹⁰ The solutions used then (and now) are primarily dextrose-based, although other formulas are used and can be effective.¹¹ Prolotherapy is practiced by

physicians in the U.S. and worldwide, has been shown effective in treating many musculoskeletal conditions—such as tendinopathies, ligament sprains, back and neck pain, tennis/golfers elbow, ankle pain, joint laxity and instability, plantar fasciitis, shoulder, knee pain and other joint pain.¹²

How Prolotherapy Works

Prolotherapy works by causing a temporary, low grade inflammation at the injection site, activating fibroblasts to the area, which, in turn, synthesize precursors to mature collagen and thus reinforce connective tissue.² It has been well documented that direct exposure of fibroblasts to growth factors (either endogenous or exogenous) causes new cell growth and collagen deposition.¹³⁻¹⁷ Inflammation creates secondary growth factor elevation.² The inflammatory stimulus of prolotherapy raises the level of growth factors to resume or initiate a new connective tissue repair sequence which had prematurely aborted or never started.² Animal biopsy studies show ligament thickening, enlargement of the tendinous junction, and strengthening of the tendon or ligament after prolotherapy injections.^{18,19}

Platelet Rich Plasma (PRP) Therapy

Platelet rich plasma (PRP) therapy, like prolotherapy, is a method of injection designed to stimulate healing. “Platelet rich plasma” is defined as “autologous blood with concentrations of platelets above baseline levels,”²⁰ “which contains at least seven growth factors.”²¹ Cell ratios in normal blood contain only 6% platelets, how-

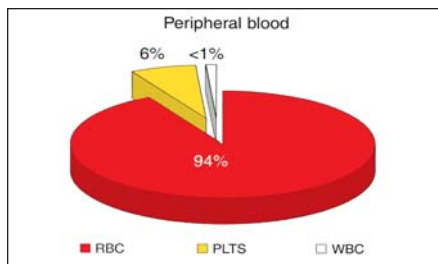


FIGURE 1A. Cell ratios in a normal blood clot: red blood cells (RBC), platelets (PLTS), and white blood cells (WBC).

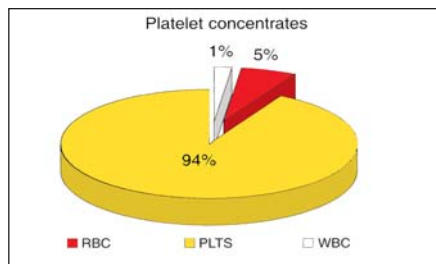


FIGURE 2A. Cell ratios in platelet rich plasma: red blood cells (RBC), platelets (PLTS), and white blood cells (WBC).

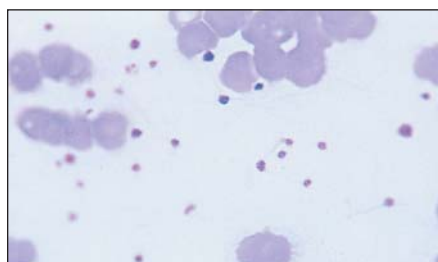


FIGURE 1B. Peripheral blood smear in normal blood.

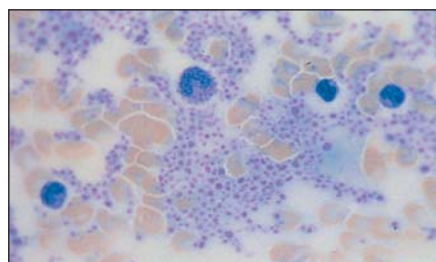


FIGURE 2B. A peripheral blood smear of platelet rich plasma).

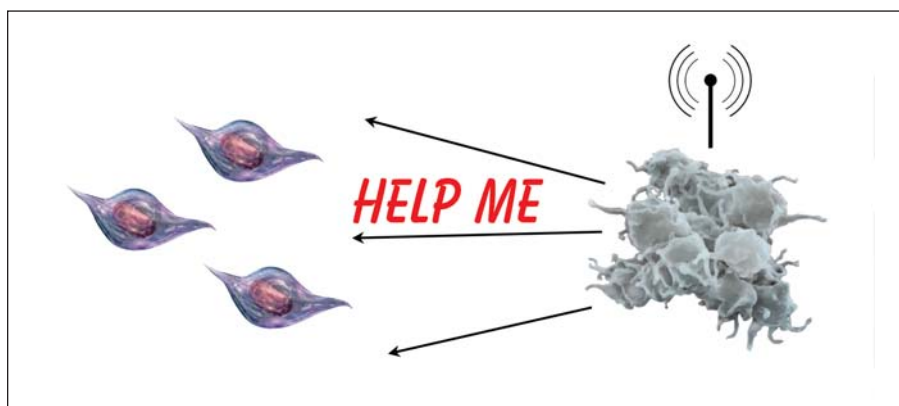


FIGURE 3. PRP mode of action: activated platelets signal for help from repair stem cells.

ever, in PRP, there is a concentration of 94% platelets (see Figures 1 and 2).²² Platelets contain a number of proteins, cytokines and other bioactive factors that initiate and regulate basic aspects of natural wound healing.²³ Circulating platelets secrete growth factors, such as platelet-derived growth factor (stimulates cell replication, angiogenesis), vascular endothelial growth factor (angiogenesis), fibroblast growth factor (proliferation of myoblasts and angiogenesis), and insulin-like growth factor-1 (mediates growth and repair of skeletal muscle), among others.²⁴ Enhanced healing is possible when platelet concentration is increased with PRP.²⁵ Activated platelets “signal” to distant repair cells, including adult stem cells, to come to the injury site (see Fig-

ure 3). Increasing the volume of platelets accordingly increases the subsequent influx of repair and stem cells.²⁶ Because the concentrated platelets are suspended in a small volume of plasma, the three plasma proteins fibrin, fibronectin, and vitronectin contribute to a repair matrix.²⁷ You could compare dextrose prolotherapy and PRP this way: prolotherapy is like planting seeds in a garden; PRP therapy is planting seeds with fertilizer.

History of Platelet Rich Plasma Therapy

Beginning in the 1990s and continuing until now, “growth factors” have been a hot topic in the medical world. It is clear that growth factors play a pivotal role in all types of wound healing.²⁸ Investigation into the use of PRP has been reported as

early as the 1970s,²⁹ but the necessary equipment was large, expensive (\$40,000 in 1996), and required a large quantity of a patient's blood (450 cc) and therefore limited to the operating room for large scale surgeries.³⁰ Starting in the early 1990s, multiple reports and studies in maxillofacial dental, periodontal surgery,^{31,32} cosmetic surgery,³³ and skin grafting showed dramatically improved healing with PRP (see Figures 4 and 5).

In the early 2000s, the use of PRP expanded into orthopedics to augment healing in bone grafts and fractures. Success there encouraged its use in sports medicine for connective tissue repair. Mishra and Pavelko, associated with Stanford University, published the first human study supporting the use of PRP for chronic tendon problems in 2006.³⁴ This study reported a 93% reduction in pain at two year followup. Then, in 2008, Pittsburgh Steelers' wide receiver, Hines Ward, received PRP for a knee medial collateral ligament sprain, and the Steelers went on to win SuperBowl XLII. Ward credited PRP for his ability to play in that game and his success with this treatment was discussed on national television.³⁵

Since then, other high profile athletes—such as Takashi Saito, closing pitcher for the L.A. Dodgers, and golfer Tiger Woods—credit PRP for helping them return to their sport.³⁶ PRP continues to gain wider acceptance in the sports world with studies continuing to validate the use of PRP for ligament and tendon injuries,³⁷ knee osteoarthritis,³⁸ degenerative knee cartilage,³⁹ chronic elbow tendonosis,⁴⁰ muscle strain⁴¹ and tears,⁴² jumpers knee,⁴³ plantar fasciitis⁴⁴ and rotator cuff tendinopathy⁴⁵—albeit some skeptics and controversy remains.^{46,47}

As the use of PRP has grown, the demand and availability for smaller, more portable and affordable machines has also grown. There are now several available models which allow the physician to create PRP from a small sample of a patient's blood in the office setting (see Figure 6).⁴⁸ Machines are very affordable and many companies offer a complimentary machine with a minimum purchase of PRP preparation kits over a period of time. However, not all marketed PRP devices are equal; they vary in quantity of blood required, platelet concentration, viability and number of spin cycles.⁴⁹ Harvest Technologies was one of the first PRP devices to gain FDA approval.⁵⁰ This system uses a

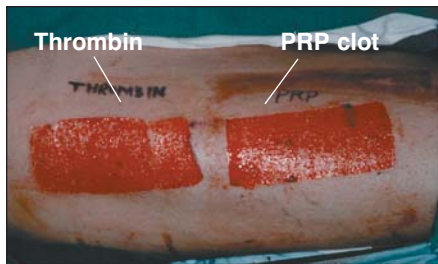


FIGURE 4A. Skin graft sites (left side control; right side PRP). Slide courtesy of Dr. Robert Marx, Chief Oral Maxillofacial Surgery, University of Miami. Used with permission.

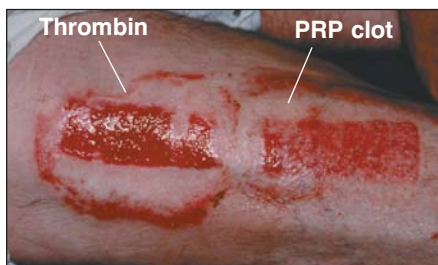


FIGURE 4B. Healing of skin graft with and without PRP. Skin graft site 7 days post-op showing PRP side with thicker epithelial covering and regression of the hypervascular phase indicating wound maturation, while control has thinner epithelial layer over a hypervascular connective tissue indicating immature healing. Slide courtesy of Dr. Robert Marx, Chief Oral Maxillofacial Surgery, University of Miami. Used with permission.

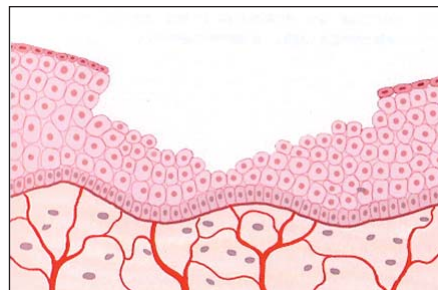


FIGURE 5A. Illustration of the split-thickness skin graft donor site (control; no PRP) at 45 days. From Marx R and Garg A. *Dental and craniofacial applications of platelet-rich plasma*. Quintessence Publishing Co. Inc. 2005. Used with permission.

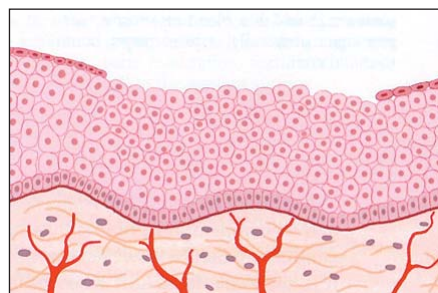


FIGURE 5B. Illustration of the split-thickness skin graft donor site with PRP enhancement at 45 days. From Marx R and Garg A. *Dental and craniofacial applications of platelet-rich plasma*. Quintessence Publishing Co. Inc. 2005. Used with permission.



FIGURE 6. Example of centrifugal PRP preparation machine (Harvest Technologies' SmartPREP[®]2 APC+™).

floating shelf technology which preserves the viability of platelets until use. In his 2005 text, Marx rated the PREP unit by Harvest Technologies, along with PCCS by Implant Innovations, as the two most effective and practical PRP devices for physician office use, outpatient surgery centers, and wound care center treatment.⁵¹

Creation and Activation of PRP

A small amount of the patient's blood is drawn (20-120 cc) into a syringe with a small amount of citrate (an anti-clotting agent) then typically spun for about 15 minutes in a special centrifugation system that separates the platelets, blood, and plasma. The plasma-poor layer is then drained off and the "buffy coat" plasma layer extracted along with a small amount of plasma and red cells. In the surgical setting, PRP is activated by the surgeon mixing in calcium chloride and/or thrombin to make a gel-like graft and then placing it where he/she wants accelerated healing. Type I collagen has also been found to be effective in activating and creating a PRP

graft.⁵² In 2006, Murray et al demonstrated successful increase in healing of a central anterior cruciate ligament (ACL) defect in a canine ACL using a collagen-platelet rich plasma matrix graft.⁵³ In some musculoskeletal studies, a 10% solution of calcium chloride is added to the PRP just prior to injection^{54,55} or is injected simultaneously via another syringe into the area being injected with PRP. Most commonly, however, connective tissue injections are given into the site where repair is needed without any additive. In that case, activation occurs by exposure to tendon-derived collagen released by the injured tissue which is being treated.^{56,57} "Peppering" the tissue during injection with the needle tip can help ensure endogenous thrombin release needed for activation.

Growth Factors in PRP Stimulate Repair

Growth factors present in granules are released when platelets are activated (see Figure 7).⁵⁸ After activation, secretion of growth factors begins within 10 minutes.

The viability of the platelets and continued release of growth factors into the tissue continues for seven days.⁵⁹ Meantime, the platelets stimulate the influx of macrophages,⁶⁰ stem cells and other repair cells, as discussed previously. Microtrauma created by the injection itself also stimulates influx of macrophages and growth factors as in the case of dextrose prolotherapy. Once the platelets die (average life span 7-10 days), the macrophages continue wound healing regulation by secreting some of the same growth factors as the platelets did, as well as others.⁶¹ The amount of initial platelets present in the wound determines the rate of wound healing and explains why PRP used during a surgical procedure speeds recovery.⁶² This may be because PRP has a strong effect in the early phase of healing.⁶³ Use of a "matrix" to hold the PRP material has been used—especially in the case of a large defect.

Optimum Platelet Concentration Level for PRP

Outpatient PRP preparation systems exist with the ability to concentrate platelets from two to eight times.⁶⁴ There is some controversy about what the "optimum" platelet concentration should be, but a level of at least 1 million platelets per μ L appears to be the "magic number." Since the average patient's platelet count is

200,000 +/- 75, a four to five times concentration appears to be the desired level.^{65,66} When levels are in the 5x range, the influx of adult stem cells has been noted to increase by over 200%.⁶⁷ In 2008, Kajikawa et al concluded that PRP enhances the initial mobilization of “circulation-derived cells” in the early stage of tendon healing. “Circulation-derived cells” are defined as mesenchymal stem cells that have the potential to differentiate into reparative fibroblasts or tenocytes as well as macrophages.⁶⁸ Under normal circumstances, circulation-derived cells last only a short time after tendon injury.⁶⁹ The authors suggest this as one of the main reasons for the known low healing ability of injured tendons. If the circulation derived cells could be activated and their time-dependant decrease stalled with PRP, then the wounded tendon could more fully heal. This study found an increase in the circulation-derived cells with the PRP group, as well as increased production of types I and III collagen in the PRP group versus control.⁷⁰ This finding of additional fibroblast proliferation and type I collagen production enhanced by increasing platelet concentrations concur with an earlier study by Lui et al.⁷¹ This provides evidence that PRP stimulates the chemotactic migration of human mesenchymal stem cells to the injury site in a dose-dependent manner—i.e., the more concentrated the platelets, the more stimulation.

There are also reports of less than four to five times concentration being effective, but it is possible that is a function of a higher starting baseline of platelets (i.e., the patient had a baseline of 400, thus a 2 or 3 fold expansion seemed to work well). It is also possible that studies which show the lack of effectiveness of PRP are in patients whose baseline platelet count is normally low, such that one million platelets/ μ L was not obtained.

Prolotherapy Versus PRP

The use of hyperosmolar dextrose (prolotherapy) has been shown to increase platelet-derived growth factor expression and up-regulate multiple mitogenic factors⁷² that may act as signaling mechanisms in tendon repair. Saline prolotherapy can have a similar effect.⁷³ An interesting study published in the January 2010 *JAMA* compared PRP versus saline injection (basically saline prolotherapy) for chronic Achilles tendinopathy. Both

groups improved “significantly” and the authors conclude there was no statistical difference between the improvement of both groups.⁷⁴ Therefore, both PRP and prolotherapy have been shown to stimulate natural healing⁷⁵ and both can be effective and both should be considered in the treatment plan for connective tissue repair. However, PRP may be more appropriate in some cases. When PRP is used as a prolotherapy “formula” for chronic or longstanding injuries, the PRP increases the initial healing factors and thereby the rate of healing. The prolotherapy itself (irritation, needle microtrauma) is what is “tricking” the body into initiating repair at these long forgotten sites as well as the PRP, itself, which also acts as an “irritating solution.” This is especially important with chronic injuries, degeneration and severe tendonosis, where the body has stopped recognizing that area as “something to repair.” In these cases, PRP may be more appropriate, however this determination should be made on an individual basis. PRP can also be used preferentially over dextrose prolotherapy in the case of a tendon sheath or muscle injury—areas occasionally but not typically treated with dextrose prolotherapy where the focus is the fibro-osseous junction (entheses).⁷⁶ It can also be used preferentially over dextrose prolotherapy because of patient preference (see Figure 8).

Whole Blood Injections Versus PRP

Even before PRP, it was not unheard of to use whole blood as a prolotherapy solution, especially where the patient was hypersensitive to other formulas.⁷⁷ A 2006 study in the *British Journal of Sports Medicine* studied the use of whole blood with “needling”(irritation such as with prolotherapy) and concluded that the use of autologous blood injection, combined with dry needling, “appears to be an effective treatment for medial epicondylitis.”⁷⁸ Another study in that same journal in 2009 compared injections using whole blood, dextrose prolotherapy, platelet rich plasma and polidocanol (a sclerosing agent), and concluded that there is evidence to support the use of each of these agents in the treatment of connective tissue damage.⁷⁹ However, there are only three known studies using whole blood, all of which were prospective case series without controls and small patient numbers.⁸⁰⁻⁸² PRP studies, on the other hand, are growing not only in number, but also

FIGURES 7A-7C. Activation of platelets results in growth factor release.

From Marx R and Garg A. *Dental and craniofacial applications of platelet-rich plasma*. Quintessence Publishing Co., Inc. 2005. Used with permission.

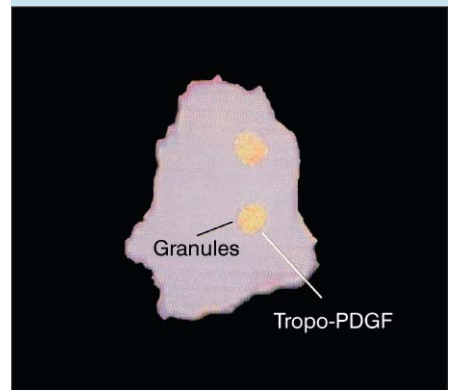

FIGURE 7A. Alpha granules in platelets contain incomplete protein and inactive growth factors.

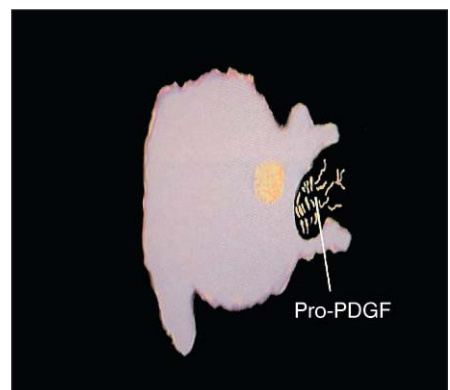


FIGURE 7B. The clotting process induces migration of the alpha granules to the cell surface, where the membrane of the alpha granules fuses to the platelet surface membrane.

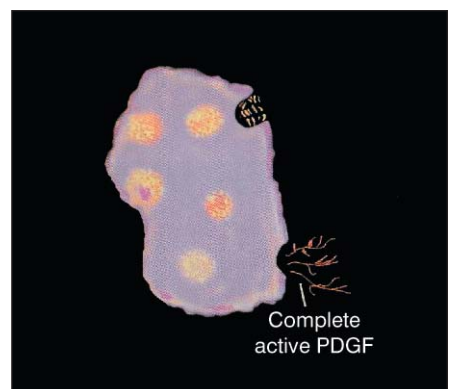


FIGURE 7C. The platelet surface membrane adds carbohydrate side chains and histones to the growth factors to make them bioactive.

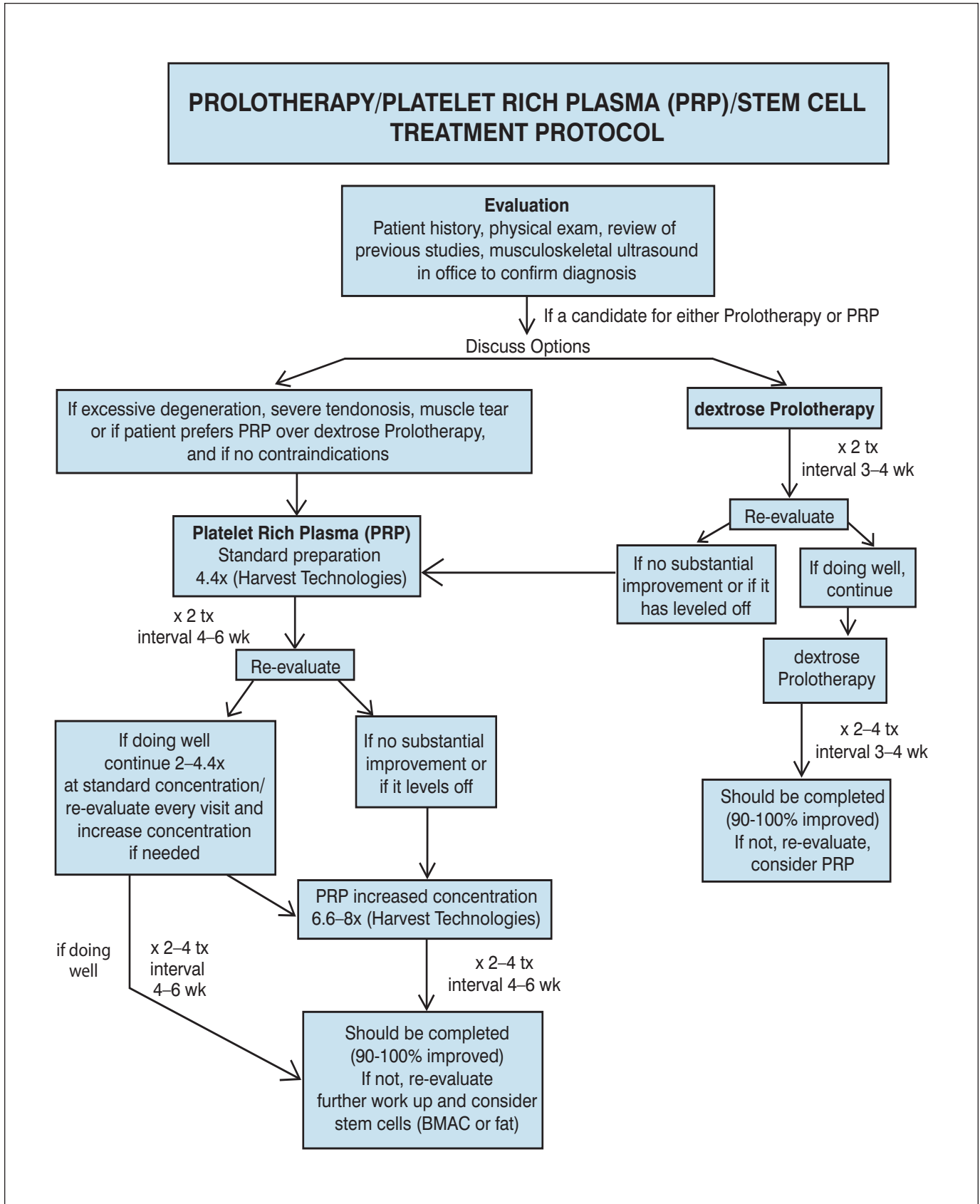


FIGURE 8. Prolotherapy, platelet rich plasma (PRP), and stem cell treatment protocol.

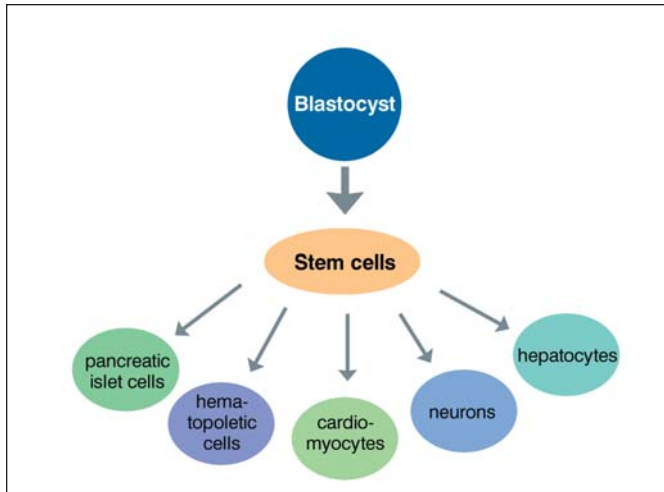


FIGURE 9. Fetal stem cells are pluripotent allowing them to differentiate into any cell type.

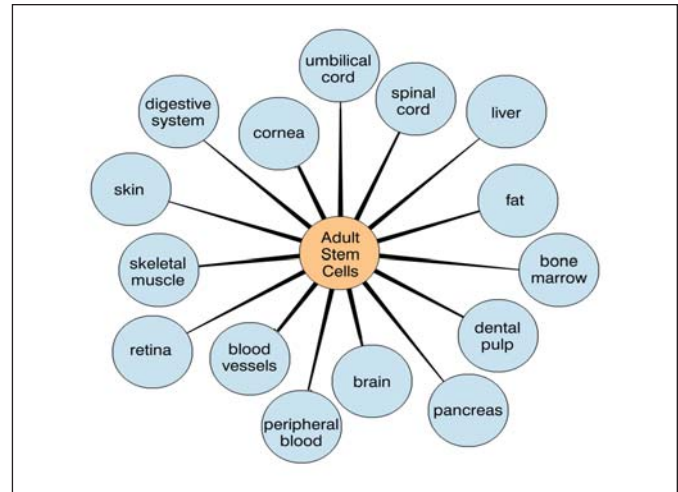


FIGURE 10. Adult stem cells are multipotent allowing them to only differentiate into a limited number of cell types.

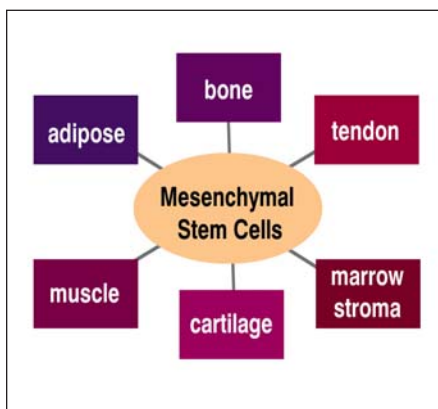


FIGURE 11. Mesenchymal stem cells (MSC) are multipotent and differentiate into musculoskeletal tissue.

technique was used in order to activate the thrombin release from the tendon—in this case endogenous thrombin is the activator for the injected platelet growth factors. The researchers indicate the importance of the “inflammation” phase *the first two days post treatment) during which there is a migration of macrophages to the injured tissue site. Macrophages release additional growth factors,⁸⁷ and there is increased collagen synthesis on days three to five. The conclusion of the Netherlands study was that “PRP reduces pain and significantly increases function, exceeding the effect of the corticosteroid injection.”⁸⁸

Safety Issues

Like prolotherapy, PRP therapy has low risk and few side effects. Concerns such as hyperplasia have been raised regarding the use of growth factors, however there have been no documented cases of carcinogenesis, hyperplasia, or tumor growth associated with the use of autologous PRP.⁸⁹ PRP growth factors never enter the cell or its nucleus and act through the stimulation of external cell membrane receptors of adult mesenchymal stem cells, fibroblasts, endothelial cells, osteoblasts, and epidermal cells.⁹⁰ This binding stimulates expression of a normal gene repair sequence, causing normal healing—only much faster. Therefore PRP has no ability to induce tumor formation.⁹¹ Also, because it is an autologous sample, the risk of allergy or infectious disease is considered negligible.⁹² Evidence also exists in studies that PRP may have an antibacterial effect.⁹³

Is PRP “Blood Doping”?

The answer to this question is unclear and the subject of controversy. Under current rules of the World Anti-Doping Agency (WADA) for Olympic athletes, PRP is prohibited via the “intramuscular” route with other routes of administration requiring a Therapeutic Use Exemption.⁹⁴ This WADA prohibition is based chiefly on the concern with the release of IGF-1 by activated platelets, although the type of IGF-1 released by platelets has too short a half-life to provide an athletic advantage, is the wrong isoform to create skeletal hypertrophy, and levels are subtherapeutic and therefore do not produce a systemic anabolic effect.⁹⁵ A Consensus Meeting on the topic is planned for Spring 2010 by the Medical & Scientific Commission of the International Olympic Committee.⁹⁶ Hopefully these restrictions will be lifted. While WADA regulates Olympic athletes, it does not have jurisdiction over professional sports leagues in the United States and PRP is not addressed specifically on any banned substances lists by those various leagues.

Stem Cell Prolotherapy: The Next Horizon

What if prolotherapy and then PRP were to fail? What is the next step, short of surgery (if surgery is even an option)? Since the early 1990s there has been an interest in “adult stem cells”—undifferentiated cells that can be isolated from many tissues in all stages of life.⁹⁷

Difference Between Fetal (Embryonic) and Adult Stem Cells

Fetal stem cells are generalized, full of potential, can give rise to any cell type, and

in quality.^{83,84} When examining the physiology of how activated platelets signal repair cells, it seems logical that using PRP (with higher levels of platelets per unit volume) be more effective than autologous blood although no study has yet directly compared the two.⁸⁵

Cortisone Versus PRP

The use of cortisone in musculoskeletal injuries is controversial and the subject of various studies over the years. In February 2010, researchers in the Netherlands published the results of a well designed, two year randomized controlled blinded trial with a significant test group of 100 patients, comparing corticosteroid use to an injection of concentrated platelet rich plasma⁸⁶ without ultrasound guidance. The PRP injection was given to the lateral epicondyle area of “maximum tenderness,” and a “peppering”

therefore deemed “pluripotent” (see Figure 9). Adult stem cells, on the other hand, are partially differentiated but can still give rise to cells from multiple lineages, and therefore deemed “multipotent” (see Figure 10). These adult stem cells are found throughout the body and exist in order to replenish dying cells and regenerate damaged tissue. Musculoskeletal tissues come from a type of adult stem cell known as the “mesenchymal” stem cell (MSC). MSCs can replicate as undifferentiated cells but also have the potential to differentiate into a variety of connective tissue cells⁹⁸ including bone, cartilage, fat, tendon, muscle, and adipose tissue.⁹⁹ Adult stem cells also produce useful growth factors and cytokines that may help repair additional tissues (see Figure 11).¹⁰⁰ The major reservoirs for mesenchymal stem cells are bone marrow and adipose tissue.¹⁰¹

History of Autologous Mesenchymal Adult Stem Cell Therapy

As early as 1993, the existence of mesenchymal stem cells—“non-committed progenitor cells of musculoskeletal tissues”—were known to have an active role in tissue repair.¹⁰² These cells, first labeled by Caplan of Case Western University in 1991 as “mesenchymal” stem cells (MSC)¹⁰³ because of their ability to differentiate to lineages of mesenchymal tissue, are known to be an essential component of the tissue repair process.¹⁰⁴ Some researchers believe that stem cells exist in every tissue, with bone marrow serving as one of the body’s main “reservoirs” from which extra stem cells are mobilized when needed.¹⁰⁵ It is well known that healing takes place more rapidly in children than adults, a fact credited to the increased number of stem cells in children. As early as 1998, researchers were studying the use of MSCs in tendon repair;¹⁰⁶ and concluded that the use of implanted adult stem cells delivered to tendon defects can “significantly improve the biomechanics, structure, and probably the function of the tendon after injury.”¹⁰⁷ MSC were deemed to be safe for human use in 1995¹⁰⁸ and, once safety was established, research efforts grew. In 1999, an article in *Science* described how these cells could be extracted from human bone marrow and then selectively induced to differentiate exclusively into either the adipocytic, chondrocytic or osteocytic lineages based on different processing protocols after extraction.¹⁰⁹

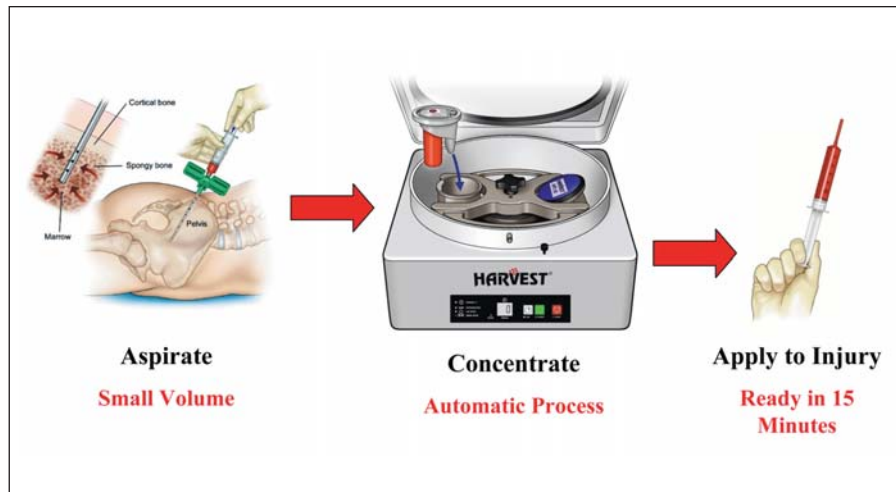


FIGURE 12. Example of a bone marrow aspirate concentrate machine (Harvest Technologies’ SmartPreP®2 BMAC2™ system).

Autologous Stem Cell Therapy for Osteoarthritis and Joint Regeneration

An interesting observation about MSCs is their ability to “home in” and repair areas of tissue injury, including osteoarthritis¹¹⁰⁻¹¹² and other injured types of tissue; for example ischemic heart tissue,^{113,114} graft-vs-host disease,¹¹⁵ and osteogenesis imperfecta.¹¹⁶ In certain degenerative diseases such as osteoarthritis, an individual’s stem cell potency appears depleted, with reduced proliferative capacity and ability to differentiate.^{117,118}

Researchers have developed protocols to process extracted autologous stem cells which encourage them to differentiate in the desired direction, whether towards cartilage, tendon, muscle or bone.¹¹⁹ Studies have demonstrated the regeneration of articular cartilage defects with adult stem cell therapy.^{120,121} In 2003, Murphy et al found significant improvement in medial meniscus and cartilage regeneration with stem cell therapy in an animal model.¹²² Not only was there evidence of marked regeneration of meniscal tissue, but the usual progressive destruction of articular cartilage, osteophytic remodeling and subchondral sclerosis seen in osteoarthritic disease were reduced in MSC-treated joints compared with controls.¹²³ In 2008,

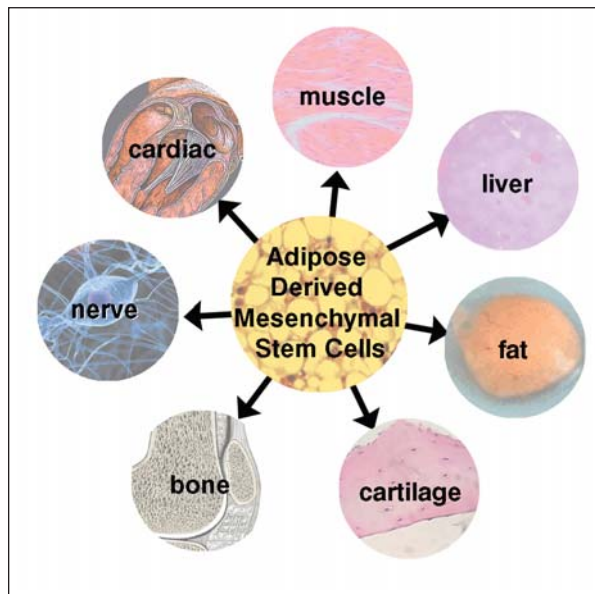


FIGURE 13. Adipose tissue-derived stem cell differentiation.

Centeno et al documented significant knee cartilage growth and symptom improvement in a human case report using culture expanded autologous MSCs from bone marrow.¹²⁴

Bone Marrow Aspirate Concentrate (BMAC)

Bone marrow has classically been the reservoir used to harvest stem cells. Bone marrow aspiration is commonly done in the office setting with local anesthesia and is tolerated well by most patients.¹²⁵ Once harvested, the stem cells need to be isolated.¹²⁶ In addition to isolation, concentrating the cells is important and related to effectiveness.¹²⁷ Some of the available systems that process PRP, such

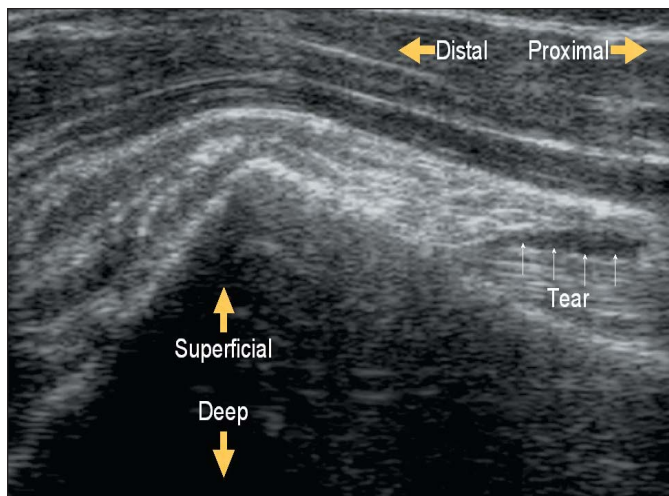


FIGURE 14A. Tear of long head biceps tendon in a 70 year-old patient (ultrasound image before PRP treatments).

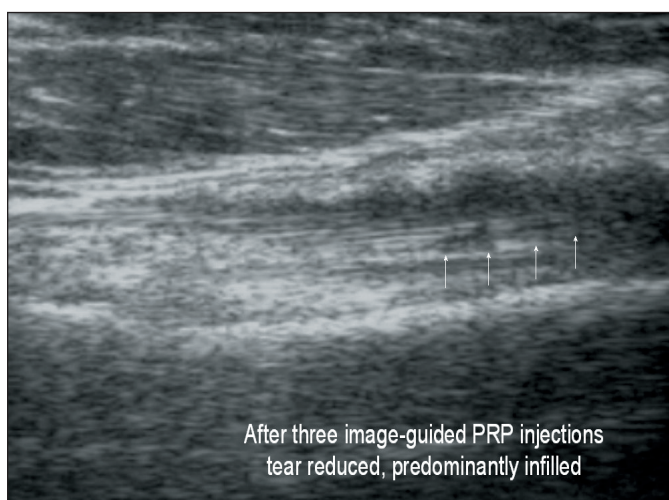


FIGURE 14B. Resolved tear of long head biceps tendon post three ultrasound image-guided PRP injections.

as Harvests Smart PRP 2, are also FDA-approved to isolate and concentrate the bone marrow aspirate into a bone marrow aspirate concentrate (BMAC; see Figure 12).¹²⁸ Concentration of the bone marrow is an important element of efficacy.^{129,130} Once concentrated, BMAC has been shown to have comparable cell counts as allograft, with less morbidity. This autologous bone marrow aspirate contains not only mesenchymal stem cells but also accessory cells that support angiogenesis and vasculogenesis by producing growth factors and cytokines. There is increasing evidence that combined use of bone marrow aspirate and PRP show equivalence to autologous bone grafting.¹³¹ BMAC has also been shown to be a safe and effective treatment for tibial nonunion,¹³² metatarsal non-unions and Jones fracture,¹³³ osteonecrosis of the hip,^{134,135} osteochondral defect repair,¹³⁶ and limb ischemia.¹³⁷ Results of a huge five year study in India for non-reconstructable critical limb ischemia demonstrated that BMAC provided an amputation-free survival of 90%, with pain reduction of over 90%.¹³⁸ Other musculoskeletal applications also exist¹³⁹ with more studies planned.

Adipose-Derived Stem Cells

Human adipose tissue has been shown to be an abundant and rich source of adult stem cells with a population of cells that possesses extensive proliferative capacity, and the ability to differentiate into multiple cell lineages.¹⁴⁰ Most people do not mind giving up a little fat and, in fact, many electively undergo liposuction procedures, which yield large volumes of useable adipose tissue.¹⁴¹ Adipose-derived stem cells can differentiate towards osteogenic, adipogenic, myogenic and chondrogenic, and neurogenic lineages (see Figure 13).¹⁴² Fat grafting has been popular in cosmetic procedures for the last several years and adipose-derived mesenchymal stem cells (AD-MSCs) are now beginning to be used in musculoskeletal medicine—either with or without PRP—to create a gel matrix or bioactive scaffold to hold the essential “inflammatory boost” in a joint area.¹⁴³ AD-MSCs are similar but not identical to bone marrow mesenchymal stem cells (BM-MSCs).¹⁴⁴ Additionally, AD-MSCs can be easily isolated from the adipose tissue in significant numbers, are easy to process, and have low donor morbidity. AD-MSCs have been used with PRP and BMAC in the treatment of many musculoskeletal and vascular disorders. It is believed that the PRP fat graft is inducted by its environment to form the type of cell which surrounds it. For example, if it is placed with muscle cells it was differentiate into muscle and be incorporated there.¹⁴⁵ Because of the increased simplicity of fat harvesting versus bone marrow aspiration, the use of autologous adipose tissue is gaining popularity for office use. Also, the yield of stem cells from adipose tissue is higher than with bone marrow, with typical MSC yield for bone marrow between 1 in 50,000 and 1 in 1 million in a skeletally mature adult compared to adipose tissue which yields 1 in 30 and 1 in 1,000 active undifferentiated stem cells.¹⁴⁶ Studies show that human AD-MSCs may be promising for neurological autoimmune disorders¹⁴⁷ musculoskeletal autoimmune issues such as rheumatoid arthritis,¹⁴⁸ for disc regeneration,¹⁴⁹ and chronic osteoarthritis¹⁵⁰ in animal models. Inevitably the use of AD-MSCs in musculoskeletal medicine will continue to grow.

FDA Considerations

Controversy over the use of fetal stem cells are eliminated with the use of autologous adult stem cells, but regulation still exists in terms of how these cells are used. Autologous adult stem cells are considered “Human Cells, Tissues and Cellular-Based Products (HCT/Ps)” and thus regulated by the FDA.¹⁵¹ However, exemption from regulation exists if the physician “removes HCT/Ps from an individual and implants such HCT/Ps into the same individual during the same surgical procedure.”¹⁵²

To be considered as occurring “during the same surgical procedure” the cells must be “autologous,” “minimally manipulated,” and “used within a short period time.”¹⁵³ “Minimally manipulated” is defined as “processing that does not alter the relevant biological characteristics of cells or tissues.”¹⁵⁴ “Short period of time” is not exactly defined but per the “FDA Guidance for Industry” is considered to be “a matter of hours (or less), without the need for shipping.”¹⁵⁵ “More than minimal” manipulation involves: “the use of drugs, biologics, and/or additional devices that warrants regulation of the manufacturing process and the resulting cells as biological products.” This is where the culture expansion of cells comes into question. In fact, the FDA defines cultured bone marrow cells as “combination products” which “may be regulated as devices or biological products” and

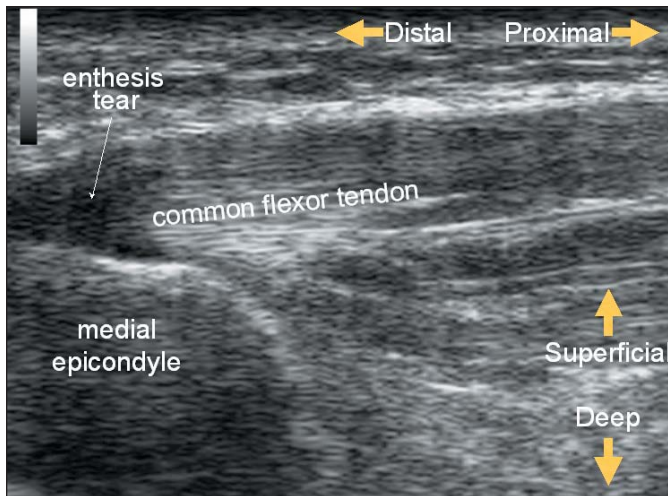


FIGURE 15A. *Ultrasound image of medial epicondylitis in 33-year-old patient of two years continuous duration (origins in high school tennis).*

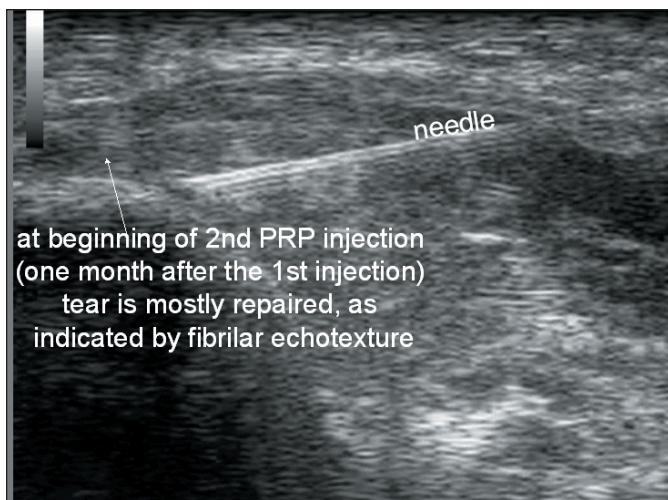


FIGURE 15B. *Fibrillar echotexture at beginning of 2nd PRP injection (one month after first injection) indicates that tear is mostly repaired.*

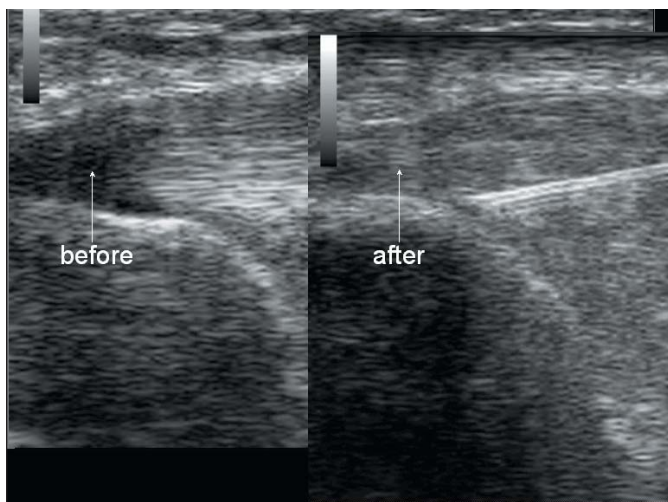


FIGURE 15C. *Ultrasound images before and after PRP injections treatment.*

indicates that “these products are currently under review.”¹⁵⁶

Therefore, the culture expansion of stem cells, while delivering higher yields, is problematic in terms of FDA requirements. For now it is clear that harvesting of autologous stem cells—either with BMAC or fat extraction—at the point of care, does not pose any problem as far as FDA regulation is concerned as long as exemption criteria are met.

Musculoskeletal Ultrasound

Musculoskeletal ultrasound has been used by physicians, especially rheumatologists, in Europe for many years. Various machines exist, many are portable, and image quality has improved by light years in the past decade. Introduced to the U.S. within the last few years, musculoskeletal ultrasound allows high resolution, real time imaging of articular and periarticular—structures such as ligament, tendons, and cartilage, including tears and tendonosis—and can be used in the office setting to give quick answers and is also highly acceptable to patients.¹⁵⁷ However, there are limitations, with one of the chief being the time it takes to learn. As stated by Dr. Rosenquist, an anesthesiologist at the University of Iowa, “It’s not something you pick up after staying at a Holiday Inn Express.”¹⁵⁸ There is a high degree of operator variability with the technique, lack of standardization and a long learning curve.¹⁵⁹ Musculoskeletal ultrasound is more common in Europe than the U.S. and in some European countries is part of physician training.¹⁶⁰ The European Society of Musculoskeletal Radiology has established technical guidelines, protocols and hands-on training since 1994.¹⁶¹ In the U.S., there is growing demand for training in this emerging field and there are more and more courses being offered each year by various institutions.

Many prolotherapists produce spectacular results while being “low tech” without the use or necessity of musculoskeletal ultrasound. And imaging does not, nor should it, supplant the physician’s “common sense.” Imaging studies are notoriously unreliable in terms of musculoskeletal pain, with multiple studies showing a high percentage of abnormal scans in asymptomatic individuals¹⁶²⁻¹⁶⁵ and thus should always be correlated to the patient history and area of complaint. However, when imaging equipment is used—especially where testing can be addressed specifically to an area of complaint, along with dynamic (motion) analysis—these ultrasound studies can add useful additional information for the physician. However, a physician should avoid using it as the sole source of diagnosis but always take a good history and physical and have an understanding of the cause of a patient’s problem first before using imaging as a confirmation. Use of ultrasound guidance for injections may or may not be needed, depending on the specific problem being treated. Some of the PRP studies cited above did not use ultrasound guidance¹⁶⁶ yet still obtained excellent results for the participants. Knowledge of anatomy and good technique goes a long way in the prolotherapy world and only administering injections with ultrasound guidance may limit the treatment scope, especially in a case of tendonosis where there is no discrete lesion. However, when indicated—as in the case of a discrete tear or effusion—the ability to visualize an injection under guidance, or the use of ultrasound to confirm a diagnosis, can be satisfying for the patient as well as the physician. Ultrasound can also help to objectively document change in tissue which otherwise would be purely subjective (see Figures 14 and 15).

Conclusion

Marx and Garg write: “Surgeons do not heal tissue; they merely place it where nature can heal it.”¹⁶⁷ With advances in science we are able to offer our patients safe, effective alternatives to surgery. Traditional prolotherapy, platelet rich plasma, and now stem cell therapy are available to enhance healing of musculoskeletal injuries and pain, along with musculoskeletal ultrasound for added diagnostic acumen. Yet, in spite of all these wonderful technological advances, there may still be times when the “low tech” approach is more practical. Technology is just a tool and should never become an obsession or violate common sense. Treating the patient in front of you and understanding what options are available for his or her condition will always be the foundation of good patient care, new age or old. ■

*Donna Alderman, DO is a graduate of Western University of Health Sciences, College of Osteopathic Medicine of the Pacific, in Pomona, California, with undergraduate degree from Cornell University in Ithaca, NY. She has extensive training in prolotherapy and has been using prolotherapy in her practice for ten years. Dr. Alderman is the Medical Director of Hemwall Family Medical Centers in California and can be reached through her website www.prolotherapy.com. In 2008, she authored the book *Free Yourself from Chronic Pain and Sports Injuries* (ISBN 9780981524207) published by Family Doctor Press, Glendale, California.*

References

1. Tendon Trouble: New treatment uses enhanced plasma. Mayo Clinic Health Letter. www.HealthLetter.MayoClinic.com. March 2010. p 7. Accessed 24 Apr 2010.
2. Foster T, Puskas B, Mandelbaum B, et al. Platelet rich plasma: From basic science to Clinical Applications. The American Journal of Sports Medicine. 2009. 37(11).
3. Hauser R and Hauser M. Platelet rich plasma (PRP) injection technique. Journal of Prolotherapy. 2009. 1(3): 184.
4. Alternative treatments: Dealing with chronic pain. Mayo Clinic Health Letter. April 2005. 23(4).
5. Prockop D, Phinney D, and Bunnell B. Mesenchymal Stem Cells, Methods and Protocols. Chapters 2 and 4. Humana Press, a part of Springer Science, NJ. 2008.
6. Hackett GS, Hemwall GA, and Montgomery GA. Ligament and tendon relaxation treated by prolotherapy. (1956 First Edition Charles C. Thomas, Publisher). Fifth Edition Gustav A. Hemwall, Publisher. Institute in Basic Life Principles. Oak Brook, IL. 1991.
7. Fullerton BD. High resolution ultrasound and magnetic resonance imaging to document tissue repair after prolotherapy. Arch PM&R. 2008. 89(2): 377-385.

8. Alderman D. A history of the American College of Osteopathic Sclerotherapeutic Pain Management, the oldest prolotherapy organization. Journal of Prolotherapy. Nov 2009. 1(4): 200-204.
9. Gedney E. Special technic: hypermobile joint: a preliminary report. Osteopathic Profession. 1937. 9: 30-31
10. Gedney E. The hypermobile joint—further reports on injection method at the February 13, 1938 meeting of the Osteopathic Clinical Society of Philadelphia.
11. Alderman D. Prolotherapy for musculoskeletal pain. Pract Pain Manag. Jan/Feb 2007. 791): 10-16.
12. Rabago D, Best T, Beamsley M, and Patterson, J. A systematic review of prolotherapy for chronic musculoskeletal pain. Clin. J. Sport Med. 2005. 15(5).
13. Des Rosiers E, Yahia L, and Rivard C. Proliferative and matrix synthesis response of canine anterior cruciate ligament fibroblasts submitted to combined growth factors. J. Orthop Res. 1996. 14: 200-208.
14. Kang H and Kang ED. Ideal concentration of growth factors in rabbits flexor tendon culture. Yonsei Medical Journal. 1999. 40: 26-29.
15. Lee J, Harwood F, Akeson W, et al. Growth factor expression in healing rabbit medial collateral and anterior cruciate ligaments. Iowa Orthopedic Journal. 1998. 18: 19-25.
16. Marui T, Niyibizi C, Georgescu HI, et al. Effect of growth factors on matrix synthesis by ligament fibroblasts. J Orthop Res. 1997. 15: 18-27.
17. Spindler KP, Imro AK, and Mayes CE. Patellar tendon and anterior cruciate ligament have different mitogenic responses to platelet-derived growth factor and transforming growth factor beta. J. Orthop Res. 1996. 14: 542-546.
18. Liu Y. An in situ study of the influence of a sclerosing solution in rabbit medial collateral ligaments and its junction strength. Connective Tissue Research. 1983. 11(2): 95-102.
19. Maynard JA, Pedrini VA, Pedrini-Mille A, Romanus B, and Ohlerking F. Morphological and biochemical effects of sodium morrhuate on tendons. Journal of Orthopedic Research. 1983. 3: 236-248.
20. Hall M, Bank P, Meislin R, Jazrawi L, and Cardone D. Platelet-rich plasma: Current concepts and application in sports medicine. Journal of the American Academy of Orthopedic Surgeons. 2009. 27: 602-608.
21. Marx R, Kevy S, and Jacobson M. Platelet rich plasma (PRP): A primer. Pract Pain Manag. Mar 2008. 8(2): 46,47.
22. Ibid. ref 21.
23. Ibid. ref. 2.
24. Creaney L and Hamilton B. Growth factor delivery methods in the management of sports injuries: the state of play. British J Sports Med. 2008. 42: 314-320.
25. Marx R and Garg A. Dental and Craniofacial Applications of Platelet-Rich Plasma. Quintessence Publishing Co. 2005.
26. Haynesworth et al. Chemotactic and Mitogenic Stimulation of Human Mesenchymal Stem Cells by platelet rich plasma Suggests a Mechanism for Enhancement of Bone Repair. DePuy Orthopedics and Case Western University. Presented at 48th Meeting of the Orthopaedic Research Society, Dallas, TX 2002, available at www.perstat.com/ortho1.pdf. Accessed 24 Apr 2010.
27. Marx R. Platelet-rich plasma: evidence to support its use. J Oral Maxillofac Surgery. 2004 62: 489-496.
28. Ibid. ref. 25; p 4.
29. Ibid. ref. 2.
30. Ibid. ref. 25; p 31.
31. Garg A. The use of platelet rich plasma to enhance the success of bone grafts around dental implants. Dent Implantol Update. 2000 11: 17.
32. Kassolis J, Rosen P, and Reynolds M. Alveolar ridge and sinus augmentation utilizing platelet rich plasma in combination with freeze-dried bone allograft. Case series. J. Periodon. 2000. 71: 1654.
33. Alexander R, Abuzeni P. Enhancement of autologous fat transplantation with platelet rich plasma. Am J. Cosmet Surg. 2001. 18: 59-70.
34. Mishra, A and Pavelko T. Treatment of chronic elbow tendonosis with buffered platelet-rich plasma. American Journal of Sports Medicine. 2006 34(11): 1774-1778.
35. Dines and Postinao. Plasma Helps Hines Ward Be Super, NY Daily News, Feb 8, 2009. www.nydailynews.com/sports/2009/02/07/2009-02-07_plasma_helps_hines_ward_be_super-2.html#ixzz0ivc1qaXu. Accessed 24 Apr 2010.
36. Schwarz A. A Promising New Treatment for Athletes in Blood. NY Times. Feb 16, 2009. <http://www.nytimes.com/2009/02/17/sports/17blood.html>. Accessed 24 Apr 2010.
37. Ibid. ref. 20.
38. Sanchez M, Anita E, et al. Intra-articular injection of an autologous preparation rich in growth factors for the treatment of knee OA: A retrospective cohort study. Clin Exp Rheumatol. 2008. 26(5): 910-913.
39. Kon E, Buda R, Filardo G, et al. Platelet-rich plasma: intra-articular knee injections produced favorable results on degenerative cartilage lesions. Knee Surgery, Sports Traumatology, Arthroscopy. April 2010. 18(4).
40. Ibid. ref. 34.
41. Hammond J, Hinton R, Curl L, et al. Use of autologous platelet-rich plasma to treat muscle strain injuries. The American Journal of Sports Medicine. Jun 2009. 37(6): 1135-1142.
42. Sanchez M, Anita E, Andia I. Application of autologous growth factors on skeletal muscle healing. Poster Presentation at 2nd World Conference on Regenerative Medicine, May 2005, <http://www.harvesttech.com/pdf/Orthopedic-PRP/Sports%20Medicine/66-SanchezRegMed2005.pdf>. Accessed 24 Apr 2010.
43. Filardo G, Kon E, Della Villa S, et al. Use of platelet-rich plasma for the treatment of refractory jumpers knee. International Orthopaedics. Published online ahead of print. Jul 31, 2009.
44. Barrett S and Erredge S. Growth factors for chronic plantar fasciitis? Podiatry Today. 2004. 17(11).
45. Scarpone M et al. PRP as a treatment alternative for symptomatic rotator cuff tendinopathy for patients failing conservative treatments. Techniques in Orthopaedics. 22(1): 26-33.
46. De Vos R, van Veldhoven P, Moen M, et al. Autologous growth factor injections in chronic tendinopathy: a systematic review. British Medical Bulletin. Mar 2, 2010. <http://bmb.oxfordjournals.org/cgi/content/full/ldq006v1>. Accessed 24 Apr 2010.
47. De Vos RJ, Weir A, van Schie HT, Bierma-Zeinstra SM, Verhaar JA, Weinans H., and Tol JL. Platelet-rich plasma injection for chronic Achilles tendinopathy: a randomized controlled trial. JAMA. Jan 13, 2010. 303(2): 144-149.
48. Kevy S and Jacobson M. Comparison of methods for point of care preparation of autologous platelet gel. Journal of the American Society of Extra-Corporeal Technology. Mar 2004. 36(1): 28-35.
49. Ibid. ref. 27.
50. www.harvesttech.com. Accessed 24 Apr 2010.
51. Ibid. ref. 25; pp 43-48.
52. Fufa D, Shealy B, Jacobson M, et al. Activation of platelet-rich plasma using soluble type I collagen. J. Oral Maxillofac Surg. 2008. 66(4): 684-690.
53. Murray M, Spindler K, Devin C, et al. Use of a col-

- lagen-platelet rich plasma scaffold to stimulate healing of a central defect in the canine ACL. *Journal of Orthopaedic Research*. Apr 2006. pp 820-830.
54. Kon E, Filardo G, et al. Platelet-rich plasma: New clinical application. A pilot study for treatment of jumpers knee injury. *International Journal of the Care of the Injured*. Jun 2009. 40(6): 598-603.
55. Ibid. ref. 43.
56. Ibid. ref. 52.
57. Ibid. ref. 20.
58. Ibid. ref. 25;
59. Ibid. ref. 27.
60. Ibid. ref. 27.
61. Ibid. ref. 27.
62. Sanchez, M., Anuita, E., et al. Comparison of surgically repaired Achilles tendon tears using platelet-rich fibrin matrices. *Am J Sports Med*. Feb 2007. 25(2): 245-51.
63. Lyras D, Kazakos K, Verettas D, et al. The effect of platelet-rich plasma gel in the early phase of patellar tendon healing. *Arch Orthop Trauma Surg*. 2009. 129: 1577-1582.
64. Ibid. ref. 26.
65. Ibid. ref. 27.
66. Ibid. ref. 26.
67. Ibid. ref. 66.
68. Kajikawa Y, Morihara T, Sakamoto H, Matsuda K, Oshima Y, Yoshida A, Nagae M, Arai Y, Kawata M, and Toshikazu K. Platelet-Rich Plasma Enhances the Initial Mobilization of Circulation-Derived Cells for Tendon Healing. *J. Cell. Physiol*. 2008. 215: 837-845.
69. Kajikawa Y, Morihara T, Watanabe N, Sakamoto H, Matsuda K, Kobayashi M, Oshima Y, Yoshida A, Kawata M, and Kubo T. GFP chimeric models exhibited a biphasic pattern of mesenchymal cell invasion in tendon healing. *J. Cell. Physiol*. 210: 684-691.
70. Ibid. ref. 68.
71. Lui Y, Kalen A, Risto O, et al. Fibroblast proliferation due to exposure to a platelet concentrate in vitro is pH dependent. *Wound Repair Regen*. 2002. 10: 336.
72. DiPaolo S, Gesualdo L, Rainieri E, Grandaliano G, and Schena F. High glucose concentration induces the overexpression of transforming growth factor-B1 through the activation of a platelet-derived growth factor loop in human mesangial cells. *Am. J. Pathol*. 1996. 149(6): 2095-2106.
73. Yelland M, Glasziou P, Bogduk N, et al. Prolotherapy injections, saline injections, and exercises for chronic low back pain: a randomized trial. *Spine*. 2004. 29: 9-16.
74. Ibid. ref. 47.
75. Clark G. platelet rich plasma (PRP) Therapy Literature Reviews. *Journal of Prolotherapy*, Aug 2009. 1(3): 185-191.
76. Ibid. ref. 11.
77. Personal correspondence with Gerald Harris, DO, Trustee of American College of Osteopathic Sclerotherapeutic Pain Management.
78. Suresh S, Ali K, Jones H, and Connell D. Medial epicondylitis: is ultrasound guided autologous blood injection an effective treatment? *British Journal of Sports Medicine*. 2006. 40(1): 935-939.
79. Best T, Zgierska A, Zeisig E, Ryan M, and Crane, D. A systematic review of four injection therapies for lateral epicondylitis: prolotherapy, polidocanol, whole blood and platelet rich plasma. *British Journal of Sports Medicine*. Jul 2009. 43(7): 471-481.
80. Edwards SG and Calandruccio JH. Autologous blood injections for refractory lateral epicondylitis. *J. Hand Surgery Am*. 2003. 28: 272-278.
81. Gani NU, Butt MF, Dhar SA, et al. Autologous blood injection in the treatment of refractory tennis elbow. *The Internet Journal of Orthopedic Surgery*. 2007. 5.
82. Ibid. ref. 78.
83. Ibid. ref. 75.
84. Ibid. ref. 47.
85. Autologous blood injection. Wikipedia. http://en.wikipedia.org/wiki/Autologous_blood_injection. Access 24 Apr 2010.
86. Peerbooms J, Sluimer J, Brujin D, and Gosens T. Positive Effect of an Autologous Platelet Concentrate in Lateral Epicondylitis in a Double-Blind Randomized Controlled Trial. *The American Journal of Sports Medicine*. 2009. 38(2): 255-262.
87. Ibid. ref. 86; p 260.
88. Ibid. ref. 86; p 255.
89. Ibid. ref. 24.
90. Marx R. The biology of platelet-rich plasma (reply to letter to the editor). *J.Oral Maxillofac Surg*. 2001. 59: 1120.
91. Schmitz JP and Hollinger J. The biology of platelet-rich plasma (letter to the editor) *J. Oral Maxillofac Surg*. 2001. 59: 1119.
92. Sanchez A, Sheridan P, and Kupp L. Is platelet-rich plasma the perfect enhancement factor? A current review. *Int. J. Oral Maxillofac Implants*. 2002. 18: 93-103.
93. Bielecki T, Gazdik T, Arendt J, et al. Antibacterial effect of autologous platelet gel enriched with growth factors and other active substances. *British Journal of Bone and Joint Surgery*. 2007. 89-B(3): 417-420.
94. www.wada-ama.org/Documents/Science_Medicine/Scientific%20Events/TUEC_Symposium_Strasbourg_2009/WADA-TUEC-Symposium-PRP-in-Light-of-2010-Prohibited-List.pdf. Accessed 24 Apr 2010.
95. Ibid. ref. 24.
96. Ibid. ref. 94.
97. Ibid. ref. 5; pp 27-28.
98. Pittenger M, Mackay A, Beck S, et al. Multilineage potential of adult human mesenchymal stem cells. *Science*. 1999. 284(5411): 143-147.
99. Ibid. ref. 98.
100. Ibid. ref. 5; p 27.
101. Ibid. ref. 5;
102. Caplan A, Fink D, Goto T, et al. Mesenchymal stem cells and tissue repair. In: *The anterior cruciate ligament: current and future concepts*. Jackson DW (ed). Raven Press. New York. 1993. pp 405-417.
103. Caplan A. Mesenchymal stem cells. *J. Orthop. Res*. 1991. (9): 641-650.
104. Ibid. ref. 26.
105. Luyten F. Mesenchymal stem cells in osteoarthritis. *Curr. Opin. Rheumatol*. 2004. 16: 559-603.
106. Young R, Butler D, Weberm W, et al. Use of mesenchymal stem cells in a collagen matrix for Achilles tendon repair. *J. Orthop Res*. 1998. 16: 406-413.
107. Ibid. ref. 106.
108. Lazarus H, Haynesworth S, Gerson S, et al. Ex vivo expansion and subsequent infusion of human bone marrow-derived stromal derived progenitor cells (mesenchymal progenitor cells); implications for therapeutic use. *Bone Marrow Transplant*. 1995. 16(4): 557-564.
109. Ibid. ref. 98.
110. Murphy J, Fink D, Hunziker E, and Barry F. Stem cell therapy in a caprine model of osteoarthritis. *Arthritis Rheum*. 2003. 48(12): 3464-3474.
111. Centeno C, Busse D, Kisiday J, et al. Increased Knee Cartilage Volume in Degenerative Joint Disease using Percutaneously Implanted, Autologous Mesenchymal Stem Cells. *Pain Physician*. 2008. 11(3): 343-353.
112. Ibid. ref. 110.
113. Kraitchman D, Tatsumi M, Gilson W, et al. Dynamic imaging of allogenic mesenchymal stem cells trafficking to myocardial infarction. *Circulation*. 2005. 107(18): 2290-2293.
114. Amado L, Sallaris A, Schuleri K, et al. Cardiac repair with intramyocardial injection of allogenic mesenchymal stem cells after myocardial infarction. *Proc. Natl. Acad. Sci. USA*. 2005. 102(32): 11-474 to 11-479.
115. Le Blanc K, Rasmusson I, Sundberg B, et al. Treatment of severe acute graft-versus-host disease with third party haploidentical mesenchymal stem cells. *Lancet*. 363 (9419): 1438-1441.
116. Horwitz E, Gordon P, Koo W, et al. Isolated allogenic bone marrow-derived mesenchymal cells engraft and stimulate growth in children with osteogenesis imperfect: Implications for cell therapy of bone. *Proc. Natl. Acad. Sci. USA*. 2002. 99(13): 8932-8937.
117. Murphy J, Dixon K, Beck S, et al. Reduced chondrogenic and adipogenic activity of mesenchymal stem cells from patients with advanced osteoarthritis. *Arthritis Rheum*. 2002. 46: 704-713.
118. Ibid. ref. 105.
119. Ibid. ref. 5.
120. Wakitani S, Goto T, and Pineda S. Mesenchymal cell-based repair of large, full-thickness defects of articular CARTILAGE. *J. Bone Joint Surg. (Am)* 1994. 76: 579-592.
121. Wakitani S, Imoto K, Yamamoto T, et al. Human autologous culture expanded bone marrow mesenchymal cell transplantation for repair of cartilage defects in osteoarthritic knees. *Osteoarthritis Cartilage*. 2002. 10: 199-206.
122. Ibid. ref. 110.
123. Ibid. ref. 110.
124. Ibid. ref. 111.
125. Ibid. ref. 5; p 29.
126. Ibid. ref. 5; p 59.
127. Ibid. ref. 127.
128. www.harvesttech.com/products/stemcells/smart-prep.html. Accessed 24 Apr 2010.
129. Saigawa T, Kato K, Ozawa T, et al. Clinical Application of Bone Marrow Implantation in Patients With Arteriosclerosis Obliterans, and the Association Between Efficacy and the Number of Implanted Bone Marrow Cells. *Circulation J*. 2004. 68: 1189-1193.
130. Ibid. ref 127.
131. Pinzur MS. Use of platelet-rich concentrate and bone marrow aspirate in high-risk patients with Charcot arthropathy of the foot. *Foot Ankle Int*. Feb 2009. 30(2): 124-127.
132. Ibid. ref. 127.
133. Leal L. Adult stem cell treatment strategy for Jones fracture and nonunion of the proximal fifth metatarsal. *Case Report*. October 14, 2007. Palisades Medical Center. North Bergen, New Jersey.
134. Hernigou P and Beaujean F. Treatment of osteonecrosis with autologous bone marrow grafting. *Clinical Orthopaedics and Related Research* 2002. (405): 14-23.
135. Gangji V and Hauzeur J. Treatment of osteonecrosis of the femoral head with implantation of autologous bone-marrow cells. *The Journal of Bone and Joint Surgery*. Jun 2004. 86-A: 1153-1160.
136. Brief A. Less invasive osteochondral defect repair of the talus using percutaneous delivery of concentrated autologous adult stem cells. October 14, 2007. New Jersey Orthopedic Specialists. www.njorthopedics.com. Accessed 24 Apr 2010.
137. Yuyama et al. Therapeutic Angiogenesis for Patients with Limb Ischemia by Autologous Transplantation of Bone Marrow Cells: A Pilot Study and Ran-

(references continued on page 72)

(references continued from page 69)

- domized Controlled Study. *The Lancet*. 2002. 360: 427-435.
138. http://www.harvesttech.com/pdf/PRESS%20RELEASE%20CLI%20India%20Study_v1_Dec%201%2009_.pdf. Accessed 24 Apr 2010.
139. Hauser R and Wei N. Researching the Regeneration of Articular Cartilage with Stem Cell Prolotherapy: An Interview with Nathan Wei, MD. *Journal of Prolotherapy*. May 2010. Vol 2(2).
140. Ogawa R. The Importance of Adipose-Derived Stem Cells and Vascularized Tissue Regeneration in the Field of Tissue Transplantation. *Current Stem Cell Research & Therapy*. 2006. (2): 13-20.
141. Alexander R. Chapter 14: Use of platelet rich plasma to Enhance Autologous Fat Grafting. *Autologous Fat Transfer: Art, Science, and Clinical Practice*. Melvin A. Shiffman (ed.). Springer Publications. 2010.
142. Ibid. ref. 5; p 69.
143. Ibid. ref. 141.
144. Ibid. ref. 5; p 59.
145. Ibid. ref. 141.
146. Ibid. ref. 5;
147. Marconi C, Rossi B, Angiari S, et al. Adipose-derived mesenchymal stem cells ameliorate chronic experimental autoimmune encephalomyelitis. *Stem Cells*. Oct 2009. 27(10): 2624-2635.
148. Gonzalez-Rey E, Gonzalez MA, Varela N, et al. Human adipose-derived mesenchymal stem cells reduce inflammatory and T cell responses and induce regulatory T cells *in vitro* in rheumatoid arthritis. *Ann Rheum Dis*. Jan 2010. 69(1): 241-248.
149. Tapp H, Deepe R, Ingram J, et al. Adipose-derived mesenchymal stem cells from the sand rat: transforming growth factor beta and 3D co-culture with human disc cells stimulate proteoglycan and collagen type I rich extracellular matrix. *Arthritis Research and Therapy*. 2008. 10: R89.
150. Black L, Gaynor J, Gahring D, et al. Effect of adipose-derived mesenchymal stem and regenerative cells on lameness in dogs with chronic osteoarthritis of the coxofemoral joints: A randomized, double-blinded, multicenter controlled trial. www.vetlearn.com. Accessed 24 Apr 2010.
151. U.S. Food and Drug Administration, Vaccines, Blood & Biologics: FDA Regulation of Human Cells, Tissues, and Cellular and Tissue-Based Products (HCT/Ps) Product List. Available at <http://www.fda.gov/BiologicsBloodVaccines/TissueTissueProducts/RegulationofTissues/ucm150485.htm>. Accessed 24 Apr 2010.
152. Title 21, Food and Drugs, Code of Federal Regulations, Subchapter L - Regulations under certain other acts administered by the Food and Drug Administration, Subpart A - General Provisions, Sect 1271.15. Available at: www.accessdata.fda.gov/scripts/cdrh/cfdocs/cfCFR/CFRSearch.cfm?fr=1271.15&SearchTerm=1271%2E15. Accessed 24 Apr 2010.
153. U.S. Food and Drug Administration, Draft Guidance for Industry: Cell Selection Devices for Point of care Production of Minimally Manipulated Autologous Peripheral Blood Stem Cells (PBSCs). Available at www.fda.gov/BiologicsBloodVaccines/GuidanceComplianceRegulatoryInformation/Guidances/Tissue/ucm074018.htm. Accessed 24 Apr 2010.
154. Title 21, Food and Drugs, Code of Federal Regulations, Subchapter L - Regulations under certain other acts administered by the Food and Drug Administration, Section 1271.3 How does FDA define important terms in this part? subsection (f). Available at www.accessdata.fda.gov/scripts/cdrh/cfdocs/cfCFR/CFRSearch.cfm?fr=1271.3. Accessed 24 Apr 2010.
155. Ibid. ref. 153.
156. U.S. Food and Drug Administration, Vaccines, Blood & Biologics: FDA Regulation of Human Cells, Tissues, and Cellular and Tissue-Based Products (HCT/Ps) Product List, Section III Combination Products. Available at <http://www.fda.gov/BiologicsBloodVaccines/TissueTissueProducts/RegulationofTissues/ucm150485.htm>. Accessed 24 Apr 2010.
157. Kane D, Balint V, Sturrock, R, and Grassi W. Musculoskeletal ultrasound—a state of the art review in rheumatology. Part 1: Current controversies and issues in the development of musculoskeletal ultrasound in rheumatology. *Rheumatology*. 2004. 43(7): 823-828.
158. Pizzi DM (ed). Ultrasound demonstrations fuel debate on clinical role in pain medicine. *Pain Medicine News*. Jan 2010.
159. Ibid. ref. 157.
160. Ibid. ref. 157.
161. www.essr.com. Accessed 24 Apr 2010.
162. Ombregt L, Bisschop P, and ter Veer HJ. *A System of Orthopaedic Medicine*, 2nd Edition. Churchill Livingstone. 2003. p 59.
163. Deyo R. Magnetic resonance imaging of the lumbar spine—terrific test or tar baby? *New England Journal of Medicine*. 1994. 331: 115-116.
164. Boden SD et al. Abnormal magnetic resonance scans of the lumbar spine in asymptomatic subjects. *J Bone and Joint Surgery*. 1990. 72A: 503-408.
165. Matsumoto M et al. MRI of the cervical intervertebral discs in asymptomatic subjects. *Bone and Joint Surgery*. (Br). 1998. 80(1): 19-24
166. Ibid. ref. 86.
167. Ibid. ref. 25; p 3.